Vol. 113: 69–73, 2015
doi: 10.3354/dao02827

DISEASES OF AQUATIC ORGANISMS
Dis Aquat Org

Published February 10

NOTE

Bipolaris hawaiiensis as an emerging cause of cutaneous phaeohyphomycosis in an Antillean manatee *Trichechus manatus manatus*

José Júlio Costa Sidrim[1], Vitor Luz Carvalho[1,2], Débora Castelo Branco de Souza Collares Maia[1], Raimunda Sâmia Nogueira Brilhante[1,*], Ana Carolina Oliveira de Meirelles[2], Cristine Pereira Negrão Silva[2], Rossana de Aguiar Cordeiro[1], José Luciano Bezerra Moreira[1], Tereza de Jesus Pinheiro Gomes Bandeira[2], Marcos Fábio Gadelha Rocha[1,3]

[1]Specialized Medical Mycology Center (CEMM), Federal University of Ceará, Rua Coronel Nunes de Melo, 1315, Rodolfo Teófilo, Fortaleza, Ceará, 60430-270 Brazil

[2]Associação de Pesquisa e Preservação de Ecossistemas Aquáticos (AQUASIS), Rua José de Alencar, 150, Caucaia, Ceará, 61627-010 Brazil

[3]Postgraduate Program in Veterinary Sciences, School of Veterinary Medicine, State University of Ceará, Av. Dr. Silas Munguba, 1700, Itaperi, Fortaleza, Ceará, 60740-000 Brazil

ABSTRACT: Phaeohyphomycoses are emerging and opportunistic diseases caused by dematiaceous fungi that infect many animal species. This paper describes a case of cutaneous phaeohyphomycosis in an Antillean manatee *Trichechus manatus manatus* caused by *Bipolaris hawaiiensis*. Blackish skin lesions were observed in an Antillean manatee calf held captive in Brazil. Direct examination of skin scraping from the affected areas revealed the presence of dematious hyphae. Culture of skin fragments led to the isolation and subsequent identification of *B. hawaiiensis* as the etiologic agent. Treatment with itraconazole for 14 d was effective. Infections by *Bipolaris* spp. are rare in animals, and this is the first report of *B. hawaiiensis* in veterinary medicine.

KEY WORDS: Phaeohyphomycosis · *Bipolaris hawaiiensis* · *Trichechus manatus manatus* · Itraconazole

INTRODUCTION

Phaeohyphomycoses are diseases caused by dematiaceous filamentous fungi, which contain melanin in their cell walls (Revankar et al. 2002, Seyedmousavi et al. 2013). Several genera belonging to the orders *Pleosporales* (*Alternaria* sp., *Bipolaris* sp.), *Ochroconiales* (*Ochroconis* sp.), *Chaetothyriales* (*Cladophialophora* sp., *Exophiala* sp., *Phialophora* sp., *Fonsecaea* spp.) and *Capnodiales* (*Cladosporium* sp.) are etiological agents of these infections in animals and cause superficial mycoses to severe disseminated and even fatal infections, depending on the etiological agent involved, the host and its immune status (Giri et al. 2011, Seyedmousavi et al. 2013).

In veterinary medicine, phaeohyphomycoses are important emerging and opportunistic diseases, affecting nearly all classes of vertebrates and invertebrates such as molluscs, crustaceans and annelids. Despite having been diagnosed in aquatic animals, including several species of fish (Seyedmousavi et al. 2013), there are no documented cases of dematiaceous fungi producing an infection in marine mammals. Among the Sirenia, an order formed by manatees and dugongs, reports of fungal infections are rare (Reidarson et al. 2001, Bossart 2007). Dilbone (1965) described a case of dermatophytosis, and Forrester

*Corresponding author: brilhante@ufc.br

(1992) listed cases of dermatitis caused by *Cephalosporium* sp., *Mucor* sp., *Fusarium* sp. and *Blastomyces dermatitidis*, all in captive *Trichechus manatus*. Studies of infectious diseases in manatees are relatively recent and rudimentary, but knowledge of the health of these animals is of great importance for their conservation, since the 4 species that comprise the order are all endangered (Bonde et al. 2004, Bossart 2006, IUCN 2013). This is a unique report of cutaneous phaeohyphomycosis in an Antillean manatee caused by *Bipolaris hawaiiensis*, highlighting the clinical and epidemiological aspects of the infection.

Fig. 1. (a) Blackish skin lesions, with irregular contours, concentrated in the dorsal region of the head of the Antillean manatee calf. (b) Distribution of the lesions (black arrows) and natural molting of the skin in the folds of the caudal peduncle (white arrow)

MATERIALS AND METHODS

On August 13, 2013, an Antillean manatee calf *Trichechus manatus manatus* was rescued by the team of the Projeto Cetáceos da Costa Branca (PCCB/UERN) after stranding on Gado Bravo Beach (04° 52′ 37.7″ S, 37° 13′ 30.0″ W) in the municipality of Tibau, state of Rio Grande do Norte, northeastern Brazil. The animal, a female, estimated age 2 mo, was taken to the Marine Mammal Rehabilitation Center of the Associação de Pesquisa e Preservação de Ecossistemas Aquáticos (CRMM/AQUASIS) for rehabilitation.

The calf was kept in a saltwater pool with prechlorinated and filtered water, with no contact to other individuals of the species. After an initial thorough clinical examination, the animal was assessed weekly; the examination included complete blood work, biometrics and scrubbing with 2% chlorhexidine, to aid the removal of loose shed skin. In the second week, superficial multifocal dark-colored skin lesions with irregular contours, measuring about 0.5 cm, were observed coinciding with the onset of the natural molt. (Fig. 1)

Over the next 30 d, the lesions expanded and spread throughout the body, initially appearing grayish or reddish-brown, but after 7 to 10 d, they turned black and the largest diameter exceeded 3 cm. No abnormal clinical signs or hematologic/biologic abnormalities were observed. On October 15, deep scraping of skin lesions was performed with a sterile scalpel blade, for microbiological analysis.

The direct examination of the skin scraping was carried out with 10% potassium hydroxide. Skin fragments were placed on a drop of potassium hydroxide on a glass slide. Then, the skin fragments were covered with a cover slip and submitted to microscopic examination. Additionally, skin fragments were seeded into tubes containing Sabouraud agar (HiMedia), Sabouraud agar plus chloramphenicol (HiMedia) and Mycosel agar (Becton, Dickinson and Company).

The samples were incubated at room temperature for up to 5 d to observe the growth of fungal colonies. After fungal recovery, slide cultures were performed on a block (0.4 × 1 × 1 cm) of potato dextrose agar (HiMedia). The agar block was placed on glass slides, within a Petri dish, and pieces of the fungal colony were seeded on the sides of the agar block, which was then covered with a cover slip. Afterwards, 1.5 ml of sterile saline solution was poured into the Petri dish, and the slide culture was incubated at 28°C for 7 d. After this period, the cover slip was placed on a glass slide with a drop of lactophenol cotton blue and taken to the optic microscope for morphological analysis and subsequent identification, in accordance with De Hoog et al. (2000). The

collection of samples for microbiological diagnosis of marine mammals was authorized by the Chico Mendes Institute for Conservation of Biodiversity, through the license SISBIO No. 35950-1, and by the animal research ethics committee of Ceará State University, under number 12639479-2.

RESULTS

Direct examination of the skin scraping revealed the presence of dematious, septate and toluroid hyphae on skin fragments, but the fur was not affected (Fig. 2). The growth of colonies of a blackish color with a sandy texture and a black reverse was observed only in those tubes with Sabouraud and Sabouraud agar plus chloramphenicol. On slide cultures, brownish septate hyphae were observed, with erect, non-branched, septate and apically directed conidiophores, with cylindrical, smooth, thick-walled conidia, containing 3 to 7 septa, allowing species identification as *Bipolaris hawaiiensis* (De Hoog et al. 2000) (Fig. 3).

Based on identification of the etiologic agent, treatment with itraconazole at a dose of 2.5 mg kg^{-1} was introduced orally once a day for 14 d. Positive evolution of the clinical picture and a good response to treatment were observed. Despite intense skin shedding, since the animal was molting, no fungal lesions were observed in the underlying layers of the affected areas. Significant hematological changes were not detected during the course of the disease, with only mild lymphopenia at the time of diagnosis. The serum levels of alanine aminotransferase (ALT) and aspartate aminotransferase (AST), measured through the clinical chemistry analyzer BS-120 (Mindray) doubled after the end of treatment with itraconazole.

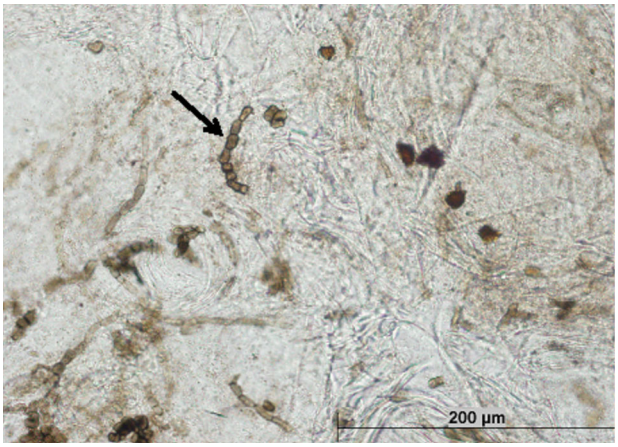

Fig. 2. Dematious, septated and toruloid hyphae (arrow) from direct examination of skin lesion of the Antillean manatee



Fig. 3. Microcultivation of *Bipolaris hawaiiensis*, showing erect, non-branched, septate and apically directed conidiophores (black arrows) with apical conidia (white arrows). In detail, cylindrical, smooth, thick-walled (W) conidia, containing 3 to 7 septa (S)

DISCUSSION

This is the first reported diagnosis of phaeohyphomycosis in aquatic mammals and represents a rare record of fungal disease in Sirenia, either in captivity or in the wild. Several species of dematiaceous fungi have been isolated from different animal taxa. However, superficial cutaneous phaeohyphomycosis caused by *Bipolaris* spp., such as reported here (since the fungal lesions were superficially restricted to the cutaneous tissues) are uncommon in veterinary medicine (Giri et al. 2011).

The genus *Bipolaris* sp. contains over 100 species, mostly described as phytopathogens or associated with soil and decaying food, and occurs mainly in tropical and subtropical regions (Bashir et al. 2009, Giri et al. 2011, da Cunha et al. 2012). Three of these species have significant medical importance as agents of superficial, subcutaneous and deep phaeohyphomycoses: *B. spicifera*, *B. australiensis* and *B. hawaiiensis* (McGinnis et al. 1986, Perfect et al. 2011).

Among the few reports of phaeohyphomycosis caused by *Bipolaris* sp. in animals, most have been assigned to *B. spicifera*, which affects horses, cows,

cats and dogs. However, most of the cases date from the 1970s and were erroneously attributed to the genera *Drechslera* sp. and *Helminthosporium* sp. (De Hoog et al. 2000). There is a record of a fatal case of systemic phaeohyphomycosis in a dog caused by *B. spicifera*, with involvement of the central nervous system and kidneys (Giri et al. 2011). No cases of infection with *B. hawaiiensis* were found in animals in the literature, so this is the first report in veterinary medicine of phaeohyphomycosis caused by this agent.

In human medicine, *B. spicifera* is the species most associated with infections (Bashir et al. 2009). However, *B. hawaiiensis* has been reported as an etiologic agent of pulmonary infections, meningoencephalitis, encephalitis, sinusitis, corneal ulcers, skin infections and endophthalmitis (Costa et al. 1991, Bashir et al. 2009, De Hoog et al. 2000). In Brazil there is only one published case report of phaeohyphomycosis caused by *B. hawaiiensis*, described in a farm worker in the southeastern region of the country (Costa et al. 1991).

Traumatic inoculation of the skin is the main transmission mode of cutaneous phaeohyphomycosis (Costa et al. 1991, Giri et al. 2011). In this case, it was not possible to determine the mode, but it is believed that the vegetation surrounding the water tanks may be the source of infection, as *Bipolaris* spp. are found as saprophytes in plants and soil (Bashir et al. 2009). Prophylactic use of chlorhexidine solution weekly for skin antisepsis may have favored the infection due to the temporary elimination of the local microbiota. The animal was scraped with sponges, which caused an intense debridation and helped remove the shed skin, possibly favoring the fungal inoculation in the skin. On the other hand, this procedure may have aided the antifungal treatment and the healing of the lesions, considering this was a strictly superficial phaeohyphomycosis.

Bledsoe et al. (2006) suggested that the defenses of the epidermis of Florida manatees do not work as effectively as in other groups of aquatic mammals, since these manatees are commonly colonized by algae and invertebrates. Thus, this immune impairment of the skin in its replacement phase, coupled with the animal's young age and the weekly skin scrubing, may have acted as important predisposing factors to this likely opportunistic infection.

Treatment with itraconazole at a dosage recommended by Bossart (2001) was effective and had no serious deleterious effects on the serum biochemical and hematological parameters of the Antillean manatee calf. The doubling of the ALT and AST serum was probably caused by the use of the antifungal, whereas azoles can increase the serum levels of liver enzymes in marine mammals 2 to 25 times but rarely cause liver disease in these animals (Reidarson et al. 2001). In addition to its extensive use in veterinary medicine, itraconazole has potent and consistent activity for the treatment of phaeohyphomycoses, including the systemic forms (Revankar et al. 2002)

CONCLUSIONS

The diagnosis of phaeohyphomycosis in marine mammals extends the spectrum of fungal diseases found in these animals and highlights the importance of fungi as emerging pathogens. The presence of the disease in a captive Antillean manatee, kept in adequate quality water and under good management conditions, demonstrates the susceptibility of these animals to infectious diseases in an artificial environment. Treatment with antifungals is poorly documented in sirenians, but the use of itraconazole in this case proved to be effective and safe.

Acknowledgments. This work was supported by the National Council for Scientific and Technological Development (CNPq; process number 474563/2013-8) and by the Coordination of Improvement of Higher Education Personnel (CAPES). We thank the institution Projeto Cetáceos da Costa Branca/Universidade do Estado do Rio Grande do Norte (PCCB/UERN) for the rescue of the Antillean manatee calf. The rehabilitation of Antillean manatees at CRMM/AQUASIS is performed by Projeto Manati, sponsored by Petrobras.

LITERATURE CITED

Bashir G, Hussain W, Rizvi A (2009) *Bipolaris hawaiiensis* keratomycosis and endophthalmitis. Mycopathologia 167: 51–53

Bledsoe EL, Harr KE, Cichra MF, Bonde RK, Lowe M (2006) A comparison of biofouling communities associated with free-ranging and captive Florida manatees (*Trichechus manatus latirostris*). Mar Mamm Sci 22:997–1003

Bonde RK, Aguirre AA, Powell J (2004) Manatees as sentinels of marine ecosystem health: Are they the 2000-pound canaries? EcoHealth 1:255–262

Bossart GD (2001) Manatees. In: Dierauf LA, Gulland FMD (eds) Handbook of marine mammal medicine. CRC Press, Boca Raton, FL, p 939–958

Bossart GD (2006) Marine mammals as sentinel species for oceans and human health. Oceanography (Wash DC) 19: 134–137

Bossart G (2007) Emerging diseases in marine mammals: from dolphins to manatees. Microbe 2:544–549

Costa AR, Porto E, Tabuti AH, Lacaz CZ, Sakai-Valente NY, Maranhão WM, Rodrigues MC (1991) Subcutaneous phaeohyphomycosis caused by *Bipolaris hawaiiensis*: case report. Rev Inst Med Trop Sao Paulo 33:74–79

da Cunha KC, Sutton DA, Fothergill AW, Cano J and others (2012) Diversity of *Bipolaris* species in clinical samples in the United States and their antifungal susceptibility profiles. J Clin Microbiol 50:4061–4066

De Hoog GS, Guarro J, Gené J, Figueras MJ (2000) Atlas of clinical fungi, 2nd edn. American Society for Microbiology, Washington, DC

Dilbone RP (1965) Mycosis in a manatee. J Am Vet Med Assoc 147:1095–1097

Forrester DJ (1992) Parasites and diseases of wild mammals in Florida. University Press of Florida, Gainesville, FL

Giri DK, Sims WP, Sura R, Cooper JJ, Gavrilov BK, Mansell J (2011) Cerebral and renal phaeohyphomycosis in a dog infected with *Bipolaris* species. Vet Pathol 48:754–757

IUCN (2013) IUCN Red List of Threatened Species. Version 2013.2. www.iucnredlist.org (accessed 23 Jan 2014).

McGinnis MR, Rinaldi MG, Winn RE (1986) Emerging agents of phaeohyphomycosis: pathogenic species of *Bipolaris* and *Exserrohilum*. J Clin Microbiol 24:250–259

Perfect JR, Alexander BD, Schell WA (2011) Phaeohyphomycoses (brown-black moulds). In: Kauffman CA, Pappas PG, Sobel JD, Dismukes WE (eds) Essentials of clinical mycology. Springer Science + Business Media, New York, NY, p 305–317

Reidarson TH, McBain JF, Dalton LM, Rinaldi MG (2001) Mycotic diseases. In: Dierauf LA, Gulland FMD (eds) Handbook of marine mammal medicine. CRC Press, Boca Raton, FL, p 337–355

Revankar SG, Patterson JE, Sutton DA, Pullen R, Rinaldi MG (2002) Disseminated phaeohyphomycosis: review of an emerging mycosis. Clin Infect Dis 34:467–476

Seyedmousavi S, Guillot J, De Hoog GS (2013) Phaeohyphomycoses, emerging opportunistic diseases in animals. Clin Microbiol Rev 26:19–35

Editorial responsibility: Thomas Braunbeck, Heidelberg, Germany

Submitted: May 27, 2014; Accepted: November 13, 2014
Proofs received from author(s): January 5, 2015