Vol. 125: 115–124, 2017
https://doi.org/10.3354/dao03141

DISEASES OF AQUATIC ORGANISMS
Dis Aquat Org

Published July 24

# Oral neoplasms in pickhandle barracuda *Sphyraena jello* from India

**V. Singaravel[1], A. Gopalakrishnan[1,*], K. Raja[1,2], R. Vijayakumar[1], S. Asrafuzzaman[3]**

[1]Centre of Advanced Study in Maine Biology, Faculty of Marine Sciences, Annamalai University, Parangipettai 608 502, Tamil Nadu, India

[2]PG & Research Department of Zoology, Government Arts College, C. Mutlur-608 102, Tamil Nadu, India

[3]Department of Zoology, Utkal University, Vani Vihar, Bhubansewar, Odisha 751 004, India

ABSTRACT: We report the spontaneous occurrence of oral neoplasms in pickhandle barracuda *Sphyraena jello* Cuvier, 1829 from Parangipettai, on the southeast coast of India. A total of 11736 fish were examined, of which 43 were affected with oral tumours, with an overall prevalence of 0.37%. Gross and clinical symptoms included reddish to grayish-white distended tumourous growths on the gingiva, intra-oral bones and tongue. The tumours exhibited delayed eruption and intra- or extra-oral swelling, varied in consistency from extremely firm to fleshy and released mucinous material. The majority of tumours consisted of numerous clumped toothlets, but some included hardened tissues. Local area invasion/transmission was observed in most cases; however, necropsy examination revealed no gross evidence of distant metastasis into visceral organs. Radiographic examination of compound odontomas revealed distinct unilocular radio-opaque mini-toothlets surrounded by defined radiolucency, whereas complex odontomas exhibited unilocular and indistinct radio-opaque masses within a much more extensive radiolucent zone. Histopathologically, the intra-oral tumour lesions were characterized by numerous imperfect (germ) toothlets consisting of a disorganized combination of dental tissues: pulp tissues with manifested and predominantly mixed hard dental tissues of immature dentine and enamel, numerous small to large and round to polyhedral ossicles embedded in hypocellular fibrous stromal tissues and sparsely spaced bland spindloid cells with cleft-like spaces of loose mucoid stroma. Histochemically, the neoplastic lesions stained positive for periodic acid-Schiff and Masson's trichrome. Based on the clinical and histological findings, the tumours were diagnosed as compound odontomas, complex odontomas, odontogenic myxomas, lingual myxomas and psammomatoid ossifying fibromas.

KEY WORDS: *Sphyraena jello* · Neoplasms · Odontoma · Myxoma · Psammomatoid ossifying fibroma



## INTRODUCTION

Neoplasms are common in fish, and are classified similarly to those in higher vertebrates (Schlumberger & Lucke 1948, Groff 2004). Tumours in fish have been reported in almost all organs and tissues (Wellings 1969, Groff 2004); however, reports related to oral tumours are rare. In fish, oral tumours (i.e. odontomas, ameloblastomas, papillomas and fibromas) have been reported in *Melanogrammus aeglefinus* (Thomas 1926), *Oncorhynchus tshawytscha* (Schlumberger & Katz 1956, Stolk 1957, Stockley 1975, Grim et al. 2009), *Sparus aurata* (Harshbarger 1974, Easa & Faisal 1987), *Tautogolabrus adsphersus* (Harshbarger 1974), *Cyprinodon variegatus variegatus* (Martineau et al. 1990), *Alcichthys elongatus* (Honma et al. 2003), *Carcharias taurus*, *Prionace glauca* (Borucinska et al. 2004), *Sphyraena barracuda* (Gopalakrishnan et al. 2011), *Sander vitreus* (Coffee et al. 2013), *Sphyraena jello* (Vijayakumar et al. 2014), *Pterophyllum scalare* (Videira et al. 2015) and *Carcharodon carcharias* (Huveneers et al. 2016). However, odontomas, myxomas

*Corresponding author: aquagopal@gmail.com

and psammomatoid ossifying fibromas are rare tumours in fish. To our knowledge, this is the first report of spontaneous occurrence of compound odontomas, complex odontomas, odontogenic myxomas, lingual myxomas and psammomatoid ossifying fibromas in pickhandle barracuda *Sphyraena jello* Cuvier, 1829 (Sphyraenidae).

## MATERIALS AND METHODS

### Sample collection

The pickhandle barracuda is widely distributed along the eastern and western coast of India, and is found in both marine and estuarine environments (De Bruin et al. 1995). Barracudas affected by tumours were sampled over a period of 2 yr (January 2014 to December 2015). Samples were collected from fishing boats, auction yards and merchants at the Parangipettai fish landing centre, Tamilnadu, southeast coast of India. Fish were identified based on a FAO fish identification guide (De Bruin et al. 1995) and tumor-affected fish were brought to the laboratory for further investigation. The colour, nature, size and site of origin of tumours were observed.

### Radiography

Both normal and tumour-affected fish were decapitated, and the heads were thoroughly washed under running tap water and rinsed with distilled water. The cleaned heads were laterally radiographed at 100 mA, 45 kV.

### Histopathology and histochemistry

Excised biopsies were fixed in 10% neutral phosphate-buffered formalin solution for 48 h. Ossified bone tumours were subsequently decalcified with 5% formic acid; biopsies were then dehydrated through a graded alcohol series, cleared in xylene and embedded in paraffin wax (56°C melting point). Serial sections of 4 µm thickness were cut with a rotary microtome (Yorco YSI-115) and then deparaffinized and rehydrated with xylene and a graded series of ethanol. Sections were then stained as follows. Harris haematoxylin and eosin (H & E) staining was performed according to the method of Coolidge & Howard (1979). Glycoprotein in the tumour tissues was stained with periodic acid-Schiff (PAS) base according to the method of Yamabayashi (1987). Collagen deposition in the tissue was analysed by staining with Masson's trichrome following the method of Chang & Kessler (2008), and Alcian blue staining was done according to Bancroft & Stevens (1982).

Table 1. Prevalence of oral tumours in *Sphyraena jello* landed at Parangipettai in Tamil Nadu, southeast India. Seasons are based on calendar months (post-monsoon: January–March; summer: April–June; pre-monsoon: July–September; monsoon: October–December)

| Season | No. of fish examined | No. of fish affected | Prevalence (%) |
|---|---|---|---|
| **2014** | | | |
| Post-monsoon | 1624 | 11 | 0.677 |
| Summer | 1816 | 3 | 0.165 |
| Pre-monsoon | 1723 | 5 | 0.290 |
| Monsoon | 1296 | 7 | 0.540 |
| Total 2014 | 6459 | 26 | 0.402 |
| **2015** | | | |
| Post-monsoon | 1409 | 8 | 0.567 |
| Summer | 1585 | 1 | 0.063 |
| Pre-monsoon | 1323 | 3 | 0.226 |
| Monsoon | 960 | 5 | 0.520 |
| Total 2015 | 5277 | 17 | 0.322 |
| Grand total | 11 736 | 43 | 0.366 |

## RESULTS

### Tumour prevalence

The prevalence of neoplasms in *Sphyraena jello* sampled at the Parangipettai landing centre is shown in Table 1. Of 11 736 fish examined, 43 were affected with extra- and/or intra-oral tumours, with an overall prevalence of 0.37%. A higher prevalence (0.40%) was observed in 2014 than in 2015 (0.32%). The highest seasonal prevalence (0.68%) was observed during the post-monsoon period in 2014, whereas the lowest prevalence was (0.06%) occurred during the summer of 2015. Among fish with oral tumours, 3 had lingual tumours, and we observed a higher occurrence in females (60.47%) than in males (39.53%). Tumour-affected barracuda length and weight varied from 48.3 to 87.6 cm (mean ± SD: 80.6 ± 4.11 cm) and 0.528 to 3.164 kg (mean ± SD 2.51 ± 0.42 kg).

### Gross pathology

Orocutaneous and odontogenic tumours in the barracuda were observed in and around the mouth region

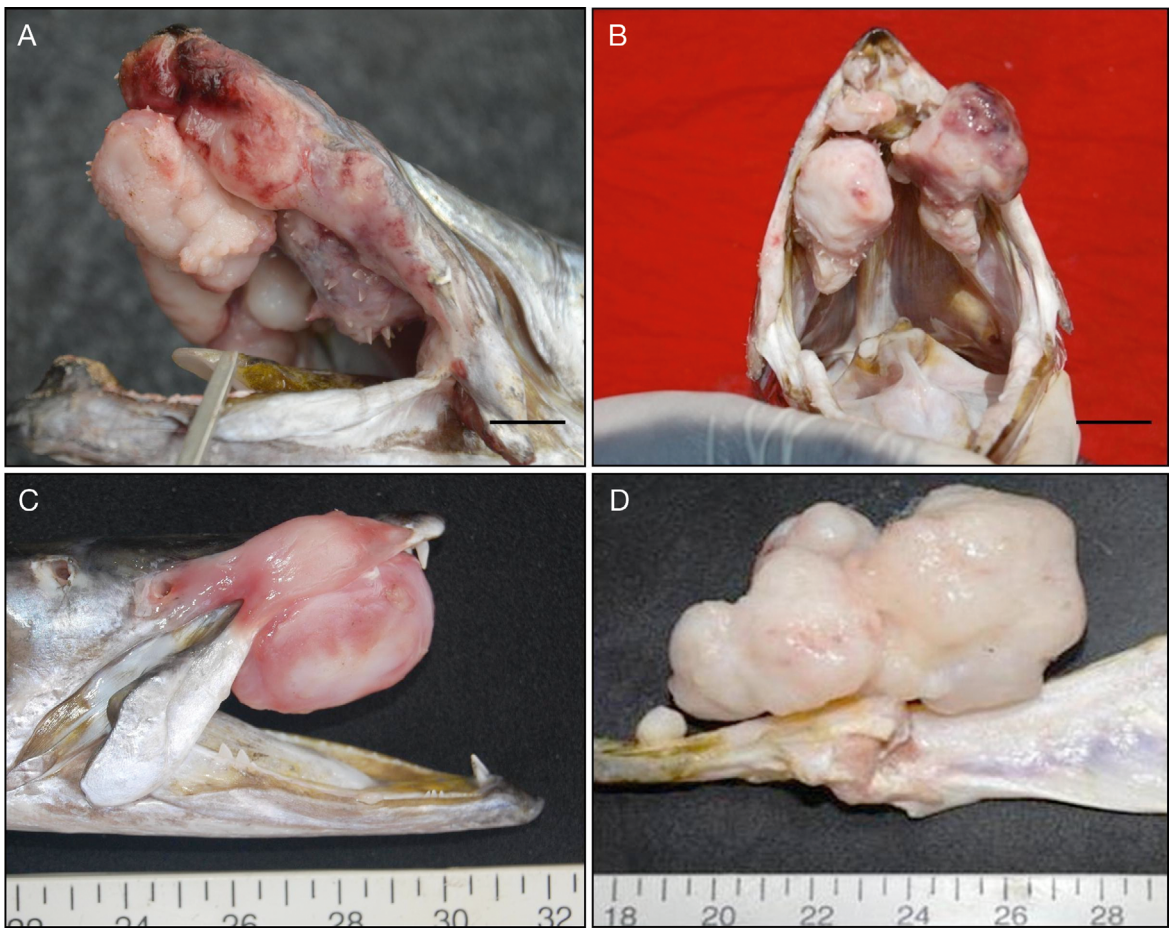


Fig. 1. *Sphyraena jello* with mouth tumours; reddish-white, bony to fleshy masses are located on, in and around the (A, B) gingiva, upper and lower jaw (scale bars = 2 cm), (C) mandible and (D) tongue. Rulers in panels C and D are in cm

(Fig. 1). Most of the neoplasms were reddish, although several were pinkish-gray and gray-white. Neoplasms exhibited delayed eruption and caused intra- or extra-oral swelling. They varied in their consistency from extremely firm to fleshy and released mucinous material. The majority of the jaw tumour lesions consisted of numerous clumped toothlets. Most lesions were located on the upper jaw, followed by the lower jaw and in some cases were observed both on the jaws and on the tongue. The lesions usually extended into the mouth, often deforming the jaw to such an extent that the fish was unable to close its mouth properly (Fig. 1). Generally, single tumours occupied the entire mouth, although multiple lesions (2–5 nodes) were observed in some cases (Fig. 1A,B). The neoplasms varied in size from 24 to 82 mm. Surgically excised lesions revealed that the tumours were located on the gingiva, tongue and both sides of the intra-oral region of the supramaxilla, premaxilla and dentary bones and their associated musculature. Necropsy examination revealed no gross evidence of distinct metastasis into other visceral organs. However, in most cases, local area invasion/transmission was observed (62.79%).

## Radiography

A radiograph of a normal barracuda head is presented in Fig. 2A. In odontoma-affected fish, the mass of extra bone tissue was usually merged with the upper and lower jaws. Compound odontomas exhibited distinct unilocular radio-opaque mini-toothlets surrounded by regions of defined radiolucency (Fig. 2B), whereas complex odontomas were characterized by unilocular and indistinct radio-opaque masses within a much more extensive radiolucent zone (Fig. 2C). Compound odontomas were mostly found in the supramaxilla, followed by the premaxilla and dentary bone, whereas complex odontomas were only observed in the supramaxilla.

## Histopathology and histochemistry

### Compound odontomas

Compound odontoma lesions were consistent with disorganized dental tissues that exhibit distinct cementum, dentin and enamel with odontoblastic cells in the pulp tissue (Fig. 3A). The lesions were composed of malformed dentin in the main portion of the hard tissue (Fig. 3B). PAS staining showed positive results for polysaccharides and glycoproteins (Fig. 3C). Masson's trichrome stain was positive for collagen, revealing short, coarse and wavy collagen fibres (Fig. 3D).

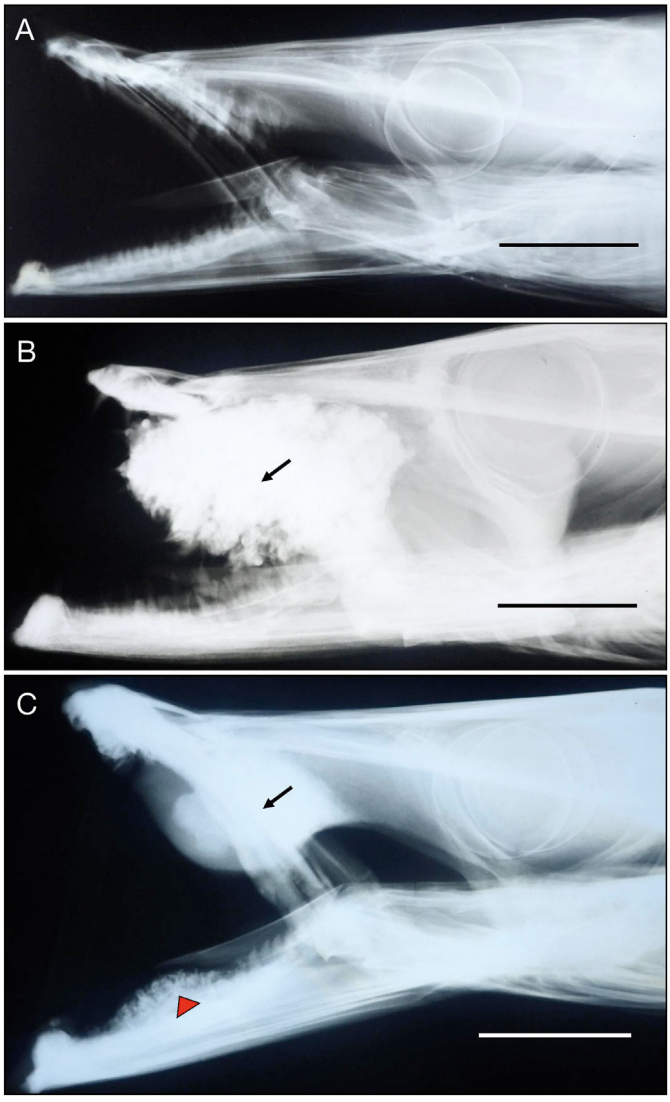


Fig. 2. Radiographs of *Sphyraena jello*: (A) normal, (B) radiodense compound odontoma in the supramaxilla (arrow), (C) complex odontoma in the supramaxilla (arrow) and compound odontoma in dentary bone (arrowhead). Scale bars = 5 cm

### Complex odontomas

Complex odontoma lesions consisted of less consolidated pulp tissue mixed with hard dental tissues (Fig. 4A). The hard tissue was largely consistent with disorganized dentin and odontogenic pulp tissues. Degenerative odontogenic dental tissues were scattered throughout loose connective tissue (Fig. 4B). PAS staining yielded positive results for polysaccharides and glycoproteins (Fig. 4C). Masson's trichrome stain was positive for collagen, with lesions exhibiting short, coarse and wavy collagen fibres, and toothlets consisting of abundant collagen (Fig. 4D).

### Psammomatoid ossifying fibromas

Mandibular lesions consisted of numerous small to large and round to polyhedral ossicles embedded in hypocellular fibrous stromal tissues. Myxomatous stromas were loosely packed in the centre and densely in the periphery, and fibroblastic cells consisted of low to moderate numbers of collagen fibrils (Fig. 5A). Concentric, lamellated, ossicle-like psammoma bodies were present. The stroma consisted of pleomorphic spindle cells with indistinct cytoplasm and basophilic nuclei. Mitotic figures were rarely observed (Fig. 5B). Masson's trichrome stain was positive for collagen and revealed that the lesions contained variable amounts of collagenous to myxomatous stroma. Psammoma bodies contained large amounts of collagen (Fig. 5C). PAS staining showed positive results for glycoprotein and polysaccharides, and the lesions exhibited slight to moderate stains with myxoid and psammoma bodies, respectively (Fig. 5D).

### Odontogenic myxomas

The fibrous stromal tissues extended into the bony trabecular tissues of the intra-oral bone musculature. The stromal tissues contained tightly packed spindled fibroblasts and were perforated by cleft-like spaces of loose mucoid stroma. The neoplastic cells contained medium-sized to tiny, oval nuclei (Fig. 6A). PAS staining yielded positive results for polysaccharides and glycoproteins and indicated that the lesions contained moderate levels of glycones (Fig. 6B). Masson's trichrome stain was positive for collagen and revealed that the myxoid matrix con-

tains short and wavy collagen fibres (Fig. 6C). Alcian blue staining was positive for acid mucopolysaccharides and sialomucins and showed that the myxoid matrix contained abundant acid mucopolysaccharides (Fig. 6D).

### Lingual myxomas

The hypocellular fibrous stromal tissues extended into the tongue musculature. The neoplastic lesions consisted of sparsely spaced bland fibroblasts and

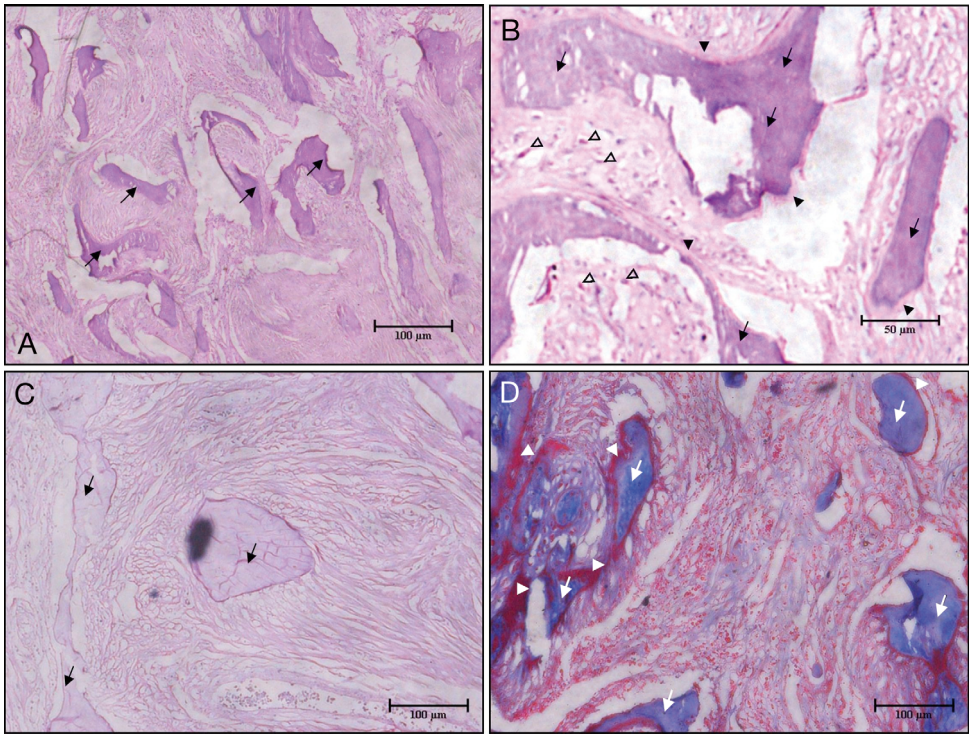


Fig. 3. Compound odontoma in *Sphyraena jello*. (A) Disorganized combination of dental matrix (arrows) scattered in stromal tissue (H&E). (B) Degenerative odontogenic dentin (arrows), enamel (black arrowheads) and odontoblastic cells (open arrowheads) in pulp tissue (H&E). (C) Periodic acid-Schiff moderately stains the dental matrix (arrows). (D) A lesion stained with Masson's trichrome shows dentin (arrows) surrounded by enamel (arrowheads)

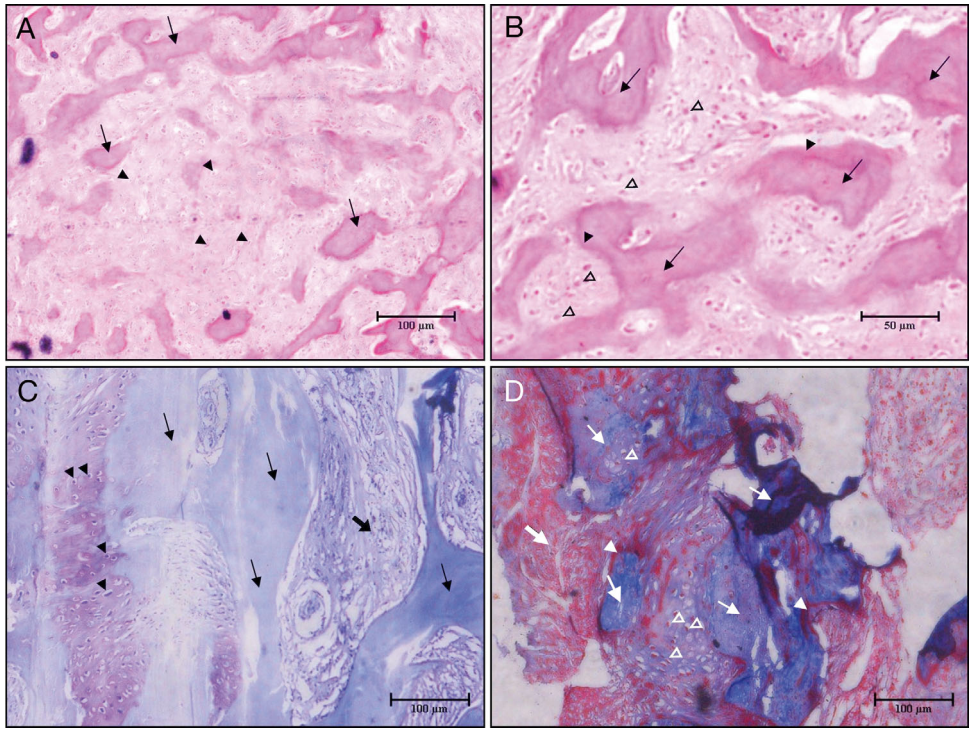


Fig. 4. Complex odontoma in *Sphyraena jello*. (A) Degenerative dental matrix shows disorganized dentin (arrows) and odontogenic pulp tissues (arrowheads) (H&E). (B) Dentin (arrows), enamel (black arrowheads) and odontoblastic cells (open arrowheads) in pulp tissue (H&E). (C) Periodic acid-Schiff moderately stains dentin and enamel (thin arrows), odontoblasts (arrowheads) and pulp tissues (thick arrow). (D) Masson's trichrome moderately stains the dental matrix, dentin (thin arrows), enamel (black arrowheads), odontoblast (open arrowheads) and pulp tissues (thick arrow)

were perforated by cleft-like spaces of loose mucoid stroma. The neoplastic cells had medium-sized to tiny oval nuclei (Fig. 7A). Masson's trichrome stain was positive for collagen, and the lesion exhibited long, coarse and wavy collagen fibres (Fig. 7B). PAS staining yielded positive results for polysaccharides and glycoproteins (Fig. 7C). Alcian blue staining was positive for acid mucopolysaccharides and sialomucins, revealing that the myxoid stromas contained abundant acid mucopolysaccharides (Fig. 7D).

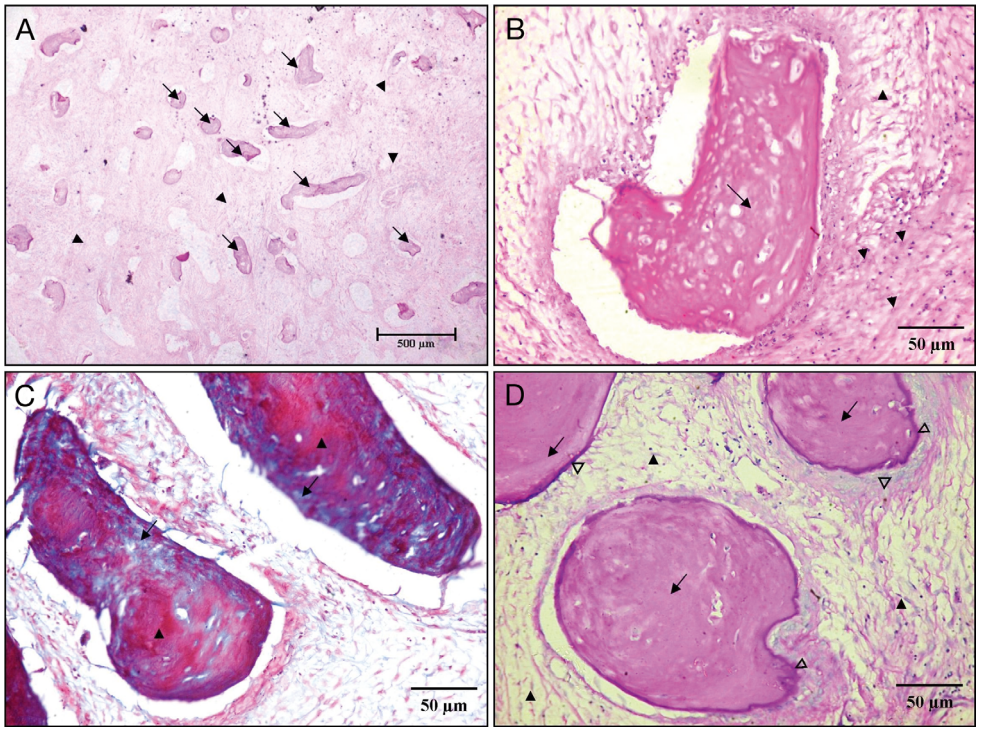


Fig. 5. Psammomatoid ossifying fibroma in *Sphyraena jello*. (A, B) Numerous round to polyhedral ossicles (arrows) embedded in fibrous stromal tissues (arrowheads) (H & E). (C) A Masson's trichrome-stained lesion shows moderate to abundant collagen content in ossicles (arrows) with protoplast (arrowheads) and myxoid stromas embedded in loose collagen fibres. (D) Periodic acid-Schiff staining of a lesion reveals moderate amounts of glycoprotein and polysaccharides in central ossicles (arrows) and abundant amounts in peripheral ossicles (open arrowheads); stromal tissues show moderate staining (black arrowheads)

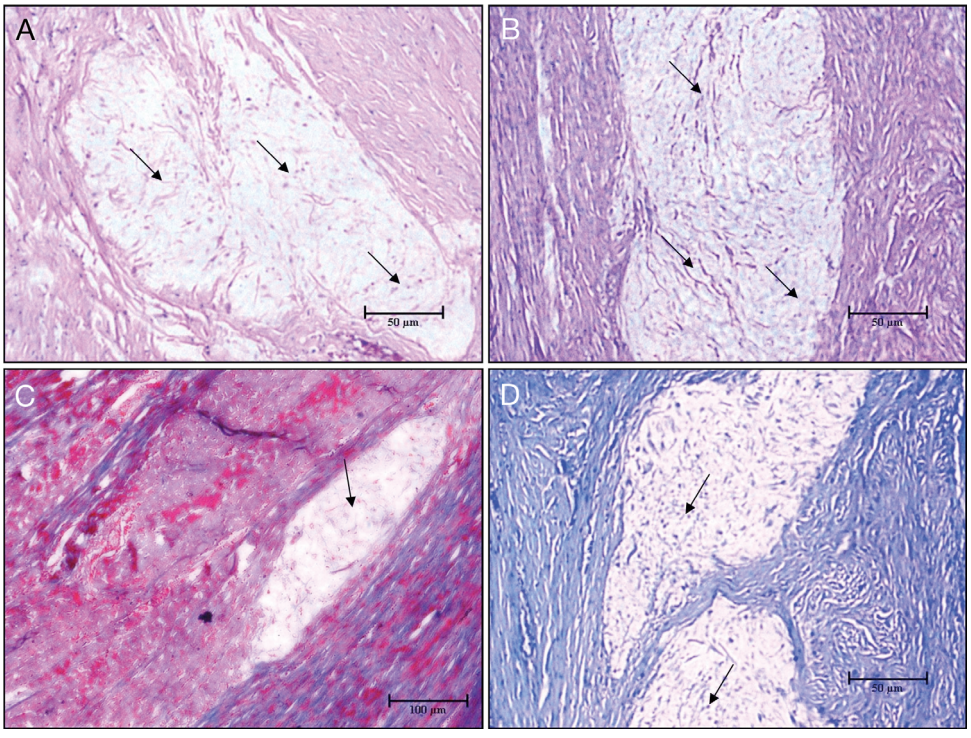


Fig. 6. Odontogenic myxoma in *Sphyraena jello*. (A) Bland spindloid cells within a myxomatous matrix (arrows) (H & E). (B) A periodic acid-Schiff-stained lesion shows moderate amounts of glycoprotein and polysaccharides (arrows). (C) Masson's trichrome staining of a lesion reveals long, coarse and wavy collagen fibres and a mucin cleft (arrow). (D) Alcian blue staining highlights acid mucopolysaccharides (arrows)

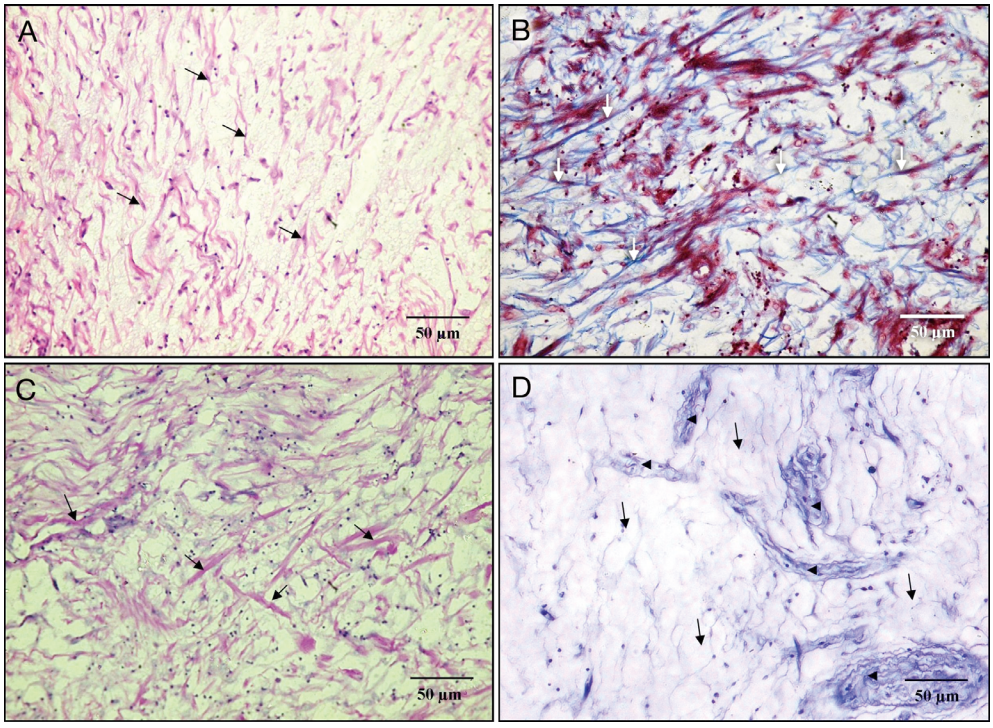


Fig. 7. Lingual myxoma in *Sphyraena jello*. (A) Myxomatous spindloid cells (arrows) (H & E). (B) Masson's trichrome-stained lesion, showing short to long and wavy collagen fibres (arrows). (C) Periodic acid-Schiff staining reveals moderate amounts of glycoprotein and polysaccharides (arrows). (D) Alcian blue staining highlights acid mucopolysaccharides (arrows) and mucinous clefts (arrowheads)

Summarizing the histological findings of the barracuda tumours, we found 5 different histomorphic neoplastic cell types. Among the tumours, compound odontomas were predominant (53.94 %) followed by complex odontomas (13.95 %), odontogenic myxomas (11.63 %), lingual myxomas (6.98 %) and psammomatoid ossifying fibromas (2.33 %). Mixed conditions were also found, such as compound with complex odontoma (4.65 %) and compound odontoma with odontogenic myxoma (6.98 %) (Table 2).

Table 2. Frequency of neoplasms in *Sphyraena jello* collected from the Parangipettai landing centre, south-east coast of India in 2014 and 2015

| Tumour type | No. of fish | Frequency (%) |
|---|---|---|
| Compound odontoma | 26 | 53.49 |
| Complex odontoma | 8 | 13.95 |
| Odontogenic myxoma | 5 | 11.63 |
| Lingual myxoma | 3 | 6.98 |
| Psammomatoid ossifying fibroma | 1 | 2.32 |
| **Mixed condition** | | |
| Compound with complex odontoma | 2 | 4.65 |
| Compound odontoma with odontogenic myxoma | 3 | 6.98 |

## DISCUSSION

Studies on oral tumours in fish are very scarce (Schlumberger & Lucke 1948, Gopalakrishnan et al. 2011, Vijayakumar et al. 2014), although some spontaneous oral tumours have been reported (Honma et al. 2003, Grim et al. 2009, Coffee et al. 2013, Videira et al. 2015). Gopalakrishnan et al. (2011) and Vijayakumar et al. (2014) reported intra-oral sarcomas and compound odontomas in *Sphyraena barracuda* and *S. jello* in India. In our investigation of *S. jello*, the prevalence of compound odontomas was higher than that of other tumours. To our knowledge, this is the first report of complex odontomas, odontogenic myxomas, lingual myxomas and psammomatoid ossifying fibromas in *S. jello*. Gross pathological examinations of the distended exophytic neoplastic growths suggested that they were benign in character; in contrast, the ulceration, hyperemic and invasive reaction suggested a malignant character. Our clinical observations revealed that single or multiple intra-oral neoplasms in *S. jello* occurred mostly on the upper jaw, followed by the lower jaw and tongue. Neoplasms have previously been reported in *S. barracuda* and *S. jello* (Gopalakrishnan et al. 2011, Vijayakumar et al. 2014).

We found no great variation between study years in the prevalence of tumours affecting barracuda. However, seasonal tumour prevalence fluctuated strongly. Vijayakumar et al. (2014) reported a higher

prevalence of odontomas during the monsoon season, whereas we found a higher tumour prevalence in the post-monsoon season. Gopalakrishnan et al. (2011) reported a tumour prevalence of 0.32 and 0.67% in *S. longiceps* and *S. barracuda,* respectively, which is similar to our results. However, for *S. jello*, Vijayakumar et al. (2014) reported a prevalence of 12.1%, which was much higher than the overall prevalence of 0.37% that we found among *S. jello*.

Sex can be an important factor in tumour prevalence in fish, with females at higher risk than males (Baumann et al. 1990, Pinkney et al. 2001, 2004). In the present study, we observed a higher incidence among females than among males. Previous studies have also reported higher tumour prevalence in females than in males (Martineau et al. 1990, Keller et al. 2011, Pinkney et al. 2014), although some studies reported a higher incidence in male than in female fish (Bowser et al. 1988, Okihiro 1988, Kortet et al. 2003, Korkea-aho et al. 2006, 2009).

Several field studies have indicated that neoplasms are more commonly observed in larger fish (Smith et al. 1989, Lee & Whitfield 1992, Poulet et al. 1994, Mikaelian et al. 2000, Kortet et al. 2002) and older fish (Smith et al. 1989, Mellergaard & Nielsen 1995, 1997). We also found that the larger and older *S. jello* were frequently affected with tumours. Age-related factors are postulated for neoplasia in some species of fish; for example, spontaneous epidermal neoplasms are more common in goldfish *Carassius auratus* at ≥5 yr of age (Etoh et al. 1983).

Odontomas are classified based on their radiographic appearance. In radiographic differential diagnoses, compound odontomas and complex odontomas appear as clusters of small toothlets and radiodense masses of hard tissues, respectively (Bordini et al. 2008, Serra-Serra et al. 2009). In our study, radiographic examination revealed both compound and complex odontomas in *S. jello*; the tumours consisted of tissues native to teeth (enamel, dentin, cementum and pulp tissue) as well as radiodense hard dental tissues.

Odontomas are considered relatively rare dental neoplasms in both higher and lower vertebrates, including fishes. In human and veterinary studies, the histological classification of odontomas consists of 2 main histotypes, viz. compound and complex odontomas. The histologically diagnostic features of the odontogenic neoplasms are dental pulp-like mesenchyme, dentin, cementum or an enamel matrix. The compound odontoma recapitulates the organization of a normal tooth, while the complex odontoma appears as a disorganized mass of hard odontogenic tissue (Shafer et al. 1983, Head et al. 2008). The barracudas investigated in our study were diagnosed as having compound odontomas, since many imperfect tooth-like structures consisting of odontoblast, predentin and dentin were scattered throughout the neoplastic tissue. The tooth-like structures (tooth germ) in these specimens lacked a true enamel structure (hypermineralized tooth cap), as has also been described in elkhorn sculpin *Alcichthys elongatus* (Honma et al. 2003), walleye *Sander vitreus* (Coffee et al. 2013) and pickhandle barracuda *S. jello* (Vijayakumar et al. 2014). The complex odontoma lesions observed in this study were similar to those described in humans by Lee & Park (2008) and were characterized by disorganized enamel, dentin, cementum and pulp tissue. To our knowledge, complex odontomas have not previously been reported in fish; thus this is the first report of complex odontomas in a fish spcies, namely *S. jello*. Both compound and complex odontoma lesions are extremely firm and large and occupy the entire buccal cavity of the fish, thereby affecting feeding activity.

Psammomatoid ossifying fibromas are rare in higher vertebrates and have not been reported in fish. The lesions that we observed in pickhandle barracuda resembled tumours in humans reported by Malathi et al. (2011), who described osteoid fibroma with atypical ossification. In our study, psammomatoid ossifying fibromas originated from the mandibular skeleton. We found no evidence of invasion and metastasis in the distal organs, and low mitotic activity also suggested the benign nature of the fibromas.

Myxomas are a rare tumour type in fishes. Cutaneous myxomas have been reported in *Seriola lalandi* (Keller et al. 2011), *Anguilla anguilla* (Gjurcevic et al. 2014), *Arius jella* (Singaravel et al. 2016) and *Carassius auratus* (Shohrpoor et al. 2016). We observed myxomatous lesions in pickhandle barracuda that were similar to those described by Keller et al. (2011), who described bland spindle-shaped cells embedded in an abundant myxoid or mucoid extracellular matrix. Pathological examination of the distended non-invasive and exophytic neoplastic growths suggested a benign nature of these tumours in barracuda. However, the overlying dermal ulceration, peripheral vascularization and inflammatory mast cells indicated pre-malignant characteristics. The fleshyer odontogenic myxomatous lesions are slightly firmer than psammomatoid ossifying fibromas.

Based on the differential diagnoses of histological and histochemical findings, the tumours observed in the sampled pickhandle barracuda were diagnosed as odontomas (compound and complex), psammo-

matoid ossifying fibromas and myxomas (odontogenic and lingual). Long-term monitoring and diagnoses will likely reveal higher numbers of tumours in *S. jello*.

*Acknowledgements*. The authors would like to acknowledge the Ministry of Environment Forest and Climate Change (MoEF&CC), Government of India, New Delhi, for financial support for the project entitled 'Prevalence of tumours in food fishes of Tamil Nadu coast' (D.O. No.22-31/2010-CS-I). Author (Dr. K. Raja) acknowledges the Department of Science and Technology (DST) – Science and Engineering Research Board (SERB) Government of India, New Delhi, for financial assistance, in the form of National Post-Doctoral Fellowship (F.No. PDF/2016/000584). We thank the fishermen and women at sampling localities for their help while collecting the fish samples from the sampling sites.

## LITERATURE CITED

Bancroft J, Stevens A (1982) Theory and practice of histological techniques, 2nd edn. Churchill Livingstone, New York, NY, p 194–198

Baumann PC, Harshbarger JC, Hartman KJ (1990) Relationship between liver tumors and age in brown bullhead populations from two Lake Erie tributaries. Sci Total Environ 94:71–87

Bordini J Jr, Contar CM, Sarot JR, Fernandes A, Machado MA (2008) Multiple compound odontomas in the jaw: case report and analysis of the literature. J Oral Maxillofac Surg 66:2617–2620

Borucinska JD, Harshbarger JC, Reimschuessel R, Bogicevic T (2004) Gingival neoplasms in a captive sand tiger shark, *Carcharias taurus* (Rafinesque), and a wild caught blue shark, *Prionace glauca* (L.). J Fish Dis 27:185–191

Bowser PR, Wolfe MJ, Forney JL, Wooster GA (1988) Seasonal prevalence of skin tumors from walleye (*Stizostedion vitreum*) from Oneida Lake, New York. J Wildl Dis 24:292–298

Chang JYF, Kessler HP (2008) Masson's trichrome stain helps differentiate myofibroma from smooth muscle lesions in the head and neck region. J Formos Med Assoc 107: 767–773

Coffee LL, Bogdanovic LB, Cushing TL, Bowser PR (2013) Pharyngeal odontoma in an adult walleye (*Sander vitreus*). Vet Pathol 50:483–487

Coolidge BJ, Howard RM (1979) Animal histology procedures of the Pathology Technology Section, Laboratory of Pathology, National Cancer Institute, National Institutes of Health, Bethesda, MD

De Bruin GHP, Russell BC, Bogusch A (1995) The marine fishery resources of Sri Lanka. FAO species identification field guide for fishery purposes. FAO, Rome

Easa ME, Faisal M (1987) Odontogenic fibroma in gilthead sea bream, *Sparus aurata*. J Egypt Vet Med Assoc 47:47–53

Etoh H, Hyodo-Taguchi Y, Aoki K, Murata M, Matsudaira H (1983) Incidence of chromatoblastomas in aging goldfish (*Carassius auratus*). J Natl Cancer Inst 70:523–528

Gjurcevic E, Sfacteria A, Marino F (2014) Spontaneous multicentric myxoma of the dermal nerve sheaths in farmed European eels *Anguilla anguilla*. Dis Aquat Org 111:173–176

Gopalakrishnan A, Maran BAV, Puvanendran V, Rajkumar M, Balasubramanian T, Ferguson HW (2011) Neoplasia in the Indian oil sardine, *Sardinella longiceps* (Valenciennes), and the great barracuda, *Sphyraena barracuda* (Edwards), from the south-east coast of India. J Fish Dis 34:881–885

Grim KC, Wolfe MJ, Edwards M, Kaufman J, Onjukka S, Moran P, Wolf JC (2009) Epizootic ameloblastomas in Chinook salmon (*Oncorhynchus tshawytscha*) of the northwestern United States. Vet Pathol 46:622–635

Groff JM (2004) Neoplasia in fishes. Vet Clin North Am Exot Anim Pract 7:705–756

Harshbarger JC (1974) Activities report of the Registry of Tumours in Lower Animals, 1965–1973. Smithsonian Institution, Washington, DC

Head KW, Else RW, Dubielzig RR (2008) Tumours of the alimentary tract, 4th edn. In: Meuten DJ (ed) Tumours in domestic animals. Wiley-Blackwell, p 402–409

Honma Y, Hitomi J, Takeda M, Ushiki T (2003) Odontoma in an elkhorn sculpin *Alcichthys elongatus* caught in the Sea of Japan. Fish Pathol 38:53–58

Huveneers C, Klebe S, Fox A, Bruce B, Robbins R, Borucinska JD, Michael MZ (2016) First histological examination of a neoplastic lesion from a free-swimming white shark, *Carcharodon carcharias* L. J Fish Dis 39:1269–1273

Keller M, Han S, Snekvik K (2011) Severe anisakiasis and cutaneous myxoma in a California yellowtail, *Seriola lalandi* Valenciennes. J Fish Dis 34:635–639

Korkea-aho TL, Partanen JM, Kiviniemi V, Vainikka A, Taskinen J (2006) Association between environmental stress and epidermal papillomatosis of roach *Rutilus rutilus*. Dis Aquat Org 72:1–8

Korkea aho TL, Vainikka A, Kortet R, Taskinen J (2009) Factors affecting between lake variation in the occurrence of epidermal papillomatosis in roach, *Rutilus rutilus* (L.). J Fish Dis 32:263–270

Kortet R, Vainikka A, Taskinen J (2002) Epizootic cutaneous papillomatosis in roach *Rutilus rutilus*: sex and size dependence, seasonal occurrence and between-population differences. Dis Aquat Org 52:185–190

Kortet R, Vainikka A, Rantala MJ, Jokinen I, Taskinen J (2003) Sexual ornamentation, androgens and papillomatosis in male roach (*Rutilus rutilus*). Evol Ecol Res 5: 411–419

Lee CH, Park GJ (2008) Complex and compound odontomas are clinico-pathological entities. Basic Appl Pathol 1: 30–33

Lee S, Whitfield PJ (1992) Virus associated spawning papillomatosis in smelt, *Osmerus eperlanus* L., in the River Thames. J Fish Biol 40:503–510

Malathi N, Radhika T, Thamizhchelvan H, Ravindran C, Ramkumar S, Giri GVV, Gopal D (2011) Psammomatoid juvenile ossifying fibroma of the jaws. J Oral Maxillofac Pathol 15:326–329

Martineau D, Bowser PR, Wooster GA, Armstrong LD (1990) Experimental transmission of a dermal sarcoma in fingerling walleyes (*Stizostedion vitreum vitreum*). Vet Pathol 27:230–234

Mellergaard S, Nielsen E (1995) Impact of oxygen deficiency on the disease status of common dab *Limanda limanda*. Dis Aquat Org 22:101–114

Mellergaard S, Nielsen E (1997) Epidemiology of lymphocystis, epidermal papilloma and skin ulcers in common dab *Limanda limanda* along the west coast of Denmark. Dis Aquat Org 30:151–163

Mikaelian I, Lafontaine YD, Gagnon P, Ménard C and others (2000) Prevalence of lip neoplasms of white sucker (*Catostomus commersoni*) in the St. Lawrence River basin. Can J Fish Aquat Sci 57(Suppl 1):174–181

Okihiro MS (1988) Chromatophoromas in two species of Hawaiian butterflyfish, *Chaetodon multicinctus* and *C. miliaris.* Vet Pathol 25:422–431

Pinkney AE, Harshbarger JC, May EB, Melancon MJ (2001) Tumor prevalence and biomarkers of exposure in brown bullheads (*Ameiurus nebulosus*) from the tidal Potomac River, USA, watershed. Environ Toxicol Chem 20: 1196–1205

Pinkney AE, Harshbarger JC, May EB, Reichert WL (2004) Tumor prevalence and biomarkers of exposure and response in brown bullhead (*Ameiurus nebulosus*) from the Anacostia River, Washington, DC and Tuckahoe River, Maryland, USA. Environ Toxicol Chem 23:638–647

Pinkney AE, Harshbarger JC, Rutter MA (2014) Temporal and spatial patterns in tumour prevalence in brown bullhead *Ameiurus nebulosus* (Lesueur) in the tidal Potomac River watershed (USA). J Fish Dis 37:863–876

Poulet FM, Wolfe MJ, Spitsbergen JM (1994) Naturally occurring orocutaneous papillomas and carcinomas of brown bullheads (*Ictalurus nebulosus*) in New York state. Vet Pathol 31:8–18

Schlumberger HG, Katz M (1956) Odontogenic tumors of salmon. Cancer Res 16:367–370

Schlumberger HG, Lucke B (1948) Tumors of fishes, amphibians, and reptiles. Cancer Res 8:657–753

Serra-Serra G, Berini-Aytés L, Gay-Escoda C (2009) Erupted odontomas: a report of three cases and review of the literature. Med Oral Patol Oral Cir Bucal 14:E299–E303

Shafer WG, Hine MK, Levy BM (1983) A text book of oral pathology, 4th edn. Saunders Co., Philadelphia, PA, p 304–313

Shohrpoor S, Sasani F, Rahmati-Holasoo H, Zargar A (2016) Concurrence of fibroma and myxoma in an oranda goldfish (*Carassius auratus*). Bull Eur Assoc Fish Pathol 36: 263–268

Singaravel V, Gopalakrishnan A, Vijayakumar R, Raja K (2016) The case report on cutaneous myxoma or invasive myxomatosis in blackfin sea catfish (*Arius jella* Day, 1877). Comp Clin Pathol 25:491–495

Smith IR, Ferguson HW, Hayes MA (1989) Histopathology and prevalence of epidermal papillomas epidemic in brown bullhead, *Ictalurus nebulosus* (Lesueur), and white sucker, *Catostomus commersoni* (Lacepede), populations from Ontario, Canada. J Fish Dis 12:373–388

Stockley C (1975) Odontogenic tumors of salmon. Prog Fish-Cult 37:62

Stolk A (1957) Tumours in fishes. XIX. Odontogenic tumour in the oviparous cyprinodont *Cyprinodon variegatus variegatus* Lacepede. Verh K Ned Akad Wet Ser C Biol Med Wet 60:658–665

Thomas L (1926) Odontoblastic carcinoma of the maxillary in a cod. Bull Assoc Fr Étud Cancer 15:464–470 (in French)

Videira M, Velasco M, Tortelly R, Sao Clemente SC, Matos P, Sanches O, Matos E (2015) Spontaneous multi-cystic peripheral ameloblastoma in the freshwater angelfish, from the Brazilian state of Para. Arq Bras Med Vet Zootec 67:1201–1204

Vijayakumar R, Gopalakrishnan A, Raja K, Sinduja K (2014) Occurrence of tumour (odontoma) in marine fish *Sphyraena jello* from the southeast coast of India. Dis Aquat Org 108:53–60

Wellings SR (1969) Neoplasia and primitive vertebrate phylogeny: echinoderms, prevertebrates, and fishes — a review. Natl Cancer Inst Monogr 31:59–128

Yamabayashi S (1987) Periodic acid-Schiff-Alcian blue: a method for the differential staining of glycoproteins. Histochem J 19:565–571

*Editorial responsibility: Thomas Lang, Cuxhaven, Germany*

*Submitted: July 15, 2016; Accepted: May 16, 2017*
*Proofs received from author(s): July 3, 2017*