

# Lobomycosis-like disease in common bottlenose dolphins *Tursiops truncatus* from Belize and Mexico: bridging the gap between the Americas

Eric A. Ramos<sup>1,2,3,\*</sup>, Delma N. Castelblanco-Martínez<sup>3,4</sup>, Jazmin Garcia<sup>5</sup>,  
Jorge Rojas Arias<sup>6</sup>, James R. Foley<sup>7</sup>, Katherina Audley<sup>8</sup>, Koen Van Waerebeek<sup>9</sup>,  
Marie-Françoise Van Bresse<sup>9</sup>

<sup>1</sup>The Graduate Center, City University of New York, New York 10016, USA

<sup>2</sup>Oceanic Society, 30 Sir Francis Drake Boulevard, PO Box 437, Ross, California 94957, USA

<sup>3</sup>Fundación Internacional para la Naturaleza y la Sostenibilidad (FINS), Chetumal, Mexico

<sup>4</sup>Consejo Nacional de Ciencia y Tecnología/Universidad de Quintana Roo, Mexico

<sup>5</sup>Halmos College of Natural Sciences and Oceanography, Nova Southeastern University, Fort Lauderdale, Florida 33004, USA

<sup>6</sup>El Colegio de la Frontera Sur (ECOSUR), Chetumal, Mexico

<sup>7</sup>Toledo Institute for Development and Environment (TIDE), Toledo, Belize

<sup>8</sup>Whales of Guerrero Research Project, Barra de Potosi, Guerrero, Mexico

<sup>9</sup>Cetacean Conservation Medicine Group (CMED), Peruvian Centre for Cetacean Research (CEPEC), Museo de Delfines, Pucallpa, Peru

**ABSTRACT:** Lobomycosis and lobomycosis-like diseases (LLD) (also: paracoccidioidomycosis) are chronic cutaneous infections that affect Delphinidae in tropical and subtropical regions worldwide. In the Americas, these diseases have been relatively well-described, but gaps still exist in our understanding of their distribution across the continent. Here we report on LLD affecting inshore bottlenose dolphins *Tursiops truncatus* from the Caribbean waters of Belize and from the eastern tropical Pacific Ocean off the southwestern coast of Mexico. Photo-identification and catalog data gathered between 1992 and 2017 for 371 and 41 individuals, respectively from Belize and Mexico, were examined for the presence of LLD. In Belize, 5 free-ranging and 1 stranded dolphin were found positive in at least 3 communities with the highest prevalence in the south. In Guerrero, Mexico, 4 inshore bottlenose dolphins sighted in 2014–2017 were affected by LLD. These data highlight the need for histological and molecular studies to confirm the etiological agent. Additionally, we document a single case of LLD in an adult Atlantic spotted dolphin *Stenella frontalis* in southern Belize, the first report in this species. The role of environmental and anthropogenic factors in the occurrence, severity, and epidemiology of LLD in South and Central America requires further investigation.

**KEY WORDS:** Lobomycosis-like disease · *Tursiops truncatus* · *Stenella frontalis* · Cutaneous diseases · Paracoccidioidomycosis · Odontocetes · Americas

Resale or republication not permitted without written consent of the publisher

## INTRODUCTION

Lobomycosis or Lobo's disease, first described by the Brazilian researcher Jorge O. Lobo (Lobo 1930), is a chronic fungal infection of the skin and subcuta-

neous tissues that affects several species of Delphinidae, but primarily bottlenose dolphins *Tursiops* spp. (de Vries and Laarman 1973, Caldwell et al. 1975, Simões-Lopes et al. 1993, Burdett Hart et al. 2011). This disease has also been referred to as

keloidal blastomycosis (Lobo 1931), and more recently as lacaziosis (Taborda et al. 1999) and paracoccidioidomycosis ceti (Vilela et al. 2016), among others, according to changing insights of its etiologic agent. We suggest that the term lobomycosis is a nomen conservandum because it appropriately honors the discoverer, provides historical immutability, and maintains continuity with existing literature. Lobomycosis is characterized by grey, white, and/or pink granulomatous lesions that may ulcerate and form large plaques (Taborda et al. 1999, Reif et al. 2006, Van Bresseem et al. 2007, 2015, Sacristán et al. 2016, Vilela et al. 2016). The causative agent in bottlenose dolphins and in a Pacific white-sided dolphin *Lagenorhynchus obliquidens* is a novel uncultivated strain of *Paracoccidioides brasiliensis*, a dimorphic fungus of the order Onygenales, family Ajellomycetaceae (Rotstein et al. 2009, Esperón et al. 2012, Ueda et al. 2013, Minakawa et al. 2016, Vilela et al. 2016). Impairment in adaptive immunity is likely a precursor to the disease in *T. truncatus* from Florida, USA (Reif et al. 2006). Lobomycosis-like disease (LLD), or paracoccidioidomycosis ceti-like disease (Vilela et al. 2016), is a condition whose clinical presentation evokes lobomycosis but lacks a decisive histological and molecular diagnosis (Van Bresseem et al. 2007, 2009, Kiszka et al. 2009). Immunohistochemical and histopathological analysis of recent LLD cases in *T. truncatus* stranded in Brazil positively identified the etiologic agent as a yeast strain of *P. brasiliensis* (Sacristán et al. 2016).

Lobomycosis and LLD have been reported worldwide in 6 species of Delphinidae, i.e. the common bottlenose dolphin *T. truncatus* (Caldwell et al. 1975, Reif et al. 2006, Murdoch et al. 2008, Van Bresseem et al. 2015), Indo-Pacific bottlenose dolphin *T. aduncus* (Kiszka et al. 2009, Tajima et al. 2015), Guiana dolphin *Sotalia guianensis* (de Vries & Laarman 1973, Van Bresseem et al. 2007), Pacific white-sided dolphin *Lagenorhynchus obliquidens* (Minakawa et al. 2016), Indian Ocean humpback dolphin *Sousa plumbea* (Lane et al. 2014), and Australian snubfin dolphin *Orcaella heinsohni* (Palmer & Peterson 2014). Dolphins may live with these progressive skin disorders for several years (Bossart 1984, Murdoch et al. 2008, Kiszka et al. 2009, Van Bresseem et al. 2009, 2015). However, individuals with advanced lobomycosis and LLD often die or disappear (Van Bresseem et al. 2009, 2015).

The occurrence of lobomycosis and LLD in *T. truncatus* has been well-documented across the Americas (Simões-Lopes et al. 1993, Reif et al. 2006, Burdett Hart et al. 2011, Van Bresseem et al. 2015). Along the Atlantic coast of South America, the southernmost

LLD record is in a *T. truncatus* stranded on Cassino Beach (32° 48' S, 52° 28' W) in southern Brazil (Van Bresseem et al. 2015), and the northernmost record is an adult male beached on Margarita Island (11° 01' 30" N, 64° 10' 30" W), Venezuela (Bermúdez et al. 2009). Along the Atlantic coast of North America, the northernmost records were in offshore *T. truncatus* from North Carolina (Rotstein et al. 2009), and the southernmost was an inshore dolphin free-ranging in the Upper Keys, Florida (Reif et al. 2006). Along the Pacific coast of the Americas, the northernmost cases of LLD were reported in a *T. truncatus* community inhabiting the waters of Golfo Dulce, Costa Rica (Bessesen et al. 2014), and the southernmost was in a small community of the same species resident in coastal waters of Posorja, Ecuador (Van Bresseem et al. 2015). Lobomycosis and LLD are unknown in Delphinidae from the Caribbean waters off Central America and in the offshore Eastern Tropical Pacific, leaving a wide gap in our knowledge of their geographical distribution. It remains unclear whether its distribution in the eastern Atlantic is continuous between North and South America.

During photo-identification (PI) studies, we observed skin lesions evoking LLD in *T. truncatus* and an Atlantic spotted dolphin *Stenella frontalis* from Belize's Caribbean coast and *T. truncatus* from the Pacific coast of southern Mexico. As this disorder has not been reported before in cetaceans from these countries, we examined PI images of *T. truncatus* taken at these locations from 1992 to 2017 for the presence of LLD. Here we report on our findings.

## MATERIALS AND METHODS

### Study areas and surveys

#### Belize

Belize has 386 km of coastline extending from its northern border with Mexico to Guatemala in the south, where shallow coastal lagoons, mangroves, estuaries, and cayes are bordered by the Belize Barrier Reef that extends along most of the country. Numerous watersheds, rivers, and canals flow into the marine waters of Belize, especially in the south of the country (Fig. 1). Images of 371 *T. truncatus* were obtained from 4 locations during small boat surveys (4–7 m long) (Table 1). Our dataset included only the inshore ecotype of *T. truncatus*, which is smaller, lighter in color, and inhabits shallower waters than the offshore ecotype in Belize (Ramos et al. 2016).

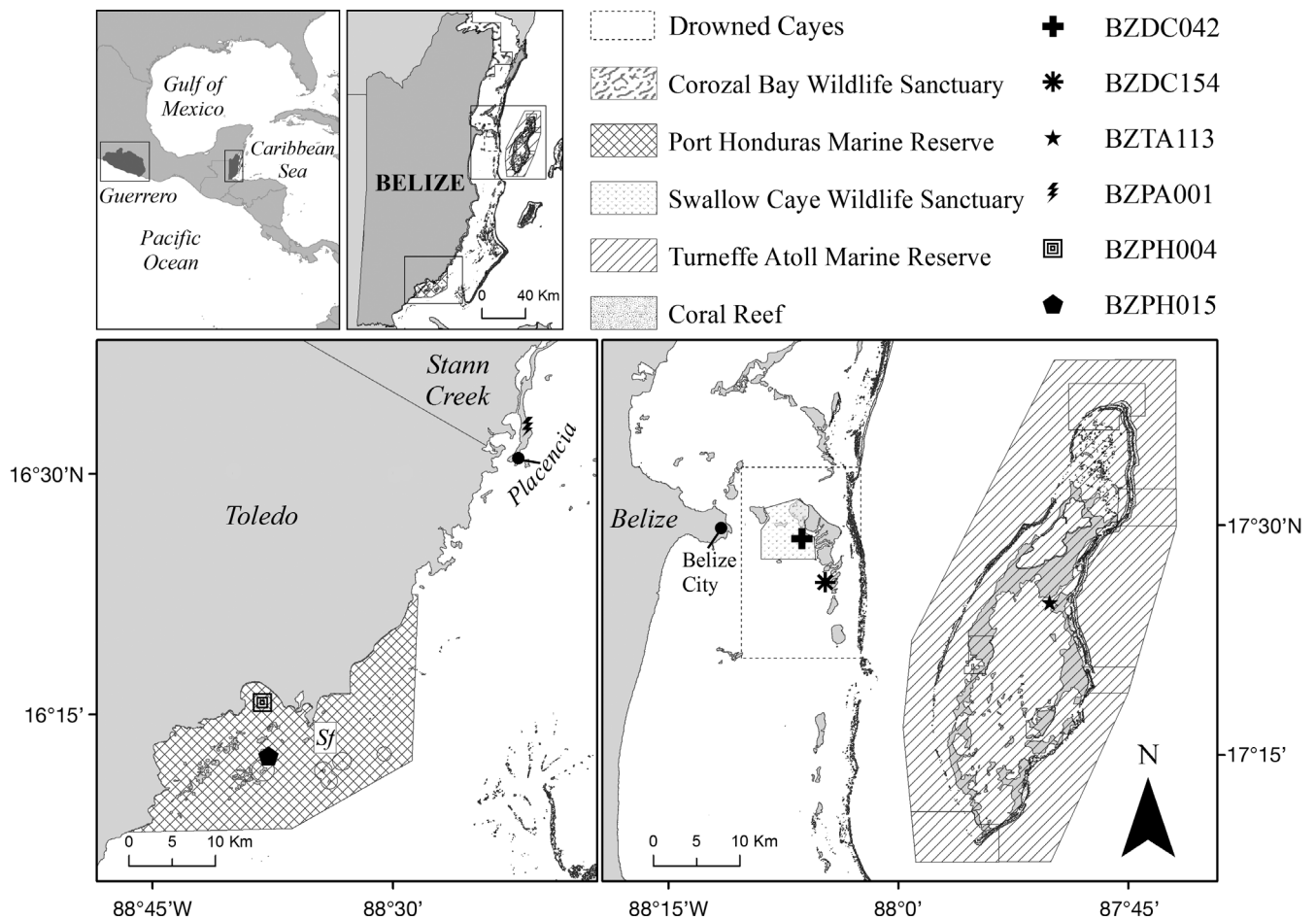


Fig. 1. Study areas in Belize and Guerrero, southern Mexico. Marks show the locations of first sightings of documented cases of lobomycosis-like disease (LLD) in bottlenose dolphins *Tursiops truncatus* from Belize. Sf marks the sighting of the LLD-afflicted adult Atlantic spotted dolphin *Stenella frontalis* in Port Honduras Marine Reserve

Sixteen *T. truncatus* were recently photo-identified (E. Ramos unpubl. data) in the shallow lagoon of Corozal Bay Wildlife Sanctuary (CBWS) (18° 23' N, 88° 11' W) in northern Belize, which is a protected area for the Antillean subspecies of the West Indian manatee *Trichechus manatus manatus*. The Drowned Cayes (17° 29' N, 88° 05' W), a chain of islands located 5 km east off Belize City, are home to a small *T. truncatus* community estimated at 122 animals, including residents (30%) and transients (Kerr et al. 2005). Turneffe Atoll Marine Reserve (17° 17' N, 87° 52' W) is a large, shallow-water oceanic atoll located 30 km east off mainland Belize that comprises a coastal ecosystem of mangrove cayes and a fringing coral reef with shallow lagoons dominated by seagrasses. Turneffe is home to a small population of inshore-ecotype *T. truncatus* including residents, transients, and partial residents. From mark-recapture studies and distance-sampling tech-

niques, population estimates range from 83 (Campbell et al. 2002) to 216 animals (Dick & Hines 2011). To date, 179 dolphins have been identified during 22 yr of long-term monitoring and PI efforts (Ramos et al. 2016). Port Honduras Marine Reserve (PHMR) (16° 13' N, 88° 41' W) is located in the coastal waters of the Toledo district of southern Belize and includes coral reef, seagrass, mangrove, and tidal wetland habitats. Baseline studies of dolphins in PHMR indicate that both Atlantic spotted dolphins *Stenella frontalis* and a small community of bottlenose dolphins occur in the reserve (Rojas Arias 2013), with 29 identified bottlenose dolphins and 24 *S. frontalis* in 2013. Images from an LLD-positive *T. truncatus* stranded at Placencia, a peninsula 32 km north of PMHR in southern Belize (16° 34' N, 88° 22' W), were also considered for the present study (Fig. 1); however, no other data exist for dolphins near Placencia.

Table 1. Site location and parameters for all regions in Belize and Mexico where bottlenose dolphins *Tursiops truncatus* were examined during the present study. Ny: total number of years analyzed; Nt: total number of photo identified dolphins examined; Npot: total number of dolphins potentially affected with lobomycosis-like disease (LLD); Npos: total number of dolphins positively confirmed with LLD; Prev: prevalence; SST: sea surface temperature; R: resident; NR: non-resident; Unk.: unknown; \* indicates stranded animal

Country	Location	Residency	Sampling period	Ny	Nt	N pot	N pos	Prev. (%)	SST (C°)	Salinity	Reference(s)
<b>Central America / Caribbean Sea</b>											
Belize	Corozal Bay Wildlife Sanctuary	Unk.	Mar 2017	1	16	0	0	0	25.8–32.2	0.8–35.9	This study
	Turneffe Atoll Marine Reserve	R & NR	1992–1996	5	81	0	0	0	27–31	34–42	Campbell et al. (2002)
			2001–2002	14	98	3	1	1			Campbell et al. (2002), this study
			2006–2016								
	Drowned Cayes & Swallow Caye Wildlife Sanctuary	R & NR	1997–1999	3	99	1	0	0	25–33	30–42	Kerr et al. (2005)
			2005–2017	13	47	4	2	4.3			This study
	Port Honduras Marine Reserve	Unk.	Jun–Aug 2013	1	29	4	2	7.1	24–31	0–38.2	Rojas Arias (2013)
	Placencia*	Unk.	Jun 2015	1	1	1	1				This study
<b>North America / Eastern Pacific Ocean</b>											
Mexico	Guerrero	R & NR	2014–2017	4	41	4	4	9.8	25–31	27–35	This study

## Mexico

A total of 41 inshore *T. truncatus* were photographed near Ixtapa/Zihuatanejo and Barra de Potosí in Guerrero, southern Mexico (17° 34' N, 101° 29' W; Fig. 2), during dedicated PI studies between 2014 and 2017 (K. Audley unpubl. data). In this region of the Mexican Pacific, oceanic habitat borders a narrow continental shelf with a steep slope and depths >40 m within 2 km of shore.

## PI and analysis

Images were taken with digital SLR cameras equipped with 75–400 m telephoto lenses for PI studies carried out as part of various research projects in Belize and Mexico (e.g. Campbell et al. 2002, Kerr et al. 2005, Rojas Arias 2013, Ramos et al. 2016). Dorsal fin photographs were visually inspected and rated using standard methodology to identify the dolphins according to scarring and natural markings (Defran et al. 1990). Existing catalogs were examined alongside sighting data from Oceanic Society records at Turneffe, the Drowned Cayes, and a 2013 baseline study at PHMR. Photo-ID catalogs for CBWS and Guerrero were created as part of this study, and for baseline monitoring of dolphin communities in these areas. Where possible, photos of full bodies were examined, but in some ID catalogs (e.g. Turneffe, Drowned Cayes), photos gathered from 1992 to 2002 were restricted to the dorsum and dorsal fin.

All PI dolphins were examined for LLD, i.e. the presence of multiple, raised, ulcerated cutaneous nodules, white to pink in color, as previously described (Reif et al. 2006, Van Bressem et al. 2007, 2009, 2015, Murdoch et al. 2008, Daura-Jorge & Simões-Lopes 2011). Dolphins were categorized as either positive, negative, or possibly affected by LLD. Relative size and progression of the lesions were measured using the percentage of lesion cover relative to the area of each side of the dorsal fin (DFA; Daura-Jorge & Simões-Lopes 2011). Measurements of relative lesion cover were gathered using ImageJ 1.50c (National Institutes of Health) by manually cropping dorsal fin photos along the edge of the fin and shifting image color threshold, then using a free-hand selection tool to extract a selection of the lesioned and non-lesioned surface area on each side of the fin. Relative lesion size was expressed as a percentage:  $p = A_{\text{lesion}}/A_{\text{dorsal}} \times 100$ , where  $A_{\text{lesion}}$  represents lesion area, and  $A_{\text{dorsal}}$  is the 1-sided DFA. Relative lesion size was further categorized as small (<10%),

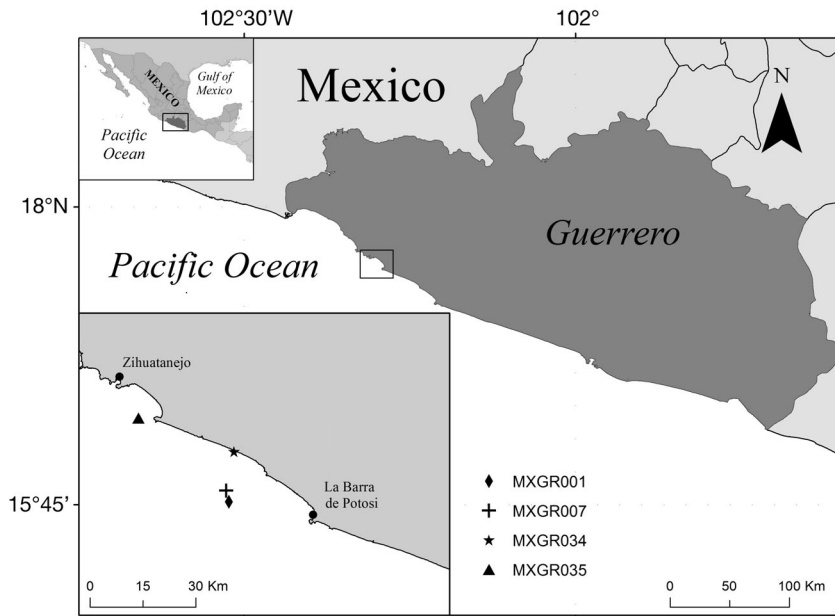


Fig. 2. First sighting locations of individual bottlenose dolphins *Tursiops truncatus* affected with lobomycosis-like disease in the state of Guerrero along the southwestern Pacific coast of Mexico

medium (10–20%), large (20–50%), or very large (>50%) (Daura-Jorge & Simões-Lopes 2011, Van Bresseem et al. 2015). Dolphins with high sighting rates over multiple years (high site fidelity) were classified as residents. Age class (calf, juvenile, adult) was estimated from relative body size and historical sighting records, whenever possible. Calves have a body size no bigger than one-third of that of an adult and are most of the time seen accompanying an adult (Campbell et al. 2002). Sex was determined opportunistically at the surface or underwater or, for adult females, by their regular association with a calf during repeated sightings. Prevalence of LLD was defined as the number of LLD positives versus the total number of PI dolphins for each region. Persistence of the disease could be examined in dolphins that were re-sighted over months and years (Table 1). Salinity (PSU) and sea surface temperature (SST) for each location are provided in Table 1 (Kerr et al. 2005, Fiedler & Talley 2006, LaCommare et al. 2008, Wildtracks 2011, SACD 2013, Foley et al. 2015, Liñán-Caballo et al. 2016).

## RESULTS

Approximately 8000 photographs of 411 PI dolphins taken during a 26 yr period were examined during this study. Ten adult dolphins were LLD-positive in 2001–2017, including 6 individuals from

Belize and 4 from Mexico (Tables 1 & 2). The clinical aspect of the lesions was similar in the 10 affected dolphins, i.e. small to very large, white to gray or pinkish, raised ulcerated granulomas on the dorsal fin, rostrum, flukes, and peduncle (Figs. 3 & 4). LLD persisted for at least 12 yr in an adult from Turneffe (BZTA103), 5 yr in a dolphin from the Drowned Cayes (BZDC042) and in an individual from Guerrero (MXGR035), and at least 2 yr in 2 adults from Guerrero (MXGR007, MXGR034). The first sighting location for each animal was plotted in ArcGIS (Figs. 1 & 2).

## Belize

In Belize, LLD affected 6 of the 371 photo-identified inshore *Tursiops truncatus* (Fig. 1, Tables 1 & 2). Five cases occurred in dolphins living close to the mainland, and only 1 was in an individual from Turneffe Atoll. LLD was not detected in the 16 dolphins identified in CBWS, northern Belize (Table 1). In the Drowned Cayes, LLD was observed in 2 dolphins: BZDC042 (Fig. 3A) and BZDC154 identified from 1997 to 2011 (Table 1), with a 4.3% prevalence for the period 2005–2017. Among the 179 dolphins identified at Turneffe Atoll from 1992 to 1996, and from 2001 to 2016 (Table 1), only 1 female (BZTA103, Fig. 3B) had LLD. In 2001, the female showed a mild form of the disease, with small lesions affecting both sides of the dorsal fin that progressively expanded until the last sighting in February 2012. In the period 2001–2016, prevalence was low (1%, N = 98) at Turneffe. In PHMR, 2 (BZPH004, BZPH015, Fig. 3C) of 28 (7.1%) identified dolphins had cutaneous disorders compatible with LLD from June to September 2013 (Tables 1 & 2). The dolphins were observed in the same group on 2 occasions. On 24 June 2015, a fisherman found a dead bottlenose dolphin (BZPA001) stranded in Placencia (Fig. 1, Table 2), southern Belize (Fig. 3D,E). Several photographs but no biological samples were taken. The dolphin showed extensive LLD lesions on various body parts (Fig. 3D,E, Table 2). Revision of the PI catalogs from the Drowned Cayes and Turneffe Atoll covering the period 1992–1999 did not reveal any additional true positives. However, possible LLD lesions were seen in 1 additional dolphin in 1997 and 2 dolphins from 2005–2017 in the Drowned Cayes, 2 dolphins from



Table 2. Details of adult inshore bottlenose dolphins *Tursiops truncatus* affected by lobomycosis-like disease in Belize (BZ) and Mexico (MX). DC: Drowned Cayes; TA: Turneffe Atoll; PH: Port Honduras Marine Reserve; PA: Placencia; GR: Guerrero; Fem.: female; Unk.: unknown

Dolphin ID	Sex	Date of encounter (yyyy.mm.dd)		Description
		First	Last	
<b>Belize</b>				
BZDC042	Unk.	1997.06.30	2012.08.13	Gray and white ulcerated granulomas across the dorsal fin, mostly on the right, with sparse lesions across its body. First imaged in 1997 without disease, lesions were first documented in 2006 and slowly expanded through 2012.
BZDC154	Unk.	2011.08.11		The leading edge of the dorsal fin presented with white to gray lesions, mostly on the right.
BZTA103	Fem.	2001.04.28	2012.04.22	Small white, granulomatous lesions on the trailing edge of the dorsal fin that slowly spread to the base and ulcerated on the right side in 2001 to 2012.
BZPH004	Unk.	2013.06.27	2013.07.13	White and pink ulcerated lesions along the leading edge of both sides of the dorsal fin, with cutaneous nodules extending across the dorsum.
BZPH015	Unk.	2013.07.04	2013.07.05	Leading edge of the dorsal fin presented with white and pink ulcerated granulomas, and nodules across the dorsum. Lesion-covered rostrum was bulbous and appeared deformed.
BZPA001	Unk.	2015.06.24		Stranded with extensive white and gray, raised, and numerous lesions across all parts of the body imaged (rostrum, flukes, peduncle).
<b>Mexico</b>				
MXGR001	Unk.	2015.01.30	2015.02.18	White ulcerated granulomas across the leading edge and middle of the dorsal fin, right side of the peduncle, and flukes.
MXGR007	Unk.	2015.02.15	2016.01.29	Sparse white ulcerated lesions along the trailing edge of the dorsal fin and across its left flank.
MXGR034	Unk.	2016.01.29	2017.03.07	Pinkish lesions/granulomas concentrated on the leading edge of the dorsal fin.
MXGR035	Unk.	2014.03.08	2016.02.23	Extensive raised and ulcerated granulomas across most of the visible body including the peduncle, flukes, and both sides of the dorsal fin.

Turneffe, and 2 from PHMR, but either image quality was too poor for diagnosis or the lesions were too small for confirmation of LLD. National prevalence for Belize was 1.6 %, ranging from 0–7.1 % across the 4 study sites (Table 1).

The relative size of LLD lesions in individual dolphins (Fig. 5A) plotted over time illustrates variability in lesion cover and progression in dolphins from different localities in Belize. Relative lesion size affecting the dorsal fin was small in the LLD-positive dolphin (BZTA103) at Turneffe Atoll, progressing slowly over a 12 yr period from <1 % DFA cover to about 4 % (Fig. 5A). Lesions were small to medium in BZDC042 in 2006 on the right (13.7 %) and left (4.8 %) side of the dorsal fin, spreading by more than 15 % on each side by 2012 (Fig. 5A). Lesion size in dolphins at PHMR ranged from small to very large (Fig. 5A).

SSTs and salinity ranged from the lowest at PHMR, where numerous waterways flow into the sea (Fig. 1),

to the highest salinity and warmest waters at the Drowned Cayes and Turneffe (Table 1).

A single adult *Stenella frontalis* of a group of 24 animals sighted in PHMR on 13 August 2013 had extensive cutaneous nodules across its dorsal fin and right flank consistent with LLD (Figs. 1 & 6).

## Mexico

Four resident adults of 41 inshore *T. truncatus* photographed in Guerrero from 2014 to 2017 were found positive for LLD (Fig. 4, Tables 1 & 2). The dolphins were sighted within 15 km from the shore, in deeper waters on average than dolphin communities in the western Caribbean Sea in Belize. Two dolphins (MXGR007 and MXGR034) were sighted together once. Lesions of different sizes were noted: small in MXGR001 (Fig. 4A, Table 2), large in MXGR007 (Fig. 4B) and MXGR034 (Fig. 4C), and very large in




Fig. 3. Lobomycosis-like disease (LLD) in inshore bottlenose dolphins *Tursiops truncatus* from different areas of Belize's Caribbean coast: (A) BZDC042 in the Drowned Cayes; (B) BZTA103 at Turneffe Atoll; and (C) BZPH004 in Port Honduras Marine Reserve. Extensive LLD on the (D) flukes and (E) rostrum of dolphin BZPA001, stranded in Placencia on 24 June 2015




Fig. 4. Lobomycosis-like disease (LLD) in inshore bottlenose dolphins *Tursiops truncatus* from Guerrero State on the Pacific coast of southwestern Mexico, near Ixtapa/Zihuatanejo and Barra de Potosí. LLD lesions varied in size and coverage in (A) MXGR001, (B) MXGR007, and (C) MXGR034, and extended over much of the visible body in (D) MXGR035



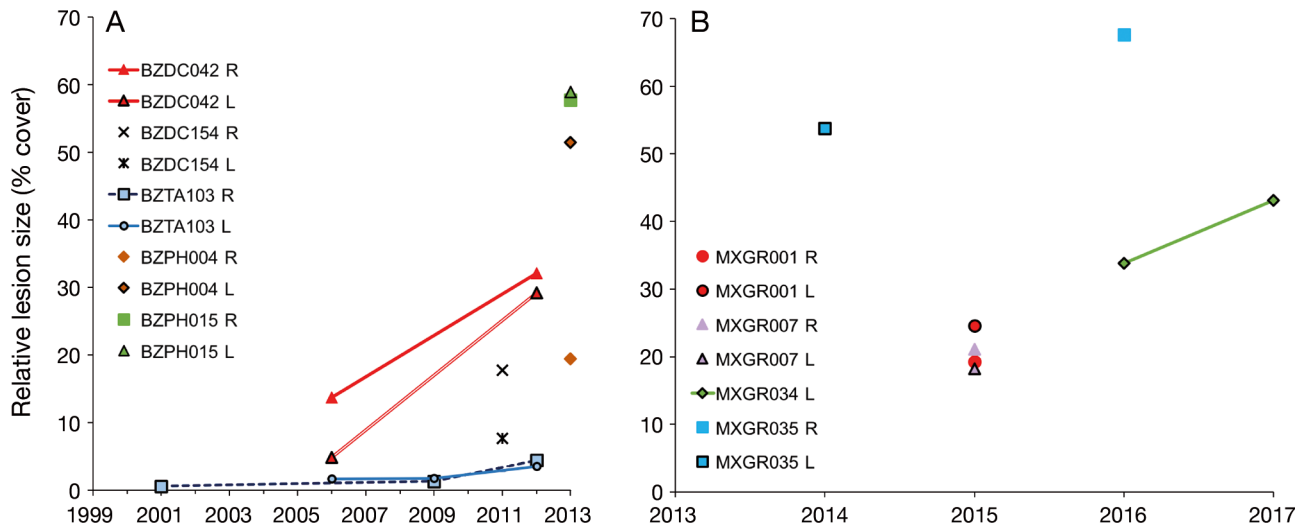


Fig. 5. Relative lesion coverage (% dorsal fin area) as a measure of progression of lobomycosis-like disease in bottlenose dolphins *Tursiops truncatus* in Belize and Mexico. (A) Lesions progressed slowly in BZTA103 and more rapidly in BZDC042 from 2001 to 2012. (B) Lesions progressed rapidly in MXGR034 from 2016 to 2017. R/L: right/left side

MXGR035 (Fig. 4D). Lesion cover increased nearly 10% over a single year in MXGR034 (Fig. 5B). Prevalence level reached 9.8% in this community (Table 2). SST and salinity were similar to those observed in the coastal waters of Belize, as was the presence of numerous river mouths (Fig. 2, Table 1).

## DISCUSSION

This study documents LLD in 10 inshore bottlenose dolphins inhabiting the Caribbean Sea off Belize ( $n = 6$ ) and the NE Pacific coastal waters of Mexico ( $n = 4$ ) and in a single Atlantic spotted dolphin in



Fig. 6. Lobomycosis like-disease in an adult Atlantic spotted dolphin *Stenella frontalis* sighted on 13 August 2013 in Port Honduras Marine Reserve in southern Belize



Belize, the first confirmed LLD case in this species. It thus extends the known distribution of LLD to southern Mexico and represents the northernmost report along the Pacific coast of the Americas. Until now, Golfo Dulce, Costa Rica, was the northernmost case location (Bessesen et al. 2014). The detection of LLD in dolphins from Belize also bridges the gap in the geographical distribution of LLD along the Atlantic coasts of North and South America. The apparent absence of LLD in the southern Gulf of Mexico and in most of the Caribbean Sea may also be due to a scarcity of field research effort. Only 2 other cases of LLD have been documented in the Caribbean Sea: (1) a *Tursiops truncatus* photographed in the Sabana-Camagüey Archipelago, northern Cuba, in 2008–2014 (López et al. 2015); and (2) an adult male *T. truncatus* stranded on Isla Margarita, Venezuela, in 2004 (Bermúdez et al. 2009). LLD was not encountered during a dedicated study of external body conditions in 3 small cetacean species, including *T. truncatus*, in the waters of Aruba in 2010–2011 (Luksenburg 2014). Many other areas remain unstudied, and clearly, further research on lobomycosis and LLD in cetaceans is needed in Central America and Mexico.

During this study, LLD prevalence levels varied between 1% (Turneffe, Belize,  $N = 98$ ) and 9.8% (Guerrero, Mexico,  $N = 41$ ). Comparable prevalence levels of lobomycosis and LLD ranged between 1.6 and 30% in other *T. truncatus* communities from the Americas (Reif et al. 2006, Van Bresseem et al. 2007, 2015, Daura-Jorge & Simões-Lopes 2011, Bessesen et al. 2014). In Belize, prevalence ranged from 1% (Turneffe) to 7.1% (PHMR,  $N = 29$ ) in 4 dolphin communities. The significance of these differences in prevalence could not be assessed, as the research effort was not comparable in the 4 communities. Nevertheless, it is worth noting that the highest number of infected dolphins occurred in southern Belize (PHMR and Placencia), and the Drowned Cayes near Belize City, 2 areas heavily impacted by anthropogenic activities, including pervasive pollution and increasing levels of vessel traffic (Bacchus et al. 2009). Several rivers (Fig. 1) contaminated by agricultural run-off and untreated effluent from Belize, Guatemala, and Honduras flow into the Caribbean around PHMR and Placencia (DEMNM 2008, Carrilli et al. 2009, Foley et al. 2015). Similarly, in the Drowned Cayes, the marine environment where 4.3% of the 47 dolphins were affected receives flood waters from nearby Belize City and the Belize River that are also very polluted, in addition to pollution from tourists and residential activities on the coastal cayes. This region is threatened by the direct dis-

posal of hundreds to thousands of liters of sewage yearly, heavy nutrient loads (i.e. phosphorus) from agriculture and aquaculture-associated run-off, and increases in the effluent of marine vessels, including discharge of sewage and fossil fuels associated with tourism and commercial vessels (DEMNM 2008). Turneffe is far from the mainland and is largely undeveloped, with fewer anthropogenic impacts, though the impacts of numerous sources of pollution including marine debris, vessel traffic, and unsustainable development (Ramos et al. 2016) are unknown. Flooding during the rainy season sometimes also results in waters from coastal Belize reaching the marine environment around Turneffe (Wildtracks 2011). The marine ecosystem of Guerrero, Mexico, is contaminated by pesticides, untreated waste waters, and run-off from shrimp aquaculture and terrestrial agriculture (Páez-Osuna et al. 1998, Leyva-Cardoso et al. 2003, Liñán-Cabello et al. 2016). The high LLD prevalence (9.8%,  $N = 41$ ) in this community is of great concern, and coupled with dramatic decreases in sighting rates from 2014 to 2017 could suggest that this population is facing major negative impacts (K. Audley unpubl. data). Moreover, urbanization and industrialization are developing at a fast pace along the southern coast of Mexico.

No correlation was apparent between salinity and SST and the prevalence or severity of LLD. Differences in freshwater input were suggested to play a role in the development and persistence of lobomycosis in LLD-afflicted *T. truncatus* communities in Florida (Burdett Hart et al. 2011). However, in South America, the highest LLD prevalence level was encountered in dolphins living in a marine area with high salinity (33–35.1) (Van Bresseem et al. 2015).

Lobomycosis and LLD in Delphinidae have been reported along the Atlantic and Pacific coasts of the Americas since the early 1970s, with evidence of the disease dating back to the 1950s on Florida's Atlantic coast (Caldwell et al. 1975, Simões-Lopes et al. 1993, Van Bresseem et al. 2007, 2015, Daura-Jorge & Simões-Lopes 2011, Bessesen et al. 2014). The earliest confirmed records of LLD in *T. truncatus* from Belize date back to 2001 (Turneffe) and 2006 (Drowned Cayes). An undetermined skin disease was briefly mentioned in 2 dolphins from the Drowned Cayes community in 1997–1999 (Kerr et al. 2005). However, we could not confirm if this was LLD, or if 1 of the affected dolphins was BZDC042. LLD is a chronic disease; it persisted at least 7 yr in 2 adult dolphins (BZTA103, BZDC042) from Belize, and 5 yr in 1 adult (MXGR035) from Mexico. Progression was slow in the LLD-positive dolphin at Turneffe, but faster in 2

others from the Drowned Cayes and Guerrero. As in other *T. truncatus* individuals from the Americas, disease progression varied between lesions and individuals (Murdoch et al. 2008, 2010, Burdett Hart et al. 2011, Van Bressem et al. 2015).

Although the status of inshore *T. truncatus* from Belize and southern Mexico remains unassessed, these small communities face an increasing number of anthropogenic pressures (e.g. overfishing, by-catch, habitat loss, pollution, and oil exploration activities) and may rapidly become vulnerable, even threatened with local extirpation, as has occurred in other small cetacean populations (Turvey et al. 2007, Vermeulen & Bräger 2015, Azevedo et al. 2017). Thus, any additional factors likely to negatively impact their populations should be avoided and carefully evaluated. Additional studies of the small-scale distribution of LLD and other skin disorders in cetaceans from Mexico and Central America should determine the factors favoring their occurrence, transmission, and prevalence levels. Samples should be taken for histological and molecular studies to examine etiologic agents.

The opportunistic discovery of LLD in an adult *Stenella frontalis* extends the list of species known to be susceptible to the disease, providing a strong incentive for targeted research of local populations of *S. frontalis* in the Caribbean Sea. Its detection in an area of high prevalence for LLD in *T. truncatus* suggests that multiple marine mammal species may be exposed to similar levels of environmental contamination as populations of *T. truncatus*. Little is known about the distribution and abundance of *S. frontalis* in Belizean waters, with only a handful of reports in the country, largely in pelagic habitats (Ramos et al. 2016).

It is recommended that the presence of LLD be recognized as a still poorly understood and potentially novel risk factor for Delphinidae in marine reserves of Belize, that deserves to be considered in any national marine mammal management plans and policies.

**Acknowledgements.** Thanks to all volunteers and staff of the Oceanic Society and the Toledo Institute for Development and Environment who supported the research and assisted with field data collection and analysis. Thanks to the Oceanic Society and Birgit Winning for access to historical records and to all researchers who created original PI catalogs in Belize, including the Cetacean Behavior Laboratory at San Diego State University, Kecia Kerr, Brittany Hancock-Hanser, Dori Dick, Katheryn Patterson, Katherine Cure, and Isidore Szczepaniak. We also thank Lisa Carne and Caryn Self-Sullivan for contributing data, and Stephanie Bousseau and Sarah Gumbleton for help with photo

analysis. Support from volunteers and the research team of the Whales of Guerrero Research Project are also gratefully acknowledged, especially Raul Fernando Ramirez Barragan for analyzing dolphin photos. Thanks to Joel Verde, Laura Rack, and the team at the Sarteneja Alliance for Conservation and Development in Sarteneja for collaborating with marine mammal research. Thanks also to Kim E. McCabe and students at Beaver Country Day School, of Brookline, MA, for traveling to Sarteneja for research. Research at Turneffe Atoll, the Drowned Cayes, and Port Honduras Marine Reserve was conducted under research permits granted by the Fisheries and Forest Departments of Belize.

#### LITERATURE CITED

- ✦ Azevedo AF, Carvalho RR, Kajin M, Van Sluys M, Bisi TL, Cunha HA, Lailson-Brito J Jr (2017) The first confirmed decline of a delphinid population from Brazilian waters: 2000–2015 abundance of *Sotalia guianensis* in Guanabara Bay, South-eastern Brazil. *Ecol Indic* 79:1–10
- ✦ Bacchus ML, Dunbar SG, Self-Sullivan C (2009) Characterization of resting holes and their use by the Antillean manatee (*Trichechus manatus manatus*) in the Drowned Cayes, Belize. *Aquat Mamm* 35:62–71
- ✦ Bermúdez L, Van Bressem MF, Reyes-Jaimes O, Sayegh AJ, Paniz-Mondolfi AE (2009) Lobomycosis in man and lobomycosis-like disease in bottlenose dolphin, Venezuela. *Emerg Infect Dis* 15:1301–1303
- ✦ Bessesen BL, Oviedo L, Burdett Hart L, Herra-Miranda D and others (2014) Lacaziosis-like disease among bottlenose dolphins *Tursiops truncatus* photographed in Golfo Dulce, Costa Rica. *Dis Aquat Org* 107:173–180
- ✦ Bossart GD (1984) Suspected acquired immunodeficiency in an Atlantic bottlenosed dolphin with chronic-active hepatitis and lobomycosis. *J Am Vet Med Assoc* 185: 1413–1414
- ✦ Burdett Hart L, Rotstein DS, Wells RS, Bassos-Hull K, Schwacke LH (2011) Lacaziosis and lacaziosis-like prevalence among wild, common bottlenose dolphins *Tursiops truncatus* from the west coast of Florida, USA. *Dis Aquat Org* 95:49–56
- ✦ Caldwell DK, Caldwell MC, Woodard JC, Ajello L, Kaplan W, McLure HM (1975) Lobomycosis as a disease of the Atlantic bottle-nosed dolphin (*Tursiops truncatus* Montagu, 1821). *Am J Trop Med Hyg* 24:105–114
- Campbell GS, Bilgre BA, Defran RH (2002) Bottlenose dolphins (*Tursiops truncatus*) in Turneffe Atoll, Belize: occurrence, site fidelity, group size, and abundance. *Aquat Mamm* 28:170–180
- ✦ Carilli JE, Prouty NG, Hughen KA, Norris RD (2009) Century-scale records of land-based activities recorded in Mesoamerican coral cores. *Mar Pollut Bull* 58:1835–1842
- ✦ Daura-Jorge FG, Simões-Lopes PC (2011) Lobomycosis-like disease in wild bottlenose dolphins *Tursiops truncatus* of Laguna, southern Brazil: monitoring of a progressive case. *Dis Aquat Org* 93:163–170
- de Vries GA, Laarman JJ (1973) A case of Lobo's disease in the dolphin *Sotalia guianensis*. *Aquat Mamm* 1:26–33
- Defran RH, Shultz GM, Weller DW (1990) A technique for the photographic identification and cataloging of dorsal fins of the bottlenose dolphin (*Tursiops truncatus*). *Rep Int Whaling Comm (Spec Issue)* 12:53–55
- DEMME (Department of the Environment Ministry of Natural Resources and the Environment) (2008) National

- plan of action for the control of land-based sources of marine pollution in Belize: final report. [www.cep.unep.org/content/about-cep/amep/belize-npa-feb-28-08-draft.pdf/at\\_download/file](http://www.cep.unep.org/content/about-cep/amep/belize-npa-feb-28-08-draft.pdf/at_download/file) (accessed 23 Jan 2016)
- Dick DM, Hines EM (2011) Using distance sampling techniques to estimate bottlenose dolphin (*Tursiops truncatus*) abundance at Turneffe Atoll, Belize. *Mar Mammal Sci* 27:606–621
- Esperón F, García-Párraga D, Bellière EN, Sánchez-Vizcaino JM (2012) Molecular diagnosis of lobomycosis-like disease in a bottlenose dolphin in captivity. *Med Mycol* 50:106–109
- ✦ Fiedler PC, Talley LD (2006) Hydrography of the eastern tropical Pacific: a review. *Prog Oceanogr* 69:143–180
- Foley J, Alvarez M, Barona T, Moore R, Requena E, Warns D (2015) TIDE (Toledo Institute for Development and the Environment) water quality report. TIDE Research & Monitoring Department, Toledo
- Kerr KA, Defran RH, Campbell GS (2005) Bottlenose dolphins (*Tursiops truncatus*) in the Drowned Cayes, Belize: group size, site fidelity and abundance. *Caribb J Sci* 41: 172–177
- ✦ Kiszka J, Van Bresse MF, Pusineri C (2009) Lobomycosis-like disease and other skin conditions in Indo-Pacific bottlenose dolphins *Tursiops aduncus* from the Indian Ocean. *Dis Aquat Org* 84:151–157
- ✦ LaCommare KS, Self-Sullivan C, Brault S (2008) Distribution and habitat use of Antillean manatees (*Trichechus manatus manatus*) in the Drowned Cayes area of Belize, Central America. *Aquat Mamm* 34:35–43
- ✦ Lane EP, de Wet M, Thompson P, Siebert U, Wohlsein P, Plön S (2014) A systematic health assessment of Indian ocean bottlenose (*Tursiops aduncus*) and Indo-Pacific humpback (*Sousa plumbea*) dolphins incidentally caught in shark nets off the KwaZulu-Natal Coast, South Africa. *PLOS ONE* 9:e107038
- ✦ Leyva-Cardoso DO, Ponce-Vé G, Botello AV, Díaz-González G (2003) Persistent organochlorine pesticides in coastal sediments from Petacalcoay, Guerrero, Mexico. *Bull Environ Contam Toxicol* 71:1244–1251
- ✦ Liñán-Cabello MA, Olivos-Ortiz A, Quijano-Scheggia S, Muñiz D, Anguiano ML, Ortega-Ortiz CD (2016) Effects of terrestrial runoff on the coral communities in Santiago Bay, Colima, Mexican Pacific Coast. *Rev Biol Trop* 64: 1185–1200
- Lobo JO (1930) Nova especie de blastomycose. *Bras Med* 44: 1227
- Lobo JO (1931) Um caso de blastomycose produzido por uma espécie nova, encontrada em Recife. *Rev Med Pernamb* 1:763–765
- López N, Fernández-Ruenes G, Sánchez-Martínez L, Cruz D, Sánchez-Campos L, Guevara C (2015) Reporte de lesiones cutáneas a través de la fotoidentificación en delfines *Tursiops truncatus* de la Costa Norte de Matanzas, Cuba. In: X Congreso de Ciencias del Mar MarCuba '2015, Nov 16–20, Havana
- Luksenburg JA (2014) Prevalence of external injuries in small cetaceans in Aruban waters, Southern Caribbean. *PLOS ONE* 9:e88988
- ✦ Minakawa T, Ueda K, Tanaka M, Tanaka N and others (2016) Detection of multiple budding yeast cells and a partial sequence of 43-kDa glycoprotein coding gene of *Paracoccidioides brasiliensis* from a case of lacaziosis in a female pacific white-sided dolphin (*Lagenorhynchus obliquidens*). *Mycopathologia* 181:523–529
- ✦ Murdoch ME, Reif JS, Mazzoil M, McCulloch SD, Fair PA, Bossart GD (2008) Lobomycosis in bottlenose dolphins (*Tursiops truncatus*) from the Indian River Lagoon, Florida: estimation of prevalence, temporal trends, and spatial distribution. *EcoHealth* 5:289–297
- ✦ Murdoch ME, Mazzoil M, McCulloch S, Bechdel S, O'Corry-Crowe G, Bossart GD, Reif JS (2010) Lacaziosis in bottlenose dolphins *Tursiops truncatus* along the coastal Atlantic Ocean, Florida, USA. *Dis Aquat Org* 92:69–73
- ✦ Páez-Osuna F, Guerrero-Galván SR, Ruiz-Fernández AC (1998) The environmental impact of shrimp aquaculture and the coastal pollution in Mexico. *Mar Pollut Bull* 36: 65–75
- Palmer C, Peterson A (2014) First report of a lacaziosis-like disease (LLD) observed in the Australian snubfin dolphin (*Orcaella heinsohni*) in Darwin Harbour, Northern Territory, Australia. *North Territ Nat* 25:3–6
- ✦ Ramos EA, Castelblanco-Martínez DN, Niño-Torres CA, Jenko K, Auil Gomez NA (2016) A review of the aquatic mammals of Belize. *Aquat Mamm* 42:476–493
- ✦ Reif JS, Mazzoil MS, McCulloch SD, Varela RA, Goldstein JD, Fair PA, Bossart GD (2006) Lobomycosis in Atlantic bottlenose dolphins from the Indian River lagoon, Florida. *J Am Vet Med Assoc* 228:104–108
- Rojas Arias J (2013) Establecimiento de la línea de información de base para la especie *Tursiops truncatus* en la reserva marina de Puerto Honduras, Belice. MSc thesis, The College of the Southern Border, Chetumal
- ✦ Rotstein DS, Burdett LG, McLellan W, Schwacke L and others (2009) Lobomycosis in offshore bottlenose dolphins (*Tursiops truncatus*), North Carolina. *Emerg Infect Dis* 15:588–590
- SACD (Sarteneja Alliance for Conservation and Development) (2013) Corozal Bay Wildlife Sanctuary research and monitoring plan. Sarteneja, Corozal. <http://oceanecosur.com/images/ofe/vinculacion/vinculados/Corozal%20Bay%20Wildlife%20Sanctuary%20Monitoring%20Plan%20web.pdf> (accessed 13 May 2017)
- ✦ Sacristán C, Réssio RA, Castilho P, Fernandes NCCA and others (2016) Lacaziosis-like disease in *Tursiops truncatus* from Brazil: a histopathological and immunohistochemical approach. *Dis Aquat Org* 117:229–235
- ✦ Simões-Lopes PC, Paula GS, Xavier FM, Scaramelo AC (1993) First case of lobomycosis in a bottlenose dolphin from southern Brazil. *Mar Mamm Sci* 9:329–331
- ✦ Taborda PR, Taborda VA, McGinnis MR (1999) *Lacazia loboi* gen. nov., comb. nov., the etiologic agent of lobomycosis. *J Clin Microbiol* 37:2031–2033
- ✦ Tajima Y, Sasaki K, Kashiwagi N, Yamada TK (2015) A case of stranded Indo-Pacific bottlenose dolphin (*Tursiops aduncus*) with lobomycosis-like skin lesions in Kinkowan, Kagoshima, Japan. *J Vet Med Sci* 77:989–992
- ✦ Turvey ST, Pitman RL, Taylor BL, Barlow J and others (2007) First human-caused extinction of a cetacean species? *Biol Lett* 3:537–540
- Ueda K, Sano A, Yamate J, Itano Nakagawa E and others (2013) Two cases of lacaziosis in bottlenose dolphins (*Tursiops truncatus*) in Japan. *Case Rep Vet Med* 2013: 318548
- ✦ Van Bresse MF, Van Waerebeek K, Reyes JC, Félix F and others (2007) A preliminary overview of skin and skeletal diseases and traumata in small cetaceans from South American waters. *Lat Am J Aquat Mamm* 6:7–42
- ✦ Van Bresse MF, Raga JA, Di Guardo G, Jepson PD and others (2009) Emerging infectious diseases in cetaceans



worldwide and the possible role of environmental stressors. *Dis Aquat Org* 86:143–157

✦ Van Bressem MF, Simões-Lopes PC, Félix F, Kiszka JJ and others (2015) Epidemiology of lobomycosis-like disease in bottlenose dolphins *Tursiops* spp. from South America and southern Africa. *Dis Aquat Org* 117:59–75

✦ Vermeulen E, Bräger S (2015) Demographics of the disappearing bottlenose dolphin in Argentina: a common species on its way out? *PLOS ONE* 10:e0119182

✦ Vilela R, Bossart GD, St. Leger JA, Dalton LM and others (2016) Cutaneous granulomas in dolphins caused by novel uncultivated *Paracoccidioides brasiliensis*. *Emerg Infect Dis* 22:2063–2069

Wildtracks (2011) Turneffe Atoll management plan 2012–2017. Belize City, Belize. [www.turneffeatoll.org/app/webroot/userfiles/66/File/Final%20Turneffe%20Atoll%20Management%20Plan%2014%2009%202012%20Fisheries%20Edited.pdf](http://www.turneffeatoll.org/app/webroot/userfiles/66/File/Final%20Turneffe%20Atoll%20Management%20Plan%2014%2009%202012%20Fisheries%20Edited.pdf) (accessed 15 Jun 2017)

*Editorial responsibility: Stephen Raverty,  
Abbotsford, British Columbia, Canada*

*Submitted: August 28, 2017; Accepted: December 19, 2017  
Proofs received from author(s): February 27, 2018*