Ruptured yolk sacs and visceral fungi in emergent pink salmon alevins: histopathology and relation to marine survival

Gary D. Marty[1,3,*], Ronald A. Heintz[2]

[1]**Department of Anatomy, Physiology, and Cell Biology, School of Veterinary Medicine, University of California, 1 Shields Ave., Davis, California 95616-8732, USA**

[2]**National Marine Fisheries Service, Auke Bay Laboratory, 17109 Pt. Lena Loop Rd., Juneau, Alaska 99801-8344, USA**

[3]***Present address:*** **Animal Health Centre, Ministry of Agriculture and Lands, 1767 Angus Campbell Rd., Abbotsford, British Columbia V3G 2M3, Canada**

*Email: gdmarty@ucdavis.edu

Diseases of Aquatic Organisms 88:115–126 (2010)

Supplement 1. Additional figures

Fig. S1. (page 2) *Oncorhynchus gorbuscha*. Sagittal step-section no. 3 from an alevin sampled on the day of volitional emergence from artificial substrate; hematoxylin and eosin stain. (A) Overview of the swimbladder (sb) and surrounding structures: spinal cord (sc), notochord (n), kidney (k), stomach (s), yolk protein (yp) in intact yolk sac, and intestine (i). The cranial wall of the swimbladder is expanded by inflammation, whereas the caudal wall is distended by hemorrhage (h). The black rectangle outlines the area shown at higher magnification in B. (B) Inflammation around the cranial margin of the swimbladder surrounds fungal hyphae that extend dorsally into renal tubules and blood vessels (arrowheads)

Fig. S2. (page 3) *Oncorhynchus gorbuscha*; hematoxylin and eosin stain. (A) Sagittal step-section no. 4 of the same alevin shown in Fig. S1. The lumen of the swimbladder (sb) is distended by foreign material. The black rectangle outlines the area shown at higher magnification in C. (B) Sagittal step-section no. 5 of the same alevin shown in Fig. S1 includes the pneumatic duct (arrow) connecting the proximal digestive tract to the swimbladder; the base of the pneumatic duct is surrounded by hemorrhage (h). (C). Higher magnification of (A). The swimbladder lumen is filled with a mixture of acellular refractile material (r), colonies of bacterial rods (b), and fungal hyphae (arrowheads); fungal hyphae (arrowheads) are common among the inflammation in the wall of the swimbladder. sc: spinal cord; n: notochord; k: kidney; s: stomach; yp: yolk protein in intact yolk sac

Supplement 1. Additional figures (continued)

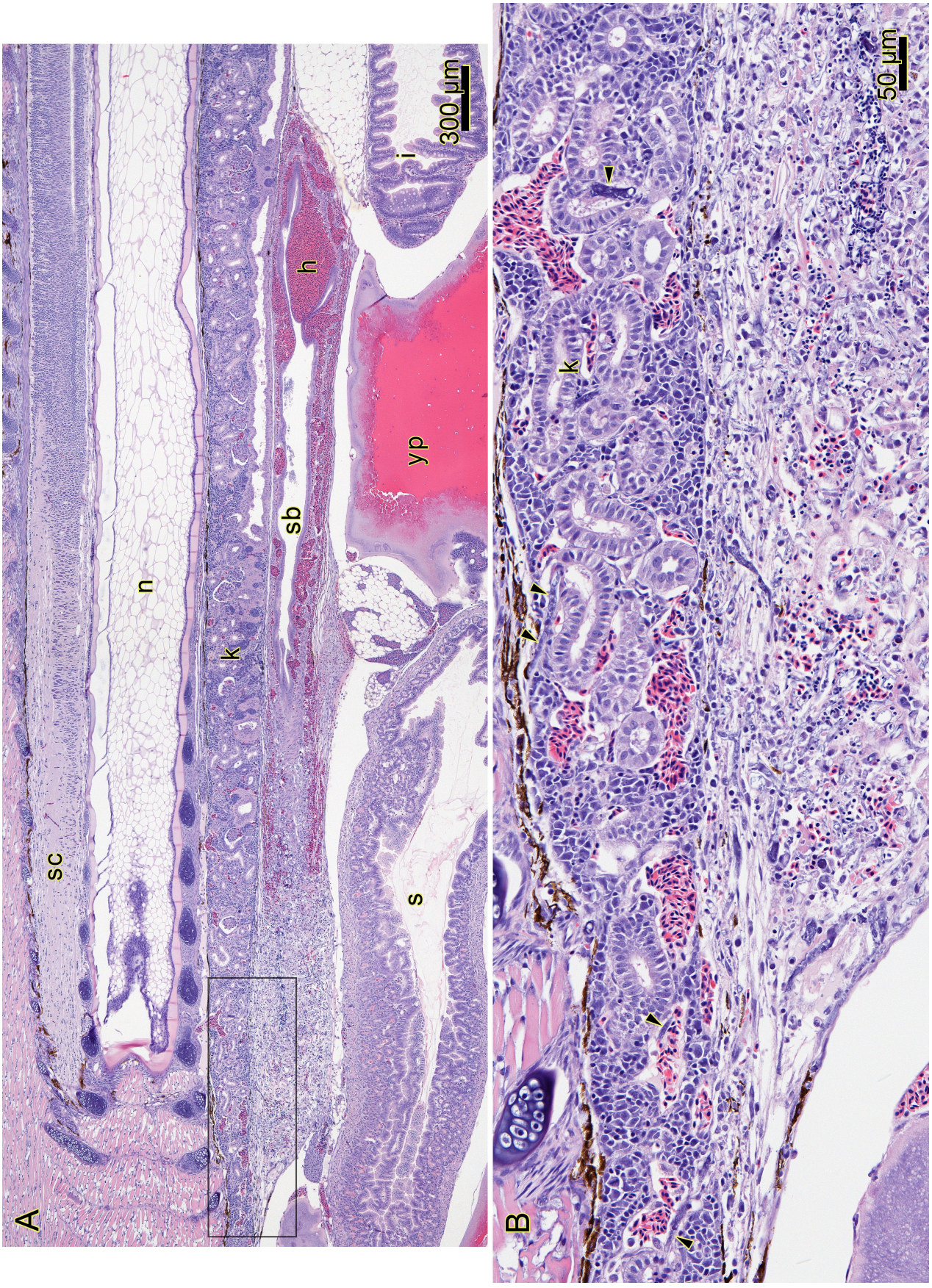

Fig. S1

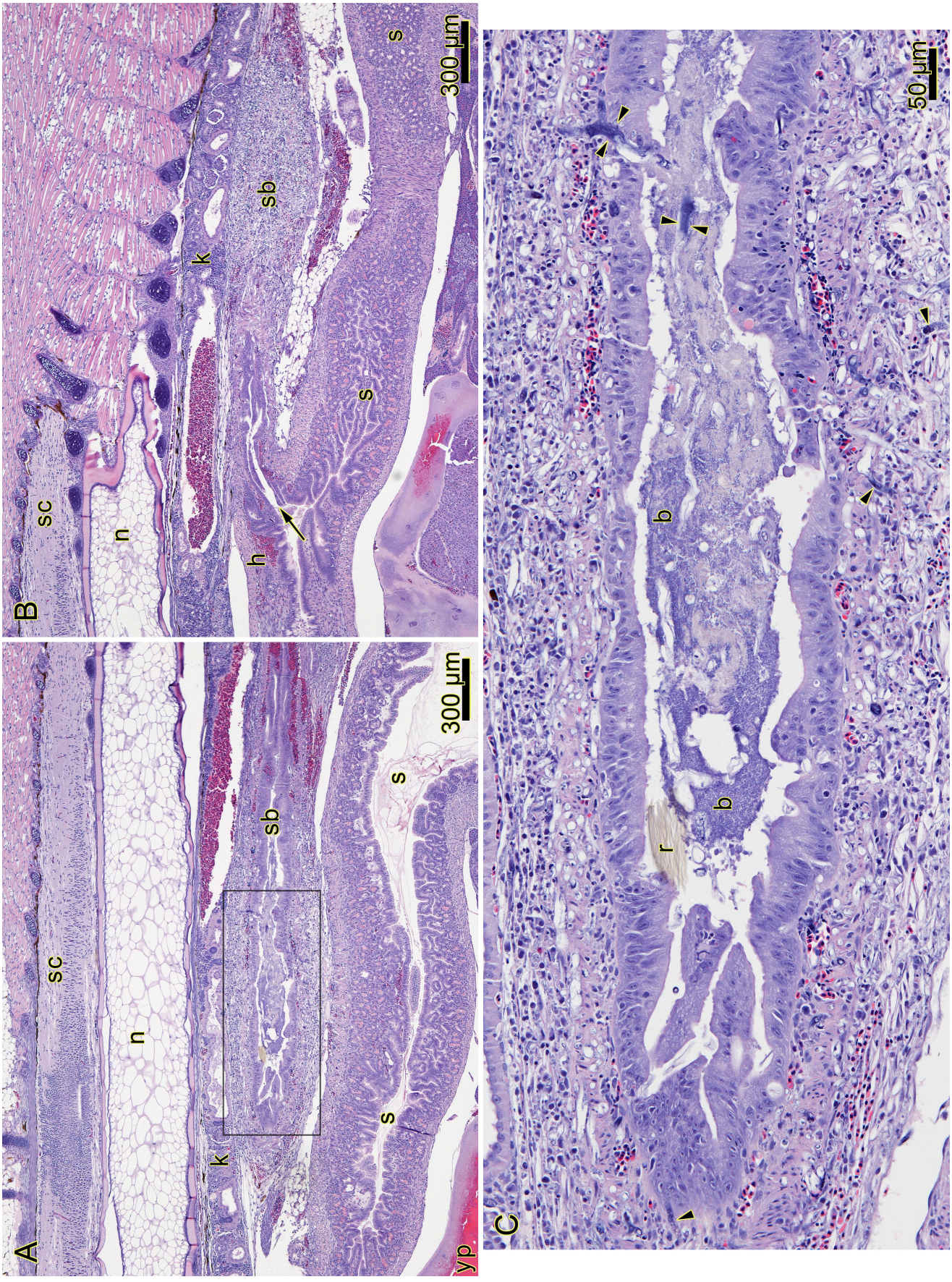

Fig. S2

Supplement 2. High resolution versions of Figs. 1–3 from the main article

Fig. 1. *Oncorhynchus gorbuscha*. Sagittal sections of alevins sampled on the day of volitional emergence from artificial substrate; hematoxylin and eosin stain. (A) Normal alevin with an intact yolk sac. (B) Step-section no. 4 through an alevin with a ruptured yolk sac (ys) and putative yolk protein in the ventral and caudal abdominal cavity (*); protein distends renal ducts. (C) Abnormal alevin with a ruptured yolk sac (ys) and free yolk protein surrounding the viscera (*); the intestinal epithelium is ulcerated (arrowhead), and putative yolk protein partly fills the intestine. (D) Higher magnification of ulcerated intestine in (C), with putative yolk proteins in the lamina propria (*) and cytoplasm of intestinal absorptive epithelial cells (arrow). ht: heart; i: intestine; k: kidney; s: stomach; yp: yolk protein within yolk sac. (A–C) Micrographs are the same magnification and are composites of 6×2 or 5×2 tiled originals (Marty 2007)

Fig. 2. *Oncorhynchus gorbuscha*; hematoxylin and eosin stain. (A) Step-section no. 3 from the fish in Fig. 1B. The archinephric duct and several renal tubules are distended by homogenous eosinophilic material (*), probably derived from yolk proteins. Urinary spaces (us) are distended by pale eosinophilic material, and some skeletal myofibers are necrotic (arrows). (B) Step-section no. 6 from the fish in Fig. 1B. Tubular epithelial cells in the anterior kidney contain brightly eosinophilic cytoplasmic protein droplets (arrowheads), and many interstitial cells contain dull eosinophilic protein. (C) Step-section no. 6 from the fish in Fig. 1B. Hepatocyte cytoplasm contains abundant brightly eosinophilic droplets of putative yolk proteins (arrowheads)

Fig. 3. *Oncorhynchus gorbuscha*; hematoxylin and eosin stain. (A) Overview of stomach (s) and surrounding structures: trunk kidney (k), intestinal ceca (ic), and yolk protein (yp) within yolk sac; box outlines area shown at greater magnification in (B). (B) Fungal hyphae in lumen stain deeply basophilic, whereas hyphae in the gastric wall stain poorly (arrowheads). Invasive hyphae are associated with hyperplastic gastric epithelium (arrows) and smooth muscle cells with karyorrhexis and karyolysis (*)

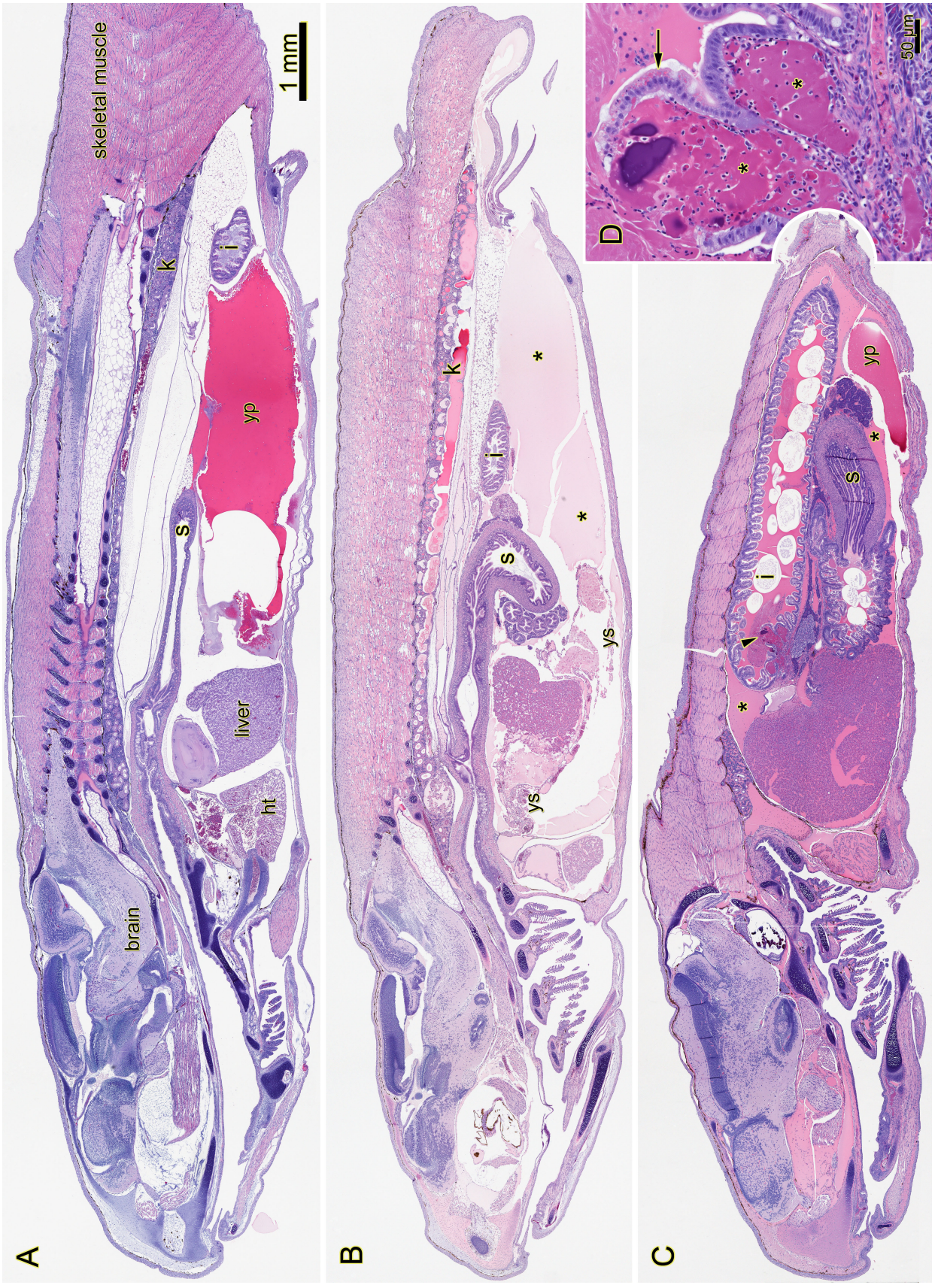

Fig. 1 (high resolution version)

Supplement 2. High resolution versions of Figs. 1–3 from the main article (continued)

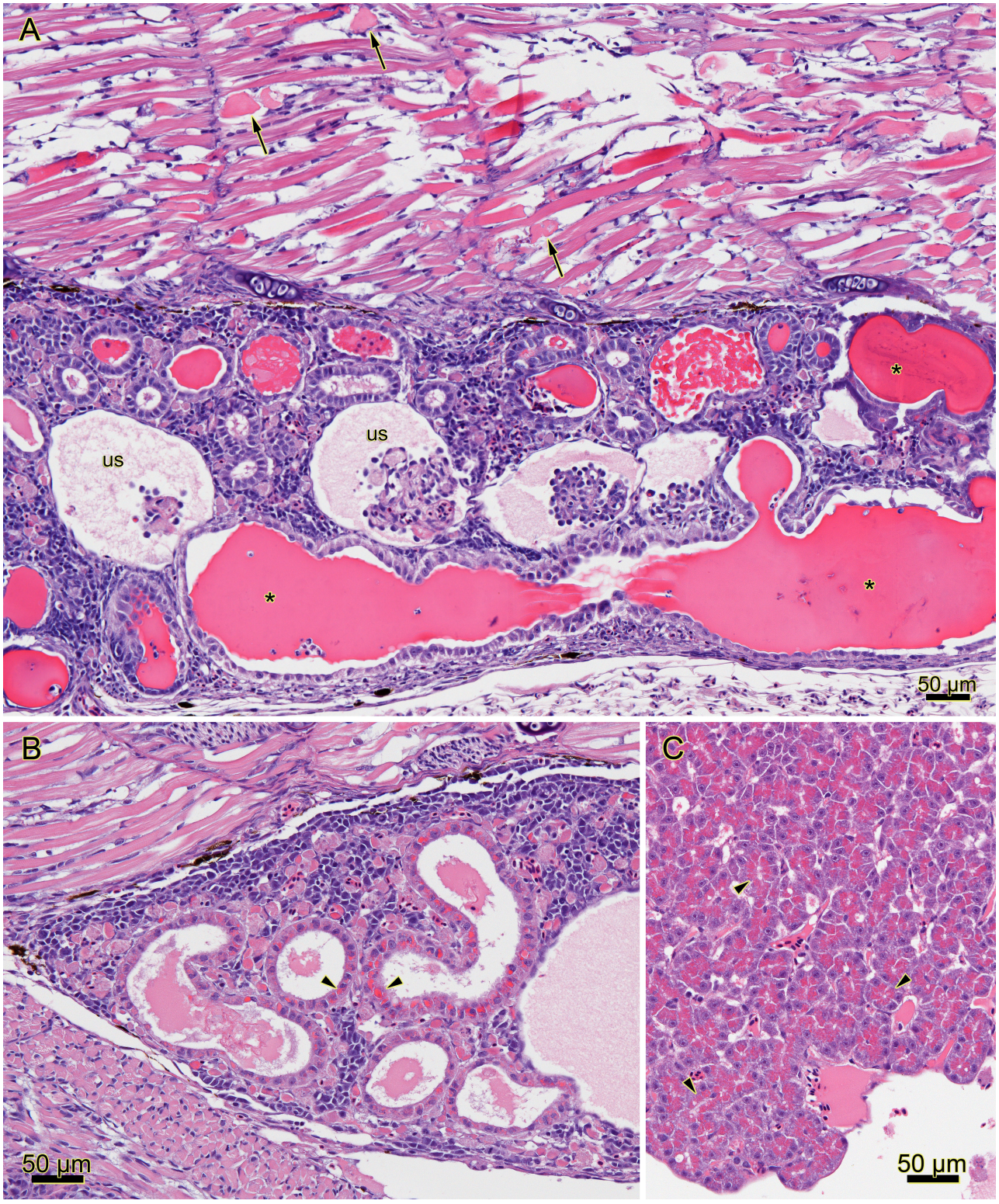

Fig. 2 (high resolution version)

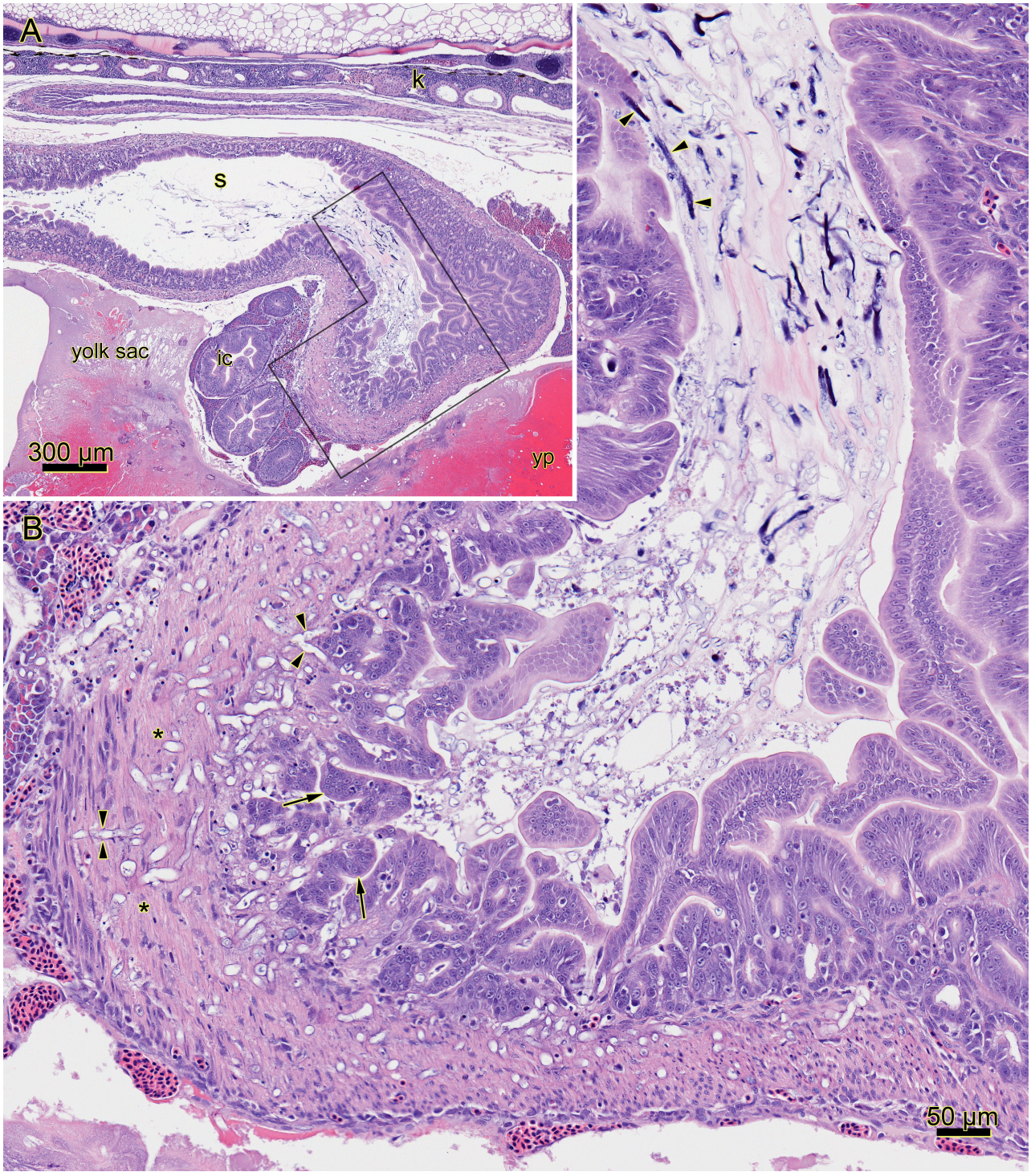

Fig. 3 (high resolution version)