Vol. 22: 143-146, 1995 | DISEASES OF AQUATIC ORGANISMS Dis aquat Org | Published June 15

NOTE

A *Steinhausia*-like infection in the ovocytes of Sydney rock oysters *Saccostrea commercialis*

T. J. Anderson[1], P. M. Hine[2], R. J. G. Lester[1]

[1]Department of Parasitology, The University of Queensland, Brisbane 4072, Australia
[2]Department of Agriculture, South Perth, 6151 Western Australia, Australia

ABSTRACT: A low intensity *Steinhausia*-like infection was observed in histological sections of the gonads of 7 out of 10 female Sydney rock oysters *Saccostrea commercialis* obtained from a farm in Queensland, Australia. Parasitophorous vacuoles occurred within the nucleus and cytoplasm of ovocytes and contained up to 18 unicells (in cross section). Infection caused an intense hemocyte infiltration. The parasite may cause problems in *S. commercialis* culture at higher infection intensities.

KEY WORDS: *Steinhausia*-like infection · Protista · *Saccostrea commercialis* · Egg · Oyster

Few microsporans have been described from bivalve molluscs. *Steinhausia ovicola* Léger & Hollande, 1917 infects the ova of *Ostrea edulis* in France. Similarly, *S. mytilovum* Field, 1924 (Sprague 1965) infects the ova of *Mytilus edulis* along the Atlantic coast of the USA and *M. galloprovincialis* in Italy (Vincentiis & Renzoni 1963), Spain (Figueras et al. 1991) and USA (Hillman 1991). The only other identified microsporan infecting bivalve molluscs is *Microsporidium rapuae* (Jones 1981) which forms cysts within the connective tissue surrounding the gut epithelium of *Ostrea lutaria* in New Zealand. This paper describes a *Steinhausia*-like parasite (Microsporea: Minisporida: Chytridiopsidae) that was observed in histological sections of female Sydney rock oysters obtained from an oyster farm in Elimbah Creek, Queensland, Australia.

Materials and methods. Oysters were obtained from an oyster farm in Elimbah Creek, Queensland, Australia (27° 03' S, 153° 07' E). They were fixed in Davidson's fluid (Humason 1979) for 6 to 18 h at 20°C, stored in 10% buffered formalin, dehydrated in alcohol and embedded in paraffin. Sections were stained with haematoxylin and eosin and Tworts Gram stain (Bancroft & Stevens 1985). Measurements were taken from the histological sections. Average measurements were derived from at least 10 observations and are followed by the standard deviation.

Results. Infection with the *Steinhausia*-like parasite was observed in the eggs of 7 out of 10 Sydney rock oysters. The intensity of infection was low; generally fewer than 1% of ovocytes appeared infected in histological sections. All developmental stages of the parasites appeared within spherical or subspherical parasitophorous vacuoles (Fig. 1A to F). As reported by Sprague (1965) for *Steinhausia mytilovum*, it was not possible to distinguish among the developmental stages of *Steinhausia*-like parasite. What may be the earliest developmental stage seen was a small uninucleate cell (Fig. 1A). Apparently more advanced stages often had nuclei associated in pairs or fours or each nucleus had 2 or 4 parts close together indicative of division (Fig. 1B, C, E). Parasitophorous vacuoles (PVs) measured up to 16.2 µm in greatest diameter ($\bar{x}$ = 10.6 ± 0.98 µm). Up to 18 cells, about 1.7 ± 0.36 µm in diameter, probably spores, were visible in some sectioned PVs (Fig. 1C to E). Others had up to 10 cells, 4.1 ± 0.69 µm in diameter (Fig. 1B). An infected egg usually contained only 1 PV which often occurred in the cytoplasm (Fig. 1C) but sometimes in the nucleus (Fig. 1D). A multiple infection of up to 5 PVs occasionally occurred within a single ovocyte (Fig. 1F). PVs typically distorted the egg nuclear membrane or cell membrane and sometimes both (Fig. 1C). Infection was accompanied by an intense hemocyte infiltration response throughout the entire gonad (Fig. 1F). Putative spores were gram negative.

Discussion. The parasite was similar to *Steinhausia* spp. (Sprague et al. 1972) because it appears as a 'cyst' containing many small spore-like unicells inside bivalve mollusc ova. Other protozoan parasites are known to infect bivalve ova (see Wolf 1977, Comps et al. 1986) but these bear no resemblance to the parasite

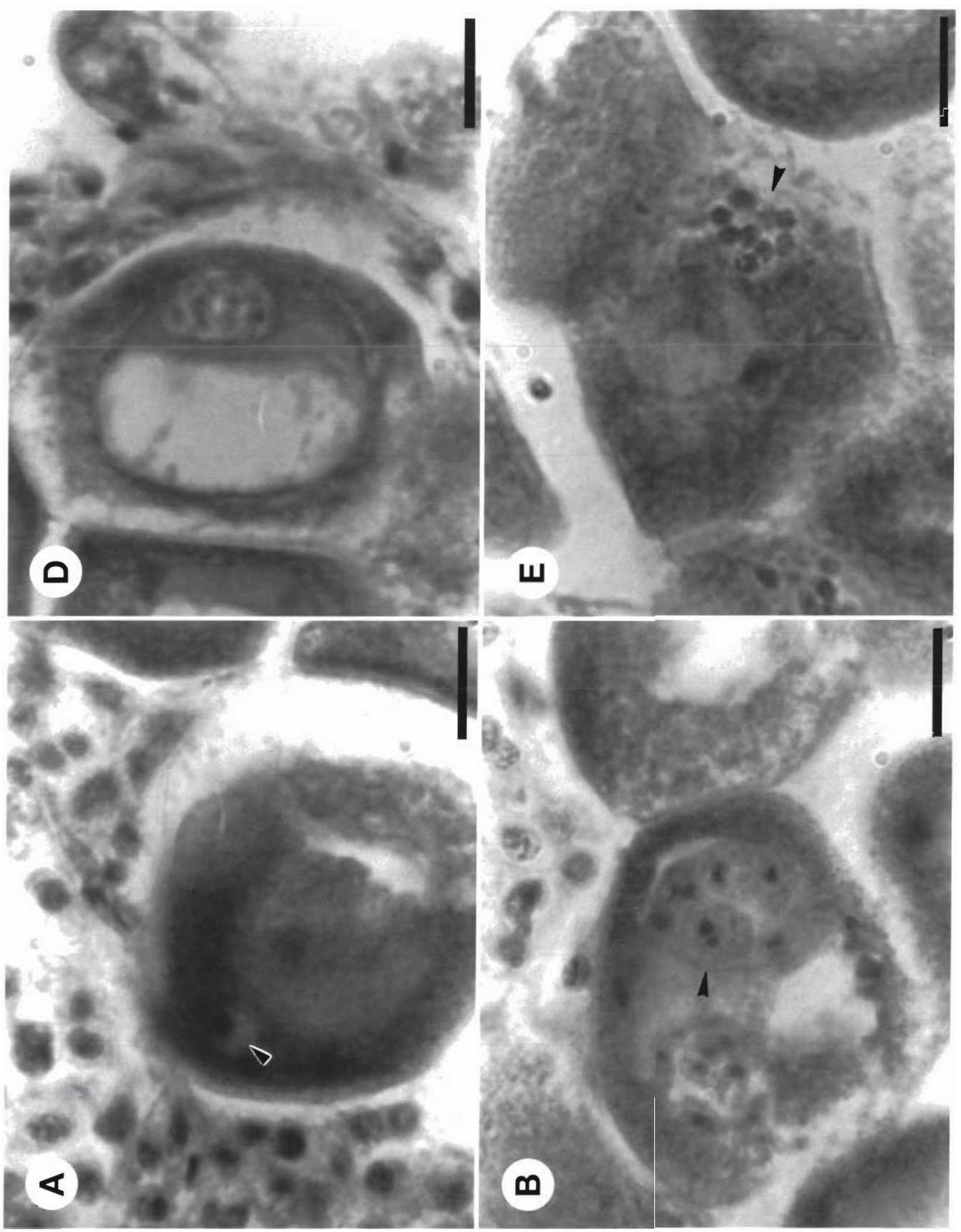
A
B
D
E

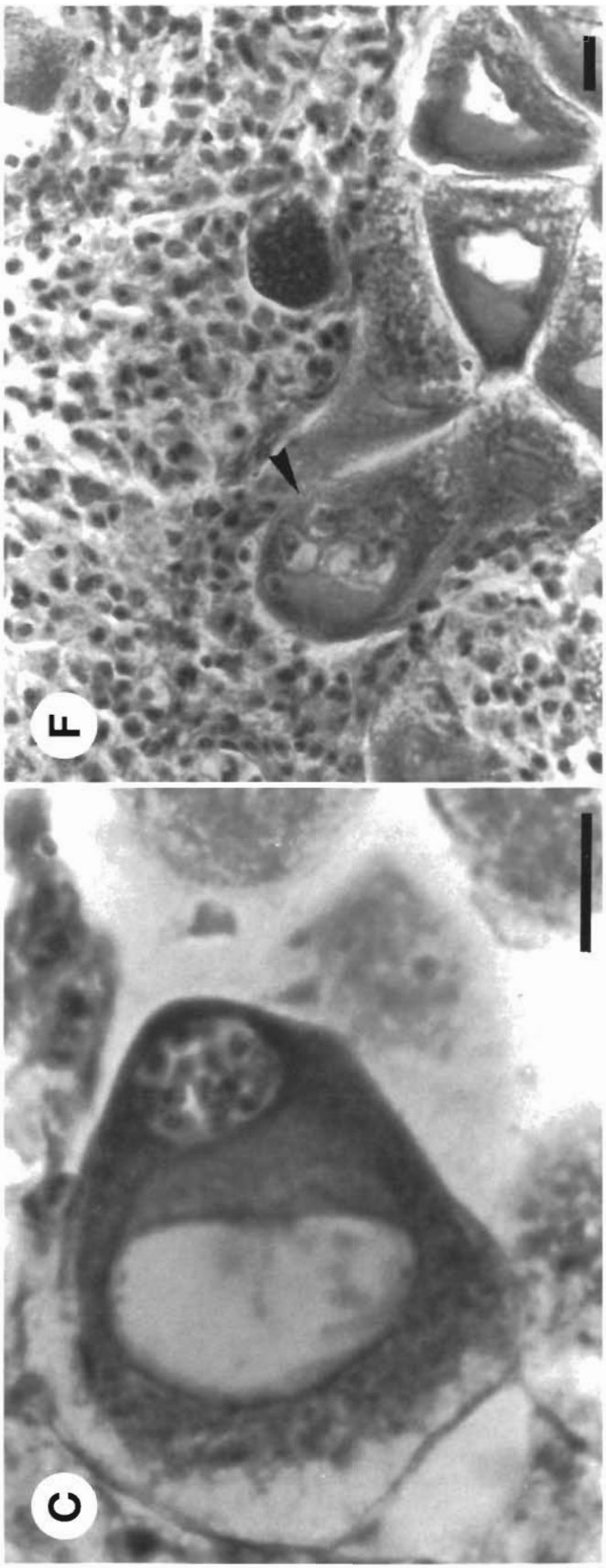

Fig. 1. *Saccostrea commercialis*. Light micrographs of paraffin sections stained with haematoxylin and eosin. *Steinhausia*-like parasite in ovocytes. Scale bars = 10 µm. (A) Earliest observed stage (small uninucleate cell) in cytoplasm of ovocytes (indicated by arrowhead). (B) Parasitophorous vacuole (PV) containing several large cells with 2 nuclear regions (indicated by arrowhead). (C) PV in cytoplasm of ovocytes containing small cells. Distortion of host cell and nuclear membranes evident. (D) A similar PV in nucleus of ovocyte. (E) Intracytoplasmic PV containing small cells with up to 4 nuclear regions (indicated by arrowhead). (F) Ovocyte containing at least 5 PVs (indicated by arrowhead). Intense hemocyte response evident

reported here. Becker & Pauley (1968) reported an unidentified protistan in ova of *Crassostrea gigas* from Humboldt Bay, California, USA, which superficially resembled *Steinhausia*. López et al. (1994) noted a *Steinhausia*-like microsporan inside ovocytes of clams *Ruditapes decussatus* cultured in Spain. Electron microscopic examination of spores and observations of fresh material are needed to confirm the identity of the parasite in *S. commercialis* ova and to make comparisons with the 2 nominal species of *Steinhausia* in bivalve ova. Transmission electron microscopy has not yet been utilised for describing *Steinhausia*. Our attempts to determine the spore ultrastructure were unsuccessful because of the low intensity of infection. Sprague (1965) reported that most infected mussels contained few infected eggs and considerable searching was usually required to find *S. mytilovum*. Other features of *S. mytilovum* and *S. ovicola* that are similar to the protistan parasite reported here are: (1) all parasites were observed to be closely associated with the host-cell nucleus and caused conspicuous invaginations of the host-nuclear membrane; and (2) multiple infections within a single egg occurred infrequently.

The pathogenesis of *Steinhausia* spp. is unclear. A marked hemocyte response to infection occurs in *Saccostrea commercialis* and was reported by Figueras et al. (1991) for *Mytilus galloprovincialis*. According to Field (1923), the eggs of mussels parasitised by *Steinhausia mytilovum* are destroyed. The low intensity of *Steinhausia*-like infection in cultured *S. commercialis* would not significantly reduce host fecundity. However, as pointed out by Figueras et al. (1991) for *Steinhausia mytilovum* in *M. galloprovincialis*, should the intensity increase, the parasite may become a problem in shellfish aquaculture particularly in hatcheries since the parasite may be transmitted transovarially as well as by ingestion of spores.

Acknowledgements. This work forms part of the doctoral dissertation of the senior author. We are indebted to Dr Keith Warner, owner of Pumicestone Passage Oyster Company, for providing oysters and his generous assistance.

LITERATURE CITED

Comps M, Park MS, Desportes I (1986) Étude ultrastructurale de *Marteilioides chungmuensis* n. g., n. sp. parasites des ovocytes de l'huître *Crassostrea gigas* Th. Protistologica 25:279-285

Bancroft JD, Stevens A (1985) Theory and practice of histological techniques. Churchill Livingstone

Becker CD, Pauley GB (1968) An ovarian parasite (*Protista incertae sedis*) from the Pacific oyster, *Crassostrea gigas*. J Invertebr Path 12:425-437

Field IA (1923) Biology and economic value of the sea mussel *Mytilus edulis*. Bull Bur Fish, Wash 38:127-259

Figueras AJ, Jardón CF, Calda JR (1991) Diseases and parasites of rafted mussel (*Mytilus galloprovincialis* Lmk.): preliminary results. Aquaculture 99:17-33

Hillman RE (1991) *Steinhausia mytilovum* (Minisporida: Chitridiopsidae) in *Mytilus* sp. in California: a new geographic record. J Invertebr Path 57:144-145

Humason GL (1979) Animal tissue techniques, 4th edn. WH Freeman & Co, San Francisco

Jones JB (1981) A new microsporidium from the oyster *Ostrea edulis* in New Zealand. J Invertebr Path 38:67-70

Léger L, Hollande AC (1917) Sur un nouveau protiste à facies de *Chytridiopsis*, parasite des ovules de l'huitre. C r Séanc Soc Biol 80:61-64

López MC, Villalba A, Carballa MJ (1994) Evolution of pathologic conditions affecting clams, *Ruditapes decussatus*, from cultured beds of Ria de Arousa (Galicia, N.W. Spain). In: Proceedings of the 6th international colloquium on pathology in marine aquaculture, Montpellier, France

Sprague V (1965) Observations on *Chytridiopsis mytilovum* (Field), formerly *Haplosporidium mytilovum* Field (Microsporida?). J Protozool 12:385-389

Sprague V, Ormières R, Manier JF (1972) Creation of a new genus and a new family in the Microsporida. J Invertebr Path 20:228-231

Vincentiis MDE, Renzoni A (1963) Sulla presenza di uno sporozoo in ovociti di *Mytilus galloprovincialis* Lam. Archo zool ital 47:21-26

Wolf PH (1977) An unidentified protistan parasite in the ova of the blacklipped oyster, *Crassostrea echinata*, from northern Australia. J Invertebr Path 29:244-246

Responsible Subject Editor: A. K. Sparks, Seattle, Washington, USA

Manuscript first received: July 28, 1994
Revised version accepted: December 6, 1994