

Pathology associated with an aquareovirus in captive juvenile Atlantic halibut *Hippoglossus hippoglossus* and an experimental treatment strategy for a concurrent bacterial infection

R. Roland Cusack^{1,*}, David B. Groman², Anne-Margaret MacKinnon³,
Frederick S. B. Kibenge², Dorota Wadowska², Nick Brown⁴

¹Veterinary Pathology, Nova Scotia Department of Fisheries and Aquaculture, PO Box 550, Truro, Nova Scotia B2N 5E3, Canada

²Aquatic Diagnostic Services, Dept. of Pathology and Microbiology, Atlantic Veterinary College, Charlottetown, Prince Edward Island C1A 4P3, Canada

³Fish Health Unit, Dept. of Fisheries and Oceans, PO Box 5030, Moncton, New Brunswick E1C 9B6, Canada

⁴R & R Finfish Development Ltd., RR#1 Sandy Cove, Digby, Nova Scotia B0V 1E0, Canada

ABSTRACT: A large-scale mortality of larval and juvenile halibut *Hippoglossus hippoglossus* occurred at a semi-commercial halibut farm in Atlantic Canada. Investigation of the cause revealed aquareovirus particles in necrotic liver tissue of affected fish. Cytopathic effect on CHSE-214 cell lines occurred from all fish cultured for viruses, and the viral morphology of the particles in culture was consistent with that observed in necrotic host tissue. The virus was placed in the family of *Reoviridae*, genus *Aquareovirus* based on morphology and RT-PCR results. Multifocal hepatocellular necrosis was a consistent finding in all fish as well as acute necrosis of proximal renal tubules. Concurrent bacterial infections were present in some specimens. Fish experimentally treated with oxytetracycline or a combination of oxytetracycline and chloramine-T had a significantly lower mortality rate than untreated fish. Fish treated with chloramine-T alone had a significantly elevated mortality rate compared to controls. Despite supportive medical therapy, mortality levels in treated and untreated groups remained elevated, supporting the hypothesis that the primary pathogen was of viral origin. This is the first report of elevated mortalities in Atlantic halibut associated with an aquareovirus.

KEY WORDS: Aquareovirus · Atlantic halibut · Fish diseases · Oxytetracycline · Chloramine-T · Pathology · Fish treatments

Resale or republication not permitted without written consent of the publisher

INTRODUCTION

A combination of biologic and economic factors have led to an increased interest in the culture of several species of marine fishes. In eastern Canada the choice for development is halibut because of its high market value, abundance of suitable habitat for culture and the advanced stage of research already completed on

the techniques of culture. The major hurdle confronting mass commercialization of the halibut species has been the survival rate of the early life stages (Mangor-Jensen et al. 1998).

Two viruses have been associated with Atlantic halibut *Hippoglossus hippoglossus* mortalities held under culture conditions. A nodavirus-like virus was associated with severe encephalopathy and retinopathy in larval halibut in Norway (Grotmol et al. 1997b). A similar virus was detected in Atlantic salmon, but the histo-

*E-mail: cusackrr@gov.ns.ca

pathologic lesions were different and mainly associated with a cardiomyopathy (Grotmol et al. 1997a). Infectious pancreatic necrosis virus (IPNV) is a common pathogen of Atlantic salmon (Wolf 1988), and this virus has also been associated with mortalities of Atlantic halibut in Norway (Mortensen et al. 1990, Biering et al. 1994, Biering & Bergh 1996) and juvenile Atlantic halibut in Scotland (Rodger & Frerichs 1997). The histopathological lesions associated with IPNV infections of Atlantic halibut larvae varied distinctly from those of Atlantic salmon fry. The most characteristic lesion was focal liver necrosis in halibut (Biering et al. 1994) and no pancreatic lesions that typify IPNV infection of salmonids were seen (Ferguson 1989). Pancreatic acinar cell necrosis was described in halibut 'fry' infected with IPNV (Rodger & Frerichs 1997).

The objective of this investigation was to determine the cause of a mass mortality of Atlantic halibut cultured at a semi-commercial farm in Nova Scotia, Canada, and to determine, experimentally, the effectiveness of treatment strategies for concurrent bacterial infections.

MATERIALS AND METHODS

Rearing conditions and history. Halibut larvae, average weight of approximately 100 mg, were reared in 8000 l circular fiberglass tanks with flowing seawater (34 ppt). The larvae were fed enriched *Artemia* to appetite and algae were added to the tanks continuously to 'green' the water. The water temperature was between 9 and 12°C and dissolved oxygen was near 100% saturation. Prior to the onset of unusual mortality levels, it was noticed that some larvae had stopped feeding, indicated by the absence of *Artemia* in the transparent gut. Some larvae also had noticeably swollen intestines, which were either transparent or white in color. A few days after the cessation of feeding the mortality rate increased. Each tank of larvae was transferred to a weaning facility once approximately 50% of the population had metamorphosed and settled to the bottom of the tanks (around 800 degree days). After a few days of acclimation in the weaning tanks, either circular 1100 or 1800 l semi-square fiberglass tanks, the fry were weaned onto a dry diet over a 10 d period. Moribund and dead fish were removed from tanks daily and recorded in a daily log. Counts of fish into the weaning system and daily removal of dead fish allowed accurate records of mortality rate following transfer.

Necropsy procedure. Gross abnormal morphologic features were noted during external and internal examination. Skin tissue was observed for the presence of parasites with the aid of a dissecting microscope.

Tissues for other diagnostic tests were collected during the necropsy procedure. Five fish grossly typifying the moribund juveniles were examined on 2 separate occasions during the period of elevated mortalities.

Bacteriology. The small size of the fish (20 to 30 mm) precluded culture of individual organs. An aspirate of ascites fluid was collected aseptically using a tuberculin syringe. This fluid was streak-plated on tryptic soya agar and blood agar supplemented with 2% NaCl. Bacterial isolates were identified using standardized techniques and their antibiotic sensitivity patterns were determined. Aspirated ascites fluid was also placed on a slide, dried and stained with a differential stain. Ten fish were examined in this manner.

Virology. All visceral organs from individual fish were pooled in sterile plastic bags. Five individual fish were processed for virology on 2 separate occasions. Tissue pools were triturated, diluted to obtain a 2% tissue suspension in Hanks' balanced salt solution (pH 7.6) and homogenized using a stomacher (Seward Lab). The homogenates were centrifuged (Sorvall) at $2500 \times g$ for 15 min at 4°C and the supernatant was filtered aseptically through a 0.45 µm pore diameter membrane filter. Each filtrate (0.1 ml) was added in duplicate to 24-well plates containing chinook salmon embryo (CHSE), salmonid head kidney (SHK), epithelioma papillosum cyprini (EPC) and guppy fintail (GFT) cell lines, using the simultaneously applied cells and test sample method, as described in the Fish Health Protection Regulations (FHPR) *Manual of Compliance* (Anonymous 1984). Plates were incubated at 15°C and examined for cytopathic effect (CPE). All wells showing CPE were subcultured by filtering cell lysates using a 0.45 µm pore diameter filter and inoculating 0.1 ml of each cell lysate onto fresh cultures of the same cell line in which CPE was observed.

Reverse transcriptase-polymerase chain reaction (RT-PCR) for aquareovirus. The PCR primers were designed using Primer Detective, Version 1.01 (Clontech Laboratories Inc.), from nucleotide sequence of a cDNA clone of an aquareovirus (strain RPC-S) (F.S.B.K. unpubl. data) previously isolated from Atlantic salmon. The primer pair would yield a PCR product of 590 bp. This product was cleaved with the restriction enzyme *HhaI* to yield products of 207 and 383 bp. Total RNA for use in RT-PCR was isolated from 300 µl of virus-infected CHSE cell lysate using the TRIZOL Reagent (GIBCO BRL). Briefly, 1 ml of TRIZOL Reagent was added to 300 µl of cell lysate of each sample in a diethylpyrocarbonate (DEPC)-treated microfuge tube and incubated at room temperature for 5 min. Two hundred microliters of chloroform were added and after vigorous mixing followed by a further incubation of 3 min, the sample was spun in a microfuge at 12000 rpm ($12000 \times g$) for 15 min. The RNA was precipitated with

isopropanol in the presence of 20 µg glycogen (Boehringer Mannheim) at room temperature for 10 min and was pelleted in a microfuge for 10 min. Isolated RNA was stored in 75% ethanol at -80°C for at least 2 h before use. The RNA was then pelleted, dried briefly, and redissolved in 10 µl of sterile RNase-free water. It was then heated to 100°C for 2 min to denature the aquareovirus double stranded (ds)RNA. Samples were quick-chilled on ice prior to use in RT-PCR. One-step RT-PCR was carried out using the Titan™ One Tube RT-PCR System kit (Boehringer Mannheim). Each reaction contained 0.2 mM dNTP, 0.4 µM sense primer, 0.4 µM antisense primer, 2 µl of template RNA, 5 mM DTT, 10 U RNase Inhibitor, RT-PCR buffer with 2.0 mM MgCl₂, and 1 µl enzyme mix (reverse transcriptase, AMV, and Expand™ High Fidelity enzyme mix; Boehringer Mannheim). The RT-PCR was performed in a Peltier Thermal Cycler PTC-200 DNA Engine (MJ Research, Inc. Watertown, Massachusetts, USA). Cycling conditions consisted of 1 cycle of cDNA synthesis and pre-denaturation at 55°C for 30 min and 94°C for 2 min, followed by 40 cycles each consisting of denaturation at 94°C for 15 s, annealing at 65°C for 30 s, and extension at 72°C for 1 min, with a final extension at 72°C for 10 min. PCR products were separated by electrophoresis on a 1% agarose gel and stained with ethidium bromide.

Histopathology. Five moribund juveniles were euthanized by an overdose of tricaine methane sulphonate (MS-222), incised along the ventral midline to expose the visceral organs and heart, and fixed whole in 10% neutral buffered formalin. Fixed specimens were decalcified in a commercially available formic acid solution (Cal-EX II, Fisher), trimmed into cassettes, then dehydrated in ethanol and cleared in xylene and embedded in paraffin wax. Sagittal sections were cut to 5 µm and stained with haematoxylin and eosin, Brown and Bren, and Giemsa stains (Luna 1992).

Electron microscopy. Field samples—transmission electron microscopy (TEM): Moribund fish were euthanized by an overdose of MS-222. Fresh visceral organs were dissected from the fish, cut into 1 mm cubes and placed in a 2% solution of glutaraldehyde/formaldehyde buffered with PBS for 2 h. After a series of washings, samples were postfixed in 1% osmium tetroxide for 1 h. Fixation took place at room temperature and fixatives were buffered in 0.1 M sodium phosphate, pH 7.2. Fixation was followed by dehydration in ascending concentrations of ethanol followed by propylene oxide. Samples were infiltrated with the mixture of propylene oxide and resin and left overnight in 100% resin. The next day pieces of tissue were embedded in 100% Epon/Araldite. Blocks were cured overnight at 70°C. Sections were cut using an ultramicrotome (Reichert-Jung Ultracut E). Semi-thin sections

were stained with toluidine blue and observed with the aid of a light microscope. Ultra-thin sections were transferred onto 200 mesh copper super grids and stained with 5% uranyl acetate in 50% ethanol followed by Sato lead stain. Sections were viewed on a Hitachi 600 TEM at 75 kV.

Cell culture—TEM: Inoculated CHSE cells were harvested when cytopathic effect reached 60 to 70% of the monolayer area. Culture medium was collected and cells were scraped from the bottom of the wells with a plastic Pasteur pipette. Both culture medium and cells were pelleted at 3000 rpm (500 × g) for 10 min (Beckman Microfuge 12) using fixed angle rotor. Pellets were fixed in 3% glutaraldehyde in 0.1 M sodium phosphate buffer for 1 h at room temperature, washed in phosphate buffer, centrifuged and then postfixed in 1% osmium tetroxide for 0.5 h at room temperature. After osmification and final centrifugation pellets were embedded in 4% agar and further processed the same way as field samples.

Cell culture—negative staining: A drop of culture medium from field inoculum was placed on a formvar and carbon coated 400 mesh copper grid. A drop of 1% phosphotungstic acid with 0.1% BSA was placed over it. After 1 min the grid was blotted and examined using a Hitachi 600 TEM at 75 kV.

Treatment of Atlantic halibut for secondary bacterial infections. A low level bacterial branchitis and systemic vibriosis was diagnosed during the course of the investigation. To address this problem, we experimented with treatment strategies in replicate groups of affected fish.

A total of 490 juvenile halibut were distributed amongst 8 fiberglass fish tanks. There were between 58 and 67 fish per tank. Each tank had flowing ambient seawater at 10°C. Treatment 'A' consisted of a 1 h static bath of chloramine-T at a concentration of 10 ppm, repeated daily for 5 d. Treatment 'B' consisted of a chloramine-T bath as described above, plus oxytetracycline at a rate of 100 mg active ingredient kg⁻¹ of fish. Medicated feed was fed for 10 consecutive days. Treatment 'C' consisted of fish fed medicated feed for 10 consecutive days. Treatment 'D' was untreated controls. Each group was fed at a rate of 1% of their body weight d⁻¹ with either medicated or non-medicated feed. Moribund and dead fish were removed daily from the tanks. Incidence of mortality between treatments was compared by a G-test based on the intrinsic null hypothesis (α=2 degrees of freedom) that treatment had no significant effect on mortality (Sokal & Rohlf 1981, p. 691–768). Where the null hypothesis was rejected, pair-wise comparisons were made by calculating the 95% confidence intervals for each frequency by use of the Bonferonni Z-statistic (Neu et al. 1974).

RESULTS

Case history and necropsy

Mortalities were first noted in the live feeding stage at the end of June and continued through the weaning stage to a size of around 1 g. Fig. 1 shows the mortality rate from the beginning of the weaning phase calculated from the hatchery records. There was a sudden increase in mortalities beginning on 20 August 1998. The mortality rate remained high for 2 mo, returning to normal in October. A peak in mortality occurred from 31 August to 20 September 1998 and began to decline from that point forward. The total accumulated mortality equaled 58% of the population.

Affected fish tended to be smaller members of the cohort. The only behavioral sign associated with the disease was lethargy. Some fish appeared darker in color. Abdominal distension was visible in 80% of affected fish. The abdomen was filled with a clear non-viscous ascites fluid, which upon microscopic examination was shown to contain low numbers of erythrocytes, macrophages and lymphocytes. Heart, kidney and liver were pale in 80% of fish. Twenty percent of fish had enlarged edematous large intestines. No feed was present in the gastrointestinal tracts and gall bladders were filled with bile. No fungi or parasites were associated with the skin of affected fish.

Histopathology

Sagittal sections through the whole body of all 5 specimens revealed severe, multifocal regions of

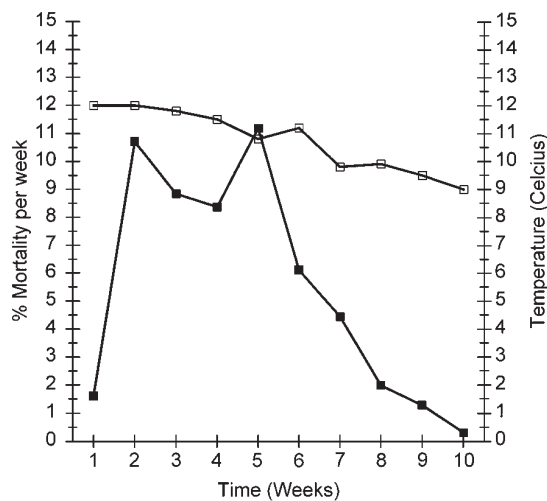


Fig. 1. *Hippoglossus hippoglossus*. Percent mortality per week of Atlantic halibut between August and October (Weeks 1 to 10 on the x-axis). (■) Percent mortality per week, (□) water temperature

hepato-cellular necrosis, characterized by areas of syncytial formation (Fig. 2) and acute necrosis of proximal renal tubules (Fig. 3). Necrotic regions of liver and kidney showed no significant inflammatory infiltrate. The lumen of the digestive tract and oral cavity contained food material that was heavily colonized by a mixed bacterial rod population. The bacterial matt extended on to the gill surface. The morphologic diagnosis was necrotizing hepatopathy and nephropathy, acute to subacute, multifocal to coalescing, severe, with bacterial overgrowth of the gill, oral cavity and intestinal lumen. The hepatic and renal lesions were indicative of either a viral or nutritional etiology.

Bacteriology

Bacteria were isolated from 2 of 10 fish. These bacteria were Gram-negative motile curved rods classified biochemically as a species of *Vibrio* (oxidase, catalase, gelatinase, urease, oxidative/fermentative, hydrolysis of orthonitrophenol by beta-galactosidase (ONPG)-positive; vibriostatic agent 0129-sensitive; triple sugar iron <acid/acid>; sulfide, indole-negative). The isolate was antibiotic sensitive to oxolinic acid, florfenicol, oxytetracycline, sulphamethoxazole trimethoprim and resistant to sulfadiazine and sulphamethazole.

Virology

Within 48 h of incubation, discrete areas of the CHSE monolayer showed regions of CPE characterized by formation of syncytia (Fig. 4), which subsequently lifted off the bottom of the plate and rolled into clumps in all sample wells. Similar CPE was again detected for all samples following subculture of all positive wells. The same CPE was also observed following culture of 1 in 10 and 1 in 1000 dilutions of 2 representative cell lysates obtained from the subculture. No CPE was observed on SHK, EPC and GFT cell lines after 21 d incubation at 15°C. Viral particles were isolated from all 10 fish tested.

Electron microscopy

Field samples

Liver tissue contained large numbers of viral arrays (Fig. 5). The viruses were located in the cytoplasm of hepatocytes. They were spherically shaped, 70 nm in size and were non-enveloped with an inner and outer capsid (Fig. 6), morphologically consistent with reovirus (Cheville 1994).

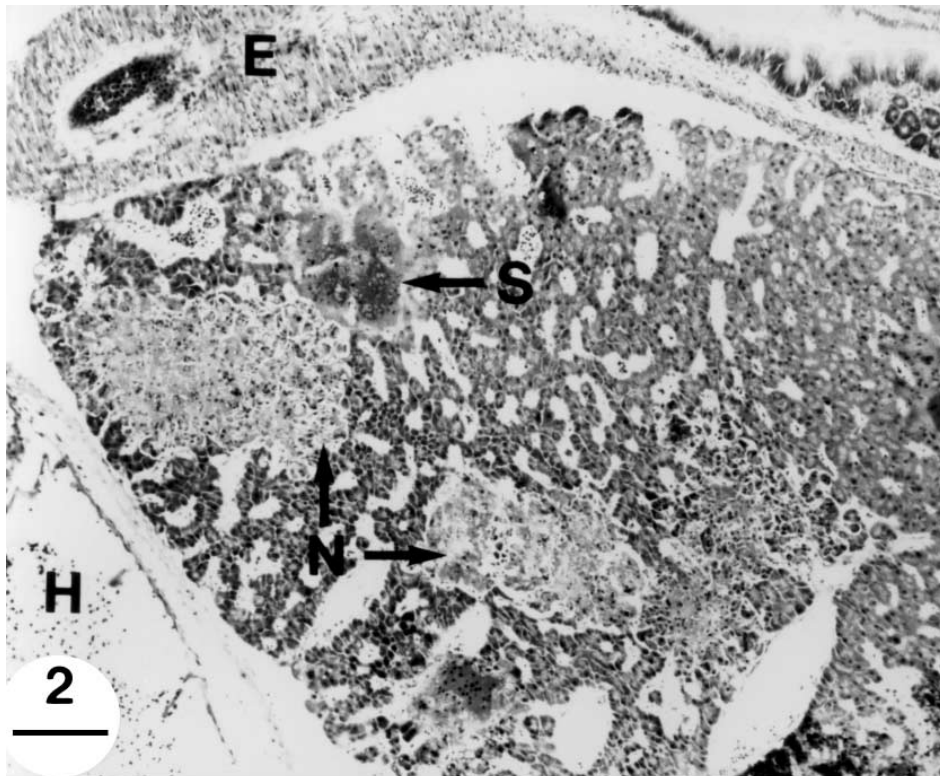


Fig. 2. *Hippoglossus hippoglossus*. Sagittal section of anterior mid-body through liver. N = foci of coagulative necrosis; S = foci of hepatocellular syncytial formation; E = esophagus; H = heart. Scale bar = 113 μ m

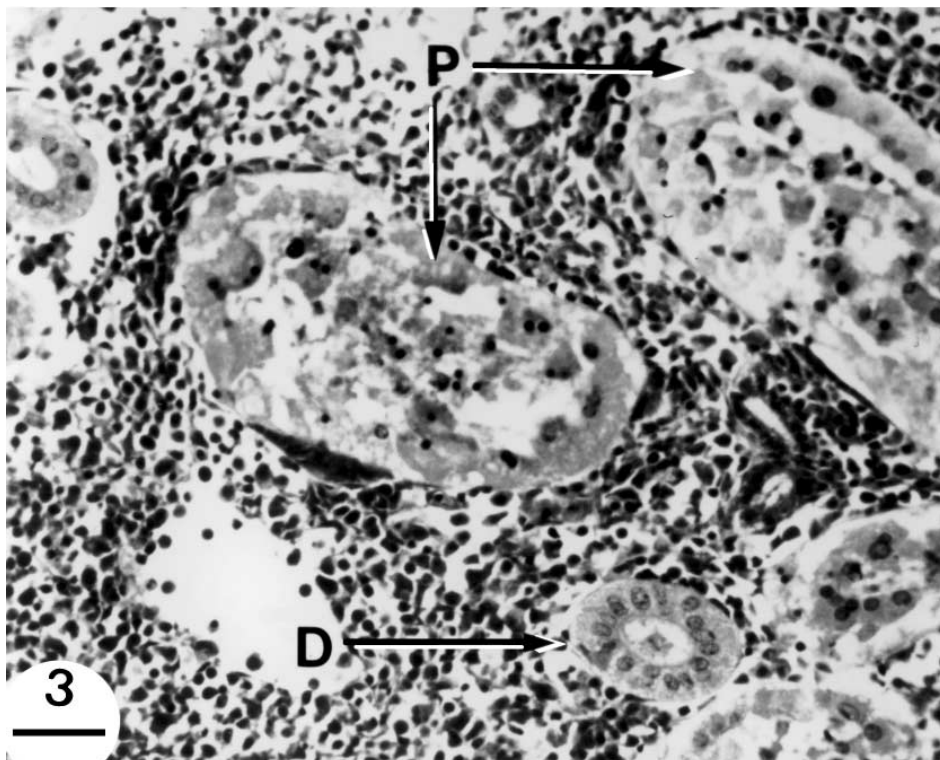


Fig. 3. *Hippoglossus hippoglossus*. Sagittal section of anterior mid-body through kidney. P = necrotic proximal tubular epithelium; D = normal distal tubular epithelium. Scale bar = 28 μ m

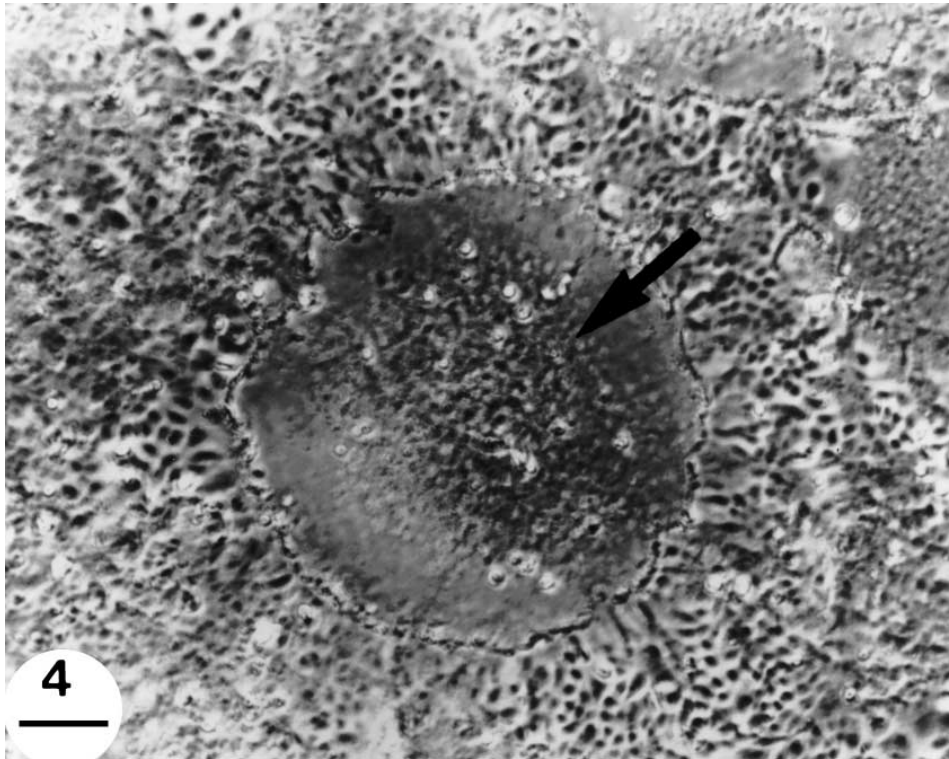


Fig. 4. *Hippoglossus hippoglossus*. Phase contrast micrograph of CHSE-infected monolayer showing CPE. Arrow = syncytium. Scale bar = 113 μ m

Cell cultures

Virus-infected tissue cultures contained non-arrayed viral particles of the size and morphology seen in the field samples (Fig. 7). Supplemental negative staining (Fig. 8) better revealed the bi-capsid morphology of the virus typical of aquareovirus (Palmer & Martin 1988, Holmes et al. 1995).

Analysis of RT-PCR reaction products

Aquareovirus strain RPC-S was used as the known positive control in RT-PCR. A PCR product 590 bp long was amplified from both RPC-S and the halibut virus isolate and visualized by ethidium bromide staining after agarose gel electrophoresis. Restriction digestion of the PCR product with *Hha*I yielded the 2 expected fragments 207 and 383 bp long for RPC-S, confirming that the amplification was specific and the virus was an aquareovirus. The restriction digest of the PCR product from the halibut virus isolate yielded a different pattern compared to that obtained with RPC-S, indicating that the 2 aqua-

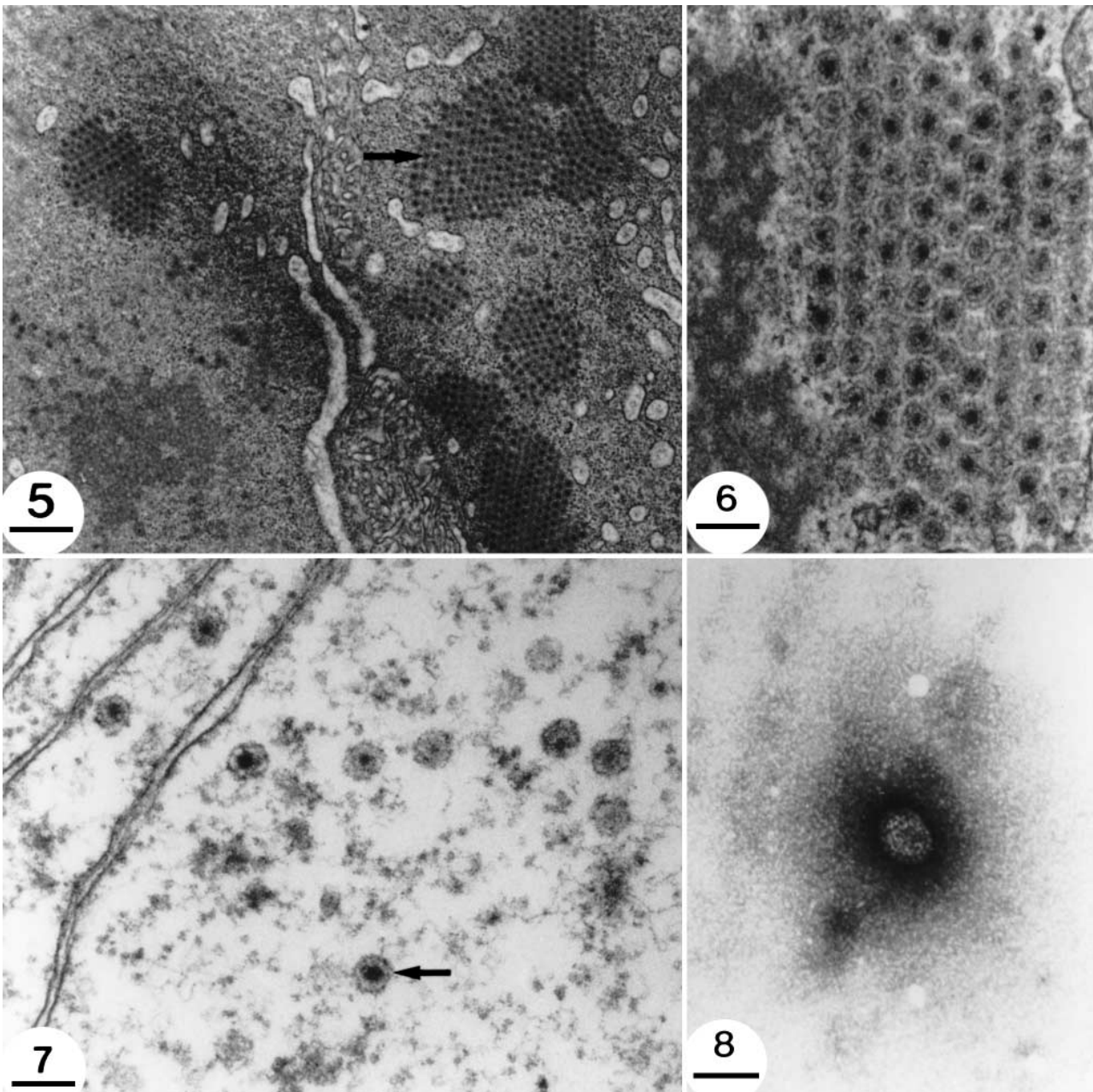
reoviruses can be easily differentiated on the basis of this test (Fig. 9). RNA templates from IPNV and from uninoculated CHSE cell culture which were used as negative controls gave no visible PCR product.

Effect of treatments on the mortality rate

Mortality rate was significantly affected by treatments (Table 1). The mortality rate of untreated controls was 24.1% during the experiment, which was significantly higher than fish treated with oxytetracycline (14.0%) or a combination of oxytetracycline and chloramine-T (15.2%). Chloramine-T treatments alone significantly elevated the mortality rate to 36.1%.

Table 1. Effect of treatments on the mortality rate of juvenile Atlantic halibut (pooled replicate groups)

	Treatment A Chloramine-T	Treatment B Oxytetracycline/ chloramine-T	Treatment C Oxytetra- cycline	Treatment D Control
No. of fish	119	118	121	132
Mortalities	43	18	17	32
% mortalities	36.1	15.2	14.0	24.2



Figs. 5 to 8. *Hippoglossus hippoglossus*. Fig. 5. Transmission electron micrograph of hepatocyte cytoplasm with viral arrays (arrow). Scale bar = 625 nm. Fig. 6. Transmission electron micrograph of viral array as noted in Fig. 5, but at higher magnification. Scale bar = 131 nm. Fig. 7. Transmission electron micrograph of CHSE tissue culture monolayer infected with aquareovirus (arrow). Scale bar = 130 nm. Fig. 8. Transmission electron micrograph of a negatively stained viral particle from concentrated supernatant of an aquareovirus-infected CHSE monolayer. Scale bar = 84 nm

DISCUSSION

We report here a third virus type associated with mortalities of cultured Atlantic halibut. The morphologic features place this virus amongst the *Reoviridae* family. The virion is 70 nm in diameter, nonenveloped and

has an inner and outer capsid. Aquareoviruses physically resemble orthoreoviruses but possess 11 dsRNA segments (Holmes et al. 1995). Among the different members of aquareovirus, 5 genogroups are recognized on the basis of whole viral RNA-RNA hybridization (Lupiani et al. 1993). The fact that the RT-PCR

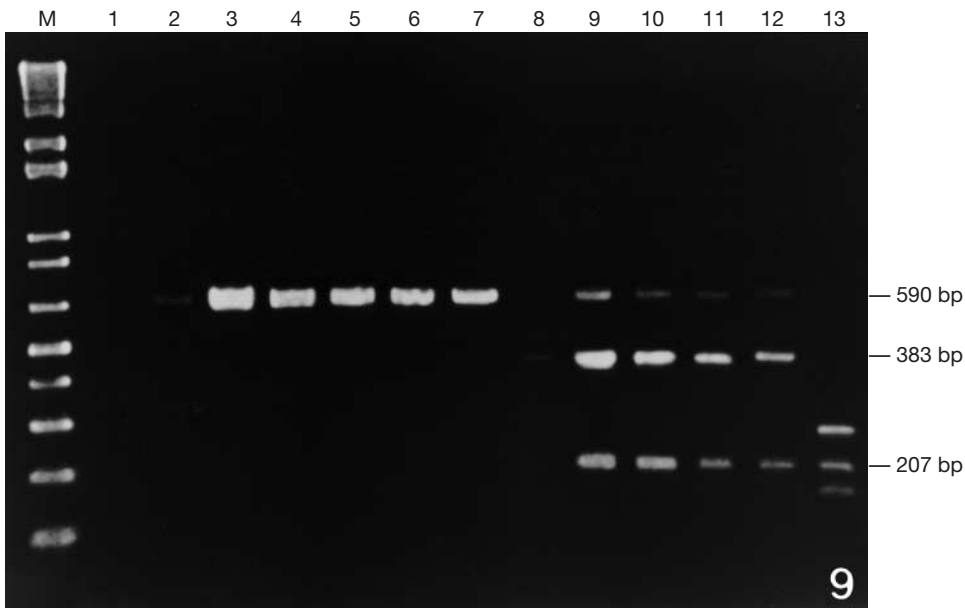


Fig. 9. Ethidium bromide-stained agarose gel electrophoresis separation of PCR products following restriction digestion with *HhaI*. Lanes: 1 = RPC-3; 2 = RPC-1; 3 = RPC-2; 4 = RPC-Z; 5 = RPC-S; 6 = RPC-S; 7 = halibut; 8–13 = RPC-1, 2, Z, S, S and halibut cut with *HhaI*, respectively. RPC = Research Productivity Council—source of RPC isolates. RPC-1, RPC-2, RPC-3, RPC-S and RPC-Z = various aquareovirus isolates from Atlantic salmon. Lane M = 1 kb DNA ladder (Gibco)

primers designed from aquareovirus strain RPC-S, which was originally isolated from Atlantic salmon broodstock, could detect the halibut aquareovirus isolate suggests that the 2 viruses belong to the same genogroup. The halibut aquareovirus isolate, however, can be easily distinguished from the Atlantic salmon aquareovirus by restriction fragment length polymorphism (RFLP).

Reoviruses cause significant diseases of animals including African horse sickness, bluetongue of ruminants and equine encephalosis (Fenner et al. 1987). Aquareoviruses have been isolated from various fish including: golden shiner (Plumb et al. 1979), catfish (Amend et al. 1984), grass carp (Chen & Jiang 1984), chum salmon (Winton et al. 1981), 13P₂ reovirus of blue gill and rainbow trout (Meyers 1980, 1983), tench (Ahne & Kolbl 1987), chub (Ahne & Kolbl 1987), golden ide (Neukirch et al. 1999), turbot (Lupiani 1989) and landlocked salmon (Hsu et al. 1999).

The golden shiner and chum salmon reoviruses were demonstrated to be of low pathogenicity (Plumb et al. 1979, Winton et al. 1981). The channel catfish reovirus was associated with low chronic mortalities from a Californian facility but experimental support of the virus' pathogenicity is lacking (Amend et al. 1984). American oysters were the original source of the 13P₂ virus (Meyers 1979), but it was transferred to rainbow trout and blue gill and caused significant mortality (Meyers 1980, 1983). The pathogenicity of the reoviral infections of tench and chub remains unclear. Grass carp reovirus infections appear to be highly pathogenic (Chen & Jiang 1984). A mortality rate of 4% was reported from cultured turbot co-infected with an aquareovirus and mixed bacteria (Lupiana 1989). In

the case of the halibut aquareovirus reported here, experimental infections are required to establish its potential pathogenicity.

The most outstanding pathology associated with infected Atlantic halibut was severe multifocal liver necrosis. Experimental infections of blue gill with the 13P₂ virus produced similar liver pathology (Meyers 1980). Electron microscopy of infected blue gill revealed intracytoplasmic viral arrays in hepatocytes and phagosomes. The viral arrays and particle morphology were similar to those found in the cytoplasm of infected halibut hepatocytes. Viral particles were not detected in halibut phagosomes. Focal hepatic necrosis was also the key pathologic feature of chum salmon experimentally infected with the chum salmon reovirus. In chum salmon, the necrosis was detected from 8 to 21 d post infection but the lesions resolved thereafter.

The pathogenesis of the current infection is unknown. The mortalities likely resulted from a combination of factors. On 2 occasions *Vibrio* sp. was isolated from 1 of 5 moribund specimens. Further complicating the pathogenesis was the presence of bacteria associated with gill lamellae of some fish. It is noteworthy, however, that all moribund fish had severe liver pathology.

Species of *Vibrio* are known pathogens of cultured marine finfishes (Sinderman 1990) and likely contributed to the halibut mortalities. The presence of the bacteria on the gills is equivocal since there was no associated host response. The colonization may have followed the fish's moribund state when animals tended to be slow moving and gathered in areas where excess feed and fecal material accumulated. The manager suspected poor nutrition as a possible contributor to the mortalities but there were no pathologic changes to

support this hypothesis and there was no seeming effect related to a change in diet. The consistent finding in all moribund fish examined was liver pathology with associated viral particles amongst the necrotic debris.

A test of possible supportive therapy was initiated following the discovery of bacteria associated with the gills and the presence of a low grade infection of *Vibrio* sp. The chloramine-T treatment significantly increased the mortality rate relative to controls. The chloramine-T treatment was carried out for 5 consecutive days instead of the prescribed 3 d treatment. Under these experimental conditions, chloramine-T negatively influenced host survival rate by 40%. A combination of chloramine-T and systemic antibiotic treatment improved the survival rate by 37%. The difference in the mortality rate between systemic antibiotic and the combination treatment was not significant.

The culture of *Vibrio* sp. was sensitive to oxytetracycline. If fish had a primary or secondary bacterial infection, it seems likely the supportive therapy was effective in controlling this problem. Since no bacteria were isolated from the gill, it is difficult to surmise what the effect of the systemic antibiotic treatment had on the gill infection. The general mortality rate was significantly improved by the supportive treatment but the mortality continued at a rate well above what would be acceptable to commercial producers (i.e. 14% mortality over 12 d). One could hypothesize that many fish continued to die as a result of a primary viral hepatopathy. This diagnosis is supported by the severe liver pathology from moribund fish in the experimental groups.

The source of this viral infection is unknown. The fry were hatched on site and not collected from the wild. One possible source of infection could be vertical transmission from the broodstock. All broodstock originated from wild sources and were not screened for viral pathogens. The systems water source was untreated seawater which could bring in viral particles. Experimental infections have demonstrated possible transfer of reoviruses from shellfish to finfish (Meyers 1983), and thus non finfish species may be considered as possible sources.

The water treatment equipment at the hatchery has since been upgraded to include UV sterilization and microfiltration to 1 µm for all life stages. There have been no incidences of elevated mortality since the case reported in this communication in either the affected population or subsequent cohorts.

Acknowledgements. We thank Dr J. Duston for his assistance in statistical analyses, Mr C. Huntington and Ms L. Boston for technical assistance and Ms J. Flemming for assistance in the manuscript preparation. The research was partially funded by NSERC grant number 224165.

LITERATURE CITED

- Ahne W, Kolbl O (1987) Occurrence of reoviruses in European cyprinid fishes (*Tinca tinca* Lin, *Leuciscus cephalus* Lin.). *J Appl Ichthyl* 3:139–141
- Amend DF, McDowell T (1984) Characteristics of a previously unidentified virus from channel catfish (*Ictalurus punctatus*). *J Fish Aquat Sci* 41:807–811
- Anonymous (1984) Fish health protection regulations: manual of compliance. *Fish Mar Serv Misc Spec Publ* 31(revised): 1–32
- Biering E, Bergh O (1996) Experimental infection of Atlantic halibut, *Hippoglossus hippoglossus* L., yolk sac larvae with infectious pancreatic necrosis virus: detection of virus by immunohistochemistry and in situ hybridization. *J Fish Dis* 19:405–413
- Biering E, Nilsen F, Rodseth OM, Glette J (1994) Susceptibility of Atlantic halibut *Hippoglossus hippoglossus* to infectious pancreatic necrosis virus. *Dis Aquat Org* 20:183–190
- Chen Y, Jiang Y (1984) Morphological and physio-chemical characterization of the hemorrhagic virus of grass carp. *Kexue Tongbao* 29:832–835
- Chevillie NF (1994) Cytopathology of viral disease. In: Ultrastructural pathology—an introduction to interpretation, Chap 11. Iowa State University Press, Ames, IA, p 549–551
- Fenner F, Bachmann PA, Gibbs EPJ, Murphy FA, Studdert MJ, White DO (1987) *Veterinary virology*. Academic Press, Orlando, FL
- Ferguson HW (1989) Gastrointestinal tract, pancreas, and swimbladder. In: Systemic pathology of fish. Iowa State University Press, Ames, IA, p 125–145
- Grotmol S, Totland GK, Kryvi H (1997a) Detection of a nodavirus-like agent in heart tissue from reared Atlantic salmon *Salmo salar* suffering from cardiac myopathy syndrome (CMS). *Dis Aquat Org* 29:79–84
- Grotmol S, Totland GK, Thorud K, Hjeltne BK (1997b) Vacuolating encephalopathy and retinopathy associated with a nodavirus-like agent: a probable cause of a mass mortality of cultured larval and juvenile Atlantic halibut *Hippoglossus hippoglossus*. *Dis Aquat Org* 29:85–97
- Holmes IH, Boccardo G, Estes MK, Furuichi MK, Hoshino Y, Joklik WK, McCrae M, Mertens PPC, Milne RG, Samal KSK, Shikata E, Winton JR, Uyeda I, Nuss DL (1995) Family *Reoviridae*. In: Murphy FA, Fauquet CM, Bishop DHL, Ghabrial SA, Jarvis AW, Martelli GP, Mayo MA, Summers MD (eds) *Virus taxonomy*. Sixth Report of the International Committee on Taxonomy of Viruses. *Archives of virology* (Suppl 10), Springer-Verlag, Wien, p 208–239
- Hsu YL, Chen BS, Wu JL (1999) Characteristics of a new reo-like virus isolated from lanlocked salmon (*Oncorhynchus masou* Brevoort). *Fish Pathol* 24(1):37–45
- Luna LG (1992) *Histopathologic methods and color atlas of special stains and tissue artifacts*. American Histolabs Inc. Publishers Division, Gaithersburg, MD, p 767
- Lupiani B, Dopazo CP, Ledo A, Fouz B, Barja JL (1989) New syndrome of mixed bacterial and viral etiology in cultured turbot *Scophthalmus maximus*. *J Aquat Anim Health* 1: 197–204
- Lupiani B, Hetrick FM, Samal SK (1993) Genetic analysis of aquareoviruses using RNA-RNA blot hybridization. *Virology* 197:475–479
- Mangor-Jensen A, Harboe T, Shields RJ, Gara B, Naas KE (1998) Atlantic halibut, *Hippoglossus hippoglossus* L., larvae cultivation literature, including a bibliography. *Aquat Res* 29:857–886
- Meyers TR (1979) A reo-like virus isolated from juvenile

- American oysters (*Crassostrea virginica*). J Gen Virol 43: 203–212
- Meyers TR (1980) Experimental pathogenicity of reovirus 13P₂ for juvenile American oysters *Crassostrea virginica* (Gmelin) and blue gill fingerlings *Lepomis macrochirus* (Rafinesque). J Fish Dis 3:187–201
- Meyers TR (1983) Serological and histopathological responses of rainbow trout, *Salmo gairdneri* Richardson, to experimental infection with the 13P₂ reovirus. J Fish Dis 6: 277–292
- Mortensen SH, Hjeltnes B, Krogsrud J, Christie KE (1990) Infectious pancreatic necrosis virus, serotype N1, isolated from Norwegian halibut (*Hippoglossus hippoglossus*), turbot (*Scophthalmus maximus*) and scallops (*Pecten maximus*). Bull Eur Assoc Fish Pathol 10(2):42–43
- Neu CW, Byers CR, Peek JM (1974) A technique for analysis of utilization-availability data. J Wildl Manag 38(3):541–545
- Neukrich M, Haas L, Lehmann H, von Messeling V (1999) Preliminary characterization of a reovirus isolated from golden ide *Leuciscus idus melanotus*. Dis Aquat Org 35: 159–164
- Palmer EL, Martin MC (1988) Electron microscopy in viral diagnosis. CRC Press Inc, Boca Raton, FL, p 194
- Plumb JA, Bowser PR, Grizzle JM, Mitchell AJ (1979) Fish viruses: a double stranded RNA icosahedral virus from a North American cyprinid. J Fish Res Board Can 36: 1390–1394
- Rodger HD, Frerichs GN (1997) Clinical infectious pancreatic necrosis virus infection in farmed halibut in the United Kingdom. Vet Rec 140:401–402
- Sinderman CJ (1990) Disease and parasite problems in marine fish culture, Vol 1. Principal diseases of marine fish and shellfish, 2nd edn. Academic Press, New York, p 293–294
- Sokal RR, Rohlf FJ (1981) Biometry. WH Freeman and Co, San Francisco, CA
- Winton JR, Lannan CN, Fryer JL, Kimura T (1981) Isolation of a new reovirus from chum salmon in Japan. Fish Pathol 15: 155–162
- Wolf K (1988) Infectious pancreatic necrosis. In: Fish viruses and fish viral diseases. Cornell University Press, Ithaca, NY, p 115–157

Editorial responsibility: Jo-Ann Leong,
Corvallis, Oregon, USA

Submitted: March 1, 2000; Accepted: September 20, 2000
Proofs received from author(s): December 15, 2000