

Accumulation and clearance of orally administered erythromycin and its derivative, azithromycin, in juvenile fall Chinook salmon *Oncorhynchus tshawytscha*

William T. Fairgrieve^{1,*}, Cyndy L. Masada², W. Carlin McAuley², Mark E. Peterson², Mark S. Myers², Mark S. Strom²

¹Pacific States Marine Fisheries Commission, 205 South East Spokane Street Suite 100, Portland, Oregon 97202, USA

²Northwest Fisheries Science Center, NOAA Fisheries, 2725 Montlake Boulevard East, Seattle, Washington 98112, USA

ABSTRACT: Fall Chinook salmon *Oncorhynchus tshawytscha* were fed practical diets medicated with azithromycin (30 mg kg⁻¹ fish for 14 d) or erythromycin (100 mg kg⁻¹ fish for 28 d) either 1, 2, or 3 times beginning 14 d after initiation of exogenous feeding (February) and ending at smoltification (June). Average tissue concentrations of azithromycin increased from 19.0 µg g⁻¹ in fry to 44.9 µg g⁻¹ in smolts, and persisted in the tissues >76 d after treatment ceased. Tissue concentrations of erythromycin were comparatively low, ranging from 0.2 µg g⁻¹ in fry to 10.4 µg g⁻¹ in smolts. Erythromycin was not detectable 21 d post-treatment. Neither antibiotic caused histopathologically significant lesions in the trunk kidney or other organ tissues. The high tissue concentrations and prolonged retention of azithromycin in Chinook may be factors that increase the efficacy of the antibiotic against *Renibacterium salmoninarum*, compared with erythromycin, particularly in early life history stages before covertly infected fish show clinical signs of disease.

KEY WORDS: Macrolide pharmacokinetics · Bacterial kidney disease · Juvenile · Chinook salmon

Resale or republication not permitted without written consent of the publisher

INTRODUCTION

Bacterial kidney disease (BKD), caused by the fastidious, slow-growing Gram-positive bacterium *Renibacterium salmoninarum*, is a severe systemic infectious disease of wild and hatchery-reared salmonids worldwide (Toranzo et al. 1990, Sakai & Kobayashi 1992, Fryer & Lannan 1993). BKD has long been implicated in catastrophic losses among hatchery populations of juvenile Pacific salmonids (Earp et al. 1953) and has been cited as the major factor limiting successful captive rearing of endangered salmon species in western North America (Flagg et al. 1995).

The macrolide antibiotic erythromycin has long been the chemotherapeutant of choice to prevent and control *Renibacterium salmoninarum* infections in salmonids (Elliott et al. 1989). Although treatment with

erythromycin may result in short-term health improvement, it often fails to eliminate the pathogen from the host and clinical signs may return after treatment ends (Wolf & Dunbar 1959). Vaccines currently available to prevent BKD in Pacific salmonids confer only limited protection (Rhodes et al. 2004), and there is a clear need for alternative chemotherapeutants, particularly in captive reared endangered stocks.

Azithromycin is a semi-synthetic macrolide drug derived from erythromycin with greatly improved extravascular penetration, tissue distribution, and a longer elimination half-life in serum and tissues (Girard et al. 1987). It concentrates in polymorphonuclear leukocytes, macrophages, and fibrocytes (Peters et al. 1992) which are all cell types that *Renibacterium salmoninarum* has been shown to invade (Bandin et al. 1993, Gutenberger et al. 1997). Azithromycin has strong *in vitro* bactericidal

*Email: william.fairgrieve@noaa.gov

activity against *R. salmoninarum* (Fryer 1987) and has demonstrated *in vivo* efficacy in experimentally infected juvenile salmonids (Strom et al. 2000).

The improved pharmacokinetic profile, broad spectrum of activity, and superior performance in controlling facultative intracellular pathogens make azithromycin an important antimicrobial drug to test for its ability to control *Renibacterium salmoninarum*. Although patterns of erythromycin accumulation and depletion in yearling Chinook salmon have been previously evaluated (Moffitt & Schreck 1988), the pharmacokinetic behavior of azithromycin in fish is unknown. The objective of this study was to compare the uptake, retention and clearance of orally administered erythromycin and azithromycin by fall Chinook salmon *Oncorhynchus tshawytscha* during the first feeding to smolt stage.

MATERIALS AND METHODS

Experimental fish and husbandry. In January 1999, unfed fall Chinook salmon fry (initial weight 0.42 g) obtained from the University of Washington research hatchery located at Big Beef Creek, Seabeck, WA, were counted into samples of 25 fish and distributed sequentially to 14 tanks until each contained 225 fish. The experiment was conducted in 1.83 m diameter (1250 l) circular polyethylene tanks. Temperature (10°C) and flow (10 l min⁻¹) were held constant throughout the experiment. Natural photoperiod was simulated in the laboratory with 2 levels of incandescent lighting, and adjustments in day length were made daily.

The fish were acclimated to laboratory conditions for 14 d, and fed to apparent satiation 4 to 6 times daily with a semi-moist starter diet (BioOregon starter diet, BioOregon). Thereafter, a growth model based on the delta-1 method (Butterbaugh & Willoughby 1967) was used to calculate the daily ration of a dry commercial salmon feed (Nutri-fry salmon diet, Moore-Clark Canada) required to produce smolts of ca. 16 g by June 15, 1999. Feeding schedules were adjusted according to actual growth and feed conversion data collected during monthly samplings.

Antibiotic administration. Duplicate groups of fish were fed diets medicated with azithromycin (A) or erythromycin (E) either once (A-1, E-1), twice (A-2, E-2), or 3 times (A-3, E-3) over a period of 140 d, beginning 14 d after initiation of exogenous feeding (February) and ending at smoltification (June) according to the schedule in Table 1. Dietary drug concentrations were adjusted during each feeding period to deliver 30 mg (active) azithromycin kg⁻¹ fish d⁻¹ for 14 d or 100 mg (active) erythromycin kg⁻¹ fish d⁻¹ for 28 d. Unmedicated diets were fed to duplicate groups of control fish throughout the

study and to test groups between antibiotic treatments and during the withdrawal period (Days 141 to 216).

Commercially available non-sterile erythromycin phosphate (Abbot Laboratories; 74.5% anhydrous potency) and azithromycin dihydrate (Zithromax[®] 250 mg tablets; Pfizer) were the test drugs. Medicated feeds were prepared by dissolving the antibiotics in 100% ethanol then spraying the mixture (25 ml kg⁻¹ feed) onto the dry salmon feed (Nutri-fry salmon diet). The feed was mixed thoroughly and the ethanol evaporated at room temperature. Pellets were frozen (-20°C) until used.

Collection and storage of tissues. At the beginning of the experiment (Day 0), before and after each antibiotic treatment, and 41 and 76 d after the final treatment ended, fish from each group were sampled to measure growth and whole body antibiotic concentrations. After the fish in each tank were bulk weighed and counted, 10 fish were sacrificed by immersion in a solution of tricaine methanesulfonate (>200 mg l⁻¹), blotted on damp paper towels, and placed into individual Whirl-pak[®] bags. The samples were stored frozen (-20°C). Feed was withheld for 36 h before sampling.

Tissue samples were collected from antibiotic-treated (n = 5 per replicate tank) and control (n = 10 per replicate tank) fish 45 d after the final treatment for histological evaluation. Samples of gill, head and trunk kidney, liver, spleen, heart, pyloric caeca, upper intestine, gonad, and brain from freshly killed fish were placed in Davidson's fixative for 24 to 36 h. The fixed tissues were transferred to a solution of ethanol in distilled water (70% v/v) and stored under refrigeration (5°C) until further processing.

Table 1. Treatment schedule, sizes of fish (g) and concentrations of azithromycin (A) and erythromycin (E) in diets fed to juvenile Chinook salmon once (A-1, E-1), twice (A-2, E-2), or 3 times (A-3, E-3). Dietary antibiotic concentrations provided daily dosages of 30 mg azithromycin or 100 mg erythromycin kg⁻¹ fish body weight. Unmedicated diet was fed to control fish throughout the study and to test groups between antibiotic treatments

Treatment period (d)	Treatment code	Range of fish weights (g)	Antibiotic concentration in feed (mg kg ⁻¹)
Azithromycin			
14–27	A-3	0.5–0.6	740
63–76	A-3, A-2	3.0–5.2	900–1225
113–126	A-3, A-2, A-1	11.1–13.0	1890–2560
Erythromycin			
14–41	E-3	0.5–1.3	2710
63–90	E-3, E-2	3.0–5.6	3000–4594
113–140	E-3, E-2, E-1	11.0–15.3	6300–8145

Antibiotic assays for erythromycin and azithromycin. The concentration of erythromycin and azithromycin in fish tissue was determined microbiologically as described by Evelyn et al. (1986a,b) using the bacterium *Micrococcus luteus*, which is sensitive to erythromycin concentrations as low as $0.00025 \mu\text{g } \mu\text{l}^{-1}$ of sample. The plate base layer (45 ml of Difco antibiotic medium 11, Difco Laboratories) was poured into 150×15 mm sterile Petri dishes and over-laid with 13.5 ml Difco Antibiotic Medium 11 inoculated with 0.2 ml of a *M. luteus* culture (optical density of 1.0 at 540 nm). Individual whole fish were weighed, placed into separate Whirl-pak® bags, and (1:1 w/v) phosphate buffer solution (pH 7.2) was added. Each sample was homogenized with a rubber roller. Five sterile 7 mm paper disks (Becton Dickinson Microbiology System) were evenly distributed around the edge of each inoculated plate, and a 6th was placed in the center. Aliquots (10 μl) of the diluted homogenates were transferred to the disks. An aliquot (10 μl) of erythromycin or azithromycin reference standard ($2.0 \mu\text{g ml}^{-1}$) was transferred by micropipette to the center disk of each plate. Plates were incubated at 30°C for 24 h after which the diameter of the zones of inhibition were measured to the nearest 0.5 mm. Antibiotic concentration was calculated from a standard curve (inhibition zone diameter vs \log_{10} antibiotic concentration in $\mu\text{g ml}^{-1}$) and corrected for dilution to determine equivalent antibiotic concentrations in the whole fish ($\mu\text{g g}^{-1}$ fish). Fish not fed antibiotics were tested and found to yield no inhibition of growth of *M. luteus*.

Histology. Fixed tissues were dehydrated, processed using a Shandon Hypercenter XP automated tissue processor, and embedded in Polyfin (Triangle Biomedical Sciences). Tissue sections (4 to 5 μm) were stained with haematoxylin and eosin-phloxine (Luna 1968), and examined by light microscopy. Tissue sections from fish from all treatments and untreated controls were first evaluated in a blind system by a single examiner who was unaware of their treatment history until all specimens had been examined. To confirm the results, a second evaluation was performed 1 yr later by the same examiner, but with knowledge of the treatment type or control status of each fish.

A semiquantitative, ordinal scoring system was used in which lesions were graded according to distribution on a scale of 1 to 5 (1 = focal; 2 = focal to multifocal; 3 = multifocal; 4 = multifocal to diffuse; 5 = diffuse), and severity on a scale of 0 to 7 (0 = absent; 1 = minimal; 2 = minimal to mild; 3 = mild; 4 = mild to moderate; 5 = moderate; 6 = moderate to severe; 7 = severe). Severity scores were based on the percentage of tissue affected by the particular lesion (0 = absent; 1 = 1 to 5%; 2 = 6 to 10%; 3 = 11 to 20%; 4 = 21 to 30%; 5 = 31 to 40%; 6 = 41 to 50%; 7 \geq 51%). Lesion distribution and severity

scores were recorded as the average of the 2 separate evaluations, if there were differences in the evaluation scores, which rarely occurred and did not involve diagnosis of significant toxicopathic lesions.

Morphologic changes were evaluated using criteria established in general fish pathology texts and reviews (Meyers & Hendricks 1985, Ferguson 1989, Bruno & Poppe 1996), general mammalian pathology and toxicology references (Cotran et al. 1999) and studies dealing specifically with the histopathological effects of erythromycin treatment on the kidney of salmonids (Hicks & Geraci 1984, Kiryu & Moffitt 2001, Moffitt & Kiryu 2001). Specific histopathological changes evaluated in kidney included vacuolation, cloudy swelling or necrosis of the proximal and distal tubules, macrophage aggregates or necrosis of haemopoietic tissue, and proteinaceous material within Bowman's space or renal tubules.

Statistical methods. A completely randomized experimental design (Steel & Torrie 1980) was used in which the 6 antibiotic treatments and 1 control were randomly assigned in duplicate to the 14 tanks of fish. Effects of the antibiotic treatment regimens on growth were assessed by 1-way analysis of variance (followed by Dunnett's test), comparing mean weights of treated and control groups at the end of the dosing phase of the experiment. The relationship between fish size at first exposure and accumulation of azithromycin or erythromycin was evaluated by comparing tissue concentration versus weight for groups of fish at first exposure to the antibiotics. Student's *t*-test or analysis of variance was performed on transformed \log_{10} (1 + concentration) data to determine whether antibiotic type or treatment frequency affected accumulation of the drug in the tissues. A single-phase exponential decay model, obtained by non-linear regression of tissue antibiotic concentration versus time (GraphPad Prism Statistical Software, GraphPad Software), described the antibiotic residue clearance kinetics during the final withdrawal phase of the experiment. Residue half-lives ($t_{1/2}$) were calculated as: $t_{1/2} = 0.6932/K$, where K was the elimination rate constant. Statistical analysis of the experimental results was performed using JMP® statistical software (SAS Institute). A level of significance of $p \leq 0.05$ was used in all statistical analyses.

RESULTS

Feed acceptability, growth and mortality

Diets medicated with erythromycin or azithromycin were well-accepted by juvenile fall Chinook salmon. Average weight gain in treated and control fish was

similar, except during the final treatment period when growth was slightly depressed in all antibiotic-treated groups (Fig. 1). The average weights of untreated control and azithromycin-treated groups were not significantly different ($p = 0.57$). Among fish treated with erythromycin, growth was significantly reduced only in the E-2 and E-3 groups ($p = 0.02$). No treatment-related mortality was recorded, although some random mortality due to traumatic injury occurred during sampling ($n = 4$).

Drug accumulation and clearance

Mean whole-body concentrations of azithromycin and erythromycin in juvenile Chinook salmon administered 1 to 3 courses of treatment are illustrated in Fig. 2. Average tissue concentrations of azithromycin after daily oral administration of 30 mg kg^{-1} for 14 d increased from $19.0 \mu\text{g g}^{-1}$ in fry (Day 28) to 34.5 mg kg^{-1} on Day 77 and $44.9 \mu\text{g g}^{-1}$ at the end of the dosing phase of the trial (Day 127). Post-treatment tissue concentrations of erythromycin were consistently lower, despite prolonged (28 d) treatment at a 3-fold higher (100 mg kg^{-1}) daily dose. Under this dosing regimen, average tissue concentrations were $0.2 \mu\text{g g}^{-1}$ in fry on

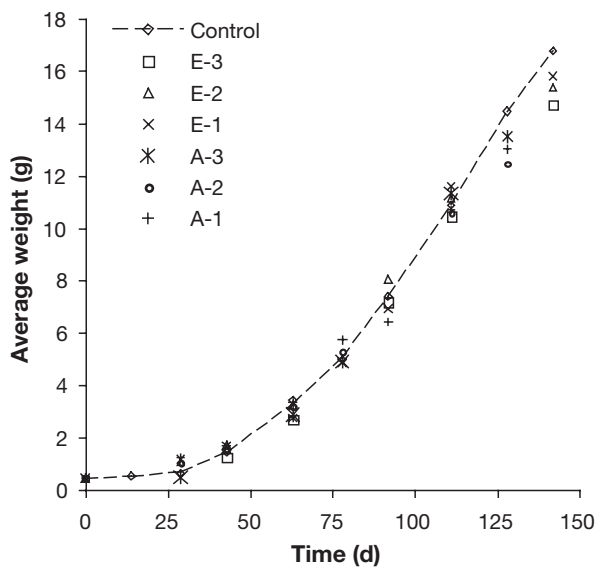


Fig. 1. *Oncorhynchus tshawytscha*. Growth of juvenile Chinook salmon fed diets containing either azithromycin (A) or erythromycin (E), once (A-1, E-1), twice (A-2, E-2), or 3 times (A-3, E-3), or an unmedicated control. Depressed growth was observed among all treated groups during the final treatment period which began on Day 113. The average weight of fish treated with azithromycin did not differ significantly ($p = 0.57$) from the untreated controls on Day 126 when treatment ended. Reductions in average weight, significant ($p = 0.02$) only in groups treated with erythromycin twice or 3 times, were observed on Day 141

Day 42, $2.5 \mu\text{g g}^{-1}$ on Day 91, and $10.4 \mu\text{g g}^{-1}$ on Day 141.

Although a pattern of increasing post-treatment concentration was observed in tissues of fish administered azithromycin or erythromycin twice (A-2, E-2) or 3 times (A-3, E-3), no significant effect of the num-

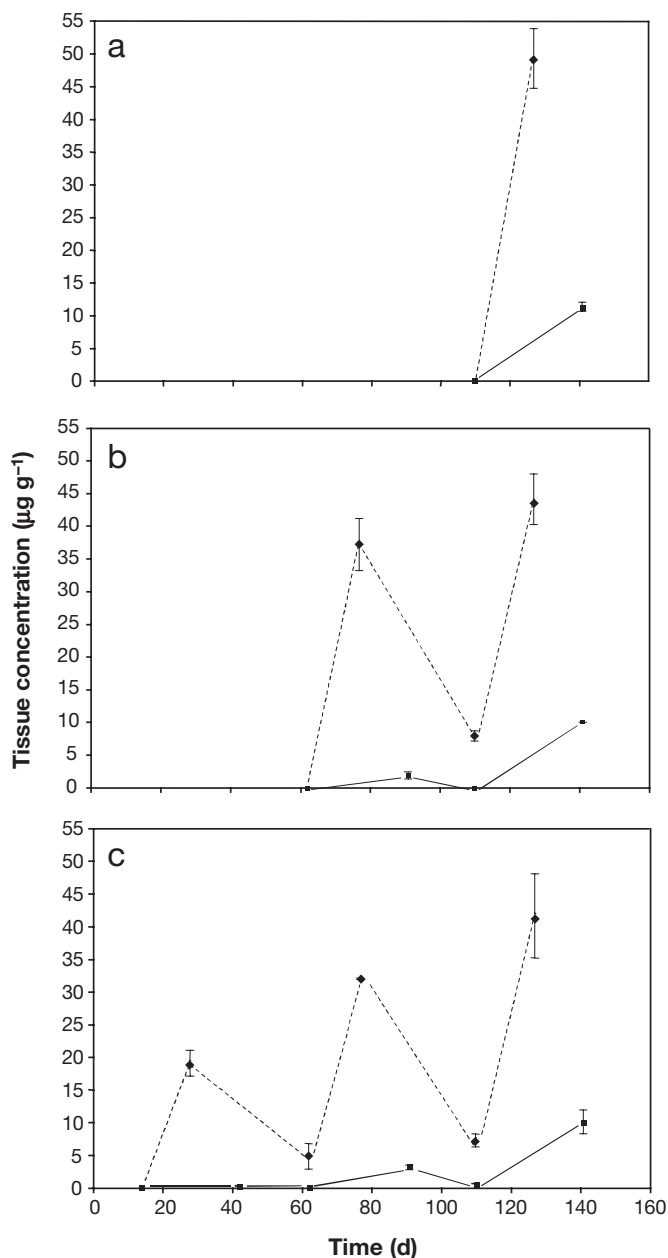


Fig. 2. *Oncorhynchus tshawytscha*. Accumulation of azithromycin (broken line) and erythromycin (solid line) in juvenile Chinook salmon following (a) 1, (b) 2, or (c) 3 courses of treatment. Antibiotic concentrations were measured in whole-body homogenates before and after each treatment, which consisted of daily oral doses of 30 mg kg^{-1} of azithromycin for 14 d or 100 mg kg^{-1} of erythromycin for 28 d. Data shown represent means \pm SE of $n = 2$ treated groups

ber of treatments previously administered was found. On Day 77 (azithromycin) and Day 91 (erythromycin), the average concentration of antibiotics in fish that had received a total of 1 (of 2) or 2 (of 3) treatments did not differ significantly (A-2 vs. A-3, $p = 0.30$; E-2 vs. E-3, $p = 0.15$). Similarly, at the end of the dosing phase, there were no significant differences in whole-body antibiotic concentrations between groups administered single or multiple treatments with either azithromycin (Day 127; $p = 0.61$) or erythromycin (Day 141; $p = 0.71$).

The tissue concentrations of azithromycin and erythromycin after the initial course of antibiotic treatment, expressed as a function of body weight, are summarized in Fig. 3. This relationship was developed to determine the extent to which absorption and retention was influenced by fish size. For both antibiotics, tissue concentrations were lowest in small (0.5 to 0.6 g) fish, and increased with fish size. Tissue concentrations of erythromycin, which averaged $0.2 \mu\text{g g}^{-1}$ in 0.6 g fish, increased 10- to 60-fold in fish averaging 5.5 to 13.6 g. By contrast, tissue concentrations of azithromycin observed in fish averaging 4.2 g and 11.9 g were only 1.9 to 2.5 times higher than those measured in the smallest fish tested (0.5 g, $19 \mu\text{g g}^{-1}$). These data reflect the generally higher absorption and retention of azithromycin observed in this study.

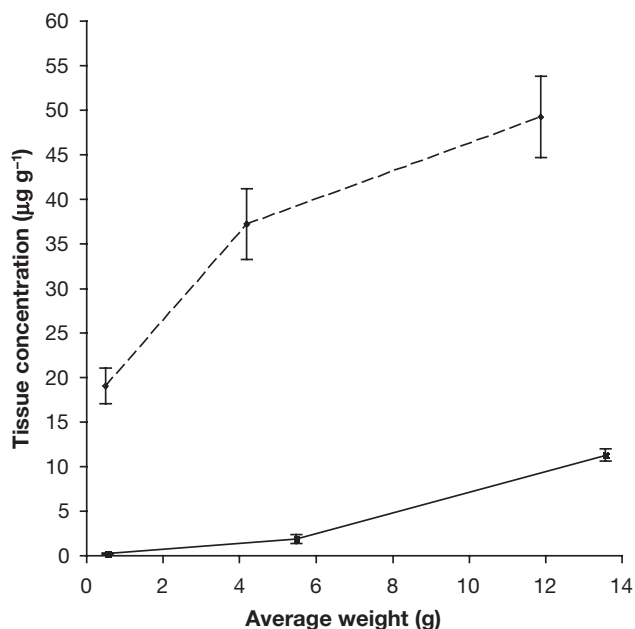


Fig. 3. *Oncorhynchus tshawytscha*. Effect of fish size on accumulation of azithromycin (broken line) and erythromycin (solid line) in juvenile Chinook salmon. Antibiotic concentrations were measured in whole-body homogenates after daily oral doses of 30 mg kg^{-1} of azithromycin for 14 d or 100 mg kg^{-1} of erythromycin for 28 d. Data shown represent means \pm SE of $n = 2$ treated groups

Azithromycin was more persistent than erythromycin in the tissues of juvenile Chinook salmon. During the dosing phase of the trial (Fig. 2), residues of azithromycin, but not erythromycin, were found at each pre-treatment sampling following the initial exposure. Thirty-five days post-exposure, azithromycin concentrations ranged from 4.7 to $7.9 \mu\text{g g}^{-1}$, but erythromycin was eliminated within 21 d.

During the withdrawal phase of the trial (Fig. 4), azithromycin elimination kinetics followed a single-phase exponential decay model, with an elimination half-life of 14.7 d. The half-life of erythromycin could not be estimated because tissue concentrations were below the detection limit by the second post-treatment sampling.

Histopathology

No lesions of pathological significance were detected in liver, exocrine pancreas, gill, pyloric caeca, upper intestine, heart, head kidney, spleen, or gonad. No lesions indicative of antibiotic toxicity were observed in the excretory or haemopoietic elements of the trunk kidney of fish from any of the erythromycin or azithromycin treatments or untreated controls. Incidental findings of single, minor cases of nephro-

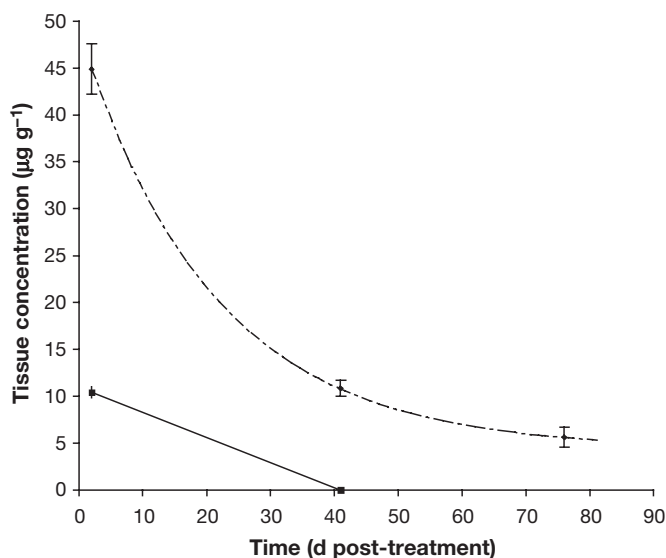


Fig. 4. *Oncorhynchus tshawytscha*. Antibiotic depletion curves for juvenile Chinook salmon following daily oral doses of azithromycin at 30 mg kg^{-1} for 14 d (broken line) or erythromycin at 100 mg kg^{-1} for 28 d (solid line). No erythromycin was detected at the second sampling (41 d post-treatment). Azithromycin elimination kinetics followed a single-phase exponential decay model: $y = 40.51 \times 2.71828^{(-0.04715x)} + 4.393$. The elimination half-life for azithromycin was 14.7 d. Data shown represent means \pm SE of $n = 6$ treated groups

calcinosis scored as 1 or 2 in distribution and 1 or 2 in severity were observed in fish from the following treatments: untreated controls, E-2, A-1, and A-2. Female fish from all treatment and control groups displayed oocytes at the late perinucleolus stage of maturation (secondary oocytes) (Nagahama 1983). Male fish from all groups were primarily at the regressed stage of testicular maturation, composed almost entirely of Type A or primary spermatogonia, with a few fish showing early and late recrudescence (up to the development of spermatids). Males in these later stages of testicular maturation were rare, and were distributed evenly among the treatment and control groups.

DISCUSSION

Medicated diets were well-accepted by juvenile Chinook salmon in the present study, and no reductions in palatability were apparent at concentrations as high as 2560 mg azithromycin or 8145 mg erythromycin kg^{-1} of feed. In contrast, Schreck & Moffitt (1987) found that yearling Chinook salmon smolts offered diets containing 6700 mg erythromycin thiocyanate kg^{-1} consumed fewer pellets than those offered an unmedicated control feed; acceptability further declined when the antibiotic concentration was increased to 10 000 and 12 000 mg kg^{-1} . Reasons for these differences in palatability are not known, although it is possible that the thiocyanate form of erythromycin used in the 1987 study is less palatable than the phosphate form used in the present trial.

Macrolide antibiotics are well known for their ability to penetrate tissues and extravascular fluids in a variety of animals. However, the much greater tissue penetration and persistence of azithromycin compared with erythromycin in animals other than fish is especially noteworthy. The affinity of azithromycin for tissues in rats (Girard et al. 1987) and dogs (Shepard & Falkner 1990) is demonstrated by tissue to plasma area-under-the-curve ratios ranging from 10 to more than 100 after a single oral dose. In contrast, tissue to plasma concentration ratios ranging from 3 to 12 have been reported for erythromycin in various tissues in rats (Girard et al. 1987). Similar trends were observed in the present study with Chinook salmon, with whole body azithromycin concentrations ranging from 4- to 100-fold higher than for erythromycin, despite the lower daily dosage and reduced length of treatment.

Consistent with its high affinity for tissues, azithromycin exhibits a prolonged elimination half-life in a variety of animal models. For example, elimination half-life in rat lung after a single oral dose was about 23 h for azithromycin, but only about 1 h for eryth-

romycin. While erythromycin was eliminated within 20 h, measurable levels of azithromycin persisted for more than 90 h (Girard et al. 1987). In dogs given multiple doses, azithromycin was detected in spleen, lung, liver, and kidney 57 d after treatment was terminated.

In this comparative study with Chinook salmon, azithromycin remained detectable in fish tissues for at least 76 d following drug withdrawal. In contrast, erythromycin was cleared from the tissues within 21 d after medicated feed was discontinued. These data confirm the results of Moffitt & Schreck (1988), who reported rapid, tissue-specific post-treatment elimination. In their study, erythromycin was not detectable in the blood, plasma, or muscle of juvenile Chinook salmon 10 d after drug administration ceased, but small quantities ($\leq 0.5 \mu\text{g ml}^{-1}$) were present in the kidney and liver after 19 d.

Contrary to expectations, deleterious changes in kidney and liver tissues often reported in trout and salmon treated with erythromycin were not observed in the present study, despite prolonged and repeated exposure to the drug. Piper (1961) and Warren (1963) observed haemoglobin deposition in the haematopoietic regions of the kidney of rainbow trout. Haemorrhagic ascites, yellow-green livers and kidney damage that included tissue damage, necrosis, and vacuolization of the tubules, have all been observed in maturing Chinook salmon injected with erythromycin (Moffitt & Kiryu 2001). Damage may be short-lived, however. In juvenile rainbow trout, necrotic damage to the proximal renal tubules of juvenile rainbow trout following oral administration of erythromycin (110 mg kg^{-1} fish d^{-1} for 18 d), was completely repaired within 14 d after feeding ceased (Hicks & Geraci 1984). These data may explain in part the absence of histologically significant lesions in fall Chinook salmon in the present study, which were sampled 45 d after treatment ended. In this regard, the finding that erythromycin was no longer detected in the tissues 21 d post-treatment is particularly relevant. The absence of toxic effects in Chinook salmon administered multiple treatments with azithromycin is however noteworthy. Because of its prolonged elimination half-life, groups of fish administered 3 consecutive treatments were continuously exposed to azithromycin for more than 6 mo without demonstrable adverse effects on growth or survival, or the development of histologically significant lesions in any of the tissues evaluated.

Quantitative differences in tissue antibiotic concentrations for fish of different sizes demonstrated in this study have important implications for the design of therapeutic regimens. Accumulated concentrations of erythromycin in first feeding fry ($0.19 \mu\text{g g}^{-1}$) were only 3.5% of the concentration considered bacteriostatic to

90% of the strains tested by Bandin et al. (1991). Marginally inhibitory concentrations of erythromycin were found in fish averaging 5.6 g (1.84 to 3.18 $\mu\text{g g}^{-1}$), but bactericidal concentrations (9.97 to 11.20 $\mu\text{g g}^{-1}$) were attained only at smoltification, when they weighed 15.6 g. In contrast, concentrations of azithromycin in the whole body tissues of Chinook salmon ranged from 18.98 $\mu\text{g ml}^{-1}$ in first feeding fry, to nearly 50 $\mu\text{g ml}^{-1}$ in smolts. Fryer (1987) found the *in vitro* minimum inhibitory concentration (MIC) for azithromycin against 4 strains of *Renibacterium salmoninarum* (Type Strains ATCC 33209 and 33739; D-6, a USA isolate from coho salmon; and 932, a Norwegian isolate from Atlantic salmon) to be only one-half of the inhibitory concentration for erythromycin. Thus, it appears that therapeutically efficacious tissue levels of azithromycin can be attained even in first feeding fry.

Adequate concentrations of antibiotic must be maintained at the site of infection to be efficacious, whether in tissues, extravascular fluids, or cells. The high tissue concentrations and prolonged retention of azithromycin in Chinook may increase the effectiveness of the antibiotic against *Renibacterium salmoninarum*, compared with erythromycin, particularly in early life history stages before infected fish show clinical signs of disease. Additional research to measure the bioavailability of orally administered azithromycin, to determine minimum concentrations bactericidal to *R. salmoninarum in vivo*, and to describe the pharmacokinetics of the antibiotic will be required to establish therapeutic regimens for its use.

Acknowledgements. This work was supported by the US Department of Energy and Bonneville Power Administration under contract no. 99-AI-17859. The authors would like to acknowledge K. Shearer and D. Frost for technical assistance with this project.

LITERATURE CITED

- Bandin I, Santos Y, Toranzo AE, Barja JL (1991) MICs and MBCs of chemotherapeutic agents against *Renibacterium salmoninarum*. *Antimicrob Agents Chemother* 35: 1011–1013
- Bandin I, Ellis AE, Barja JL, Secombes CJ (1993) Interaction between rainbow trout macrophages and *Renibacterium salmoninarum in vitro*. *Fish Shellfish Immunol* 3:25–33
- Bruno DW, Poppe TT (1996) A colour atlas of salmonid diseases. Academic Press, London
- Butterbaugh GL, Willoughby H (1967) A feeding guide for brook, brown, and rainbow trout. *Prog Fish-Cult* 29: 210–215
- Cotran RS, Kumar V, Collins T, Robbins SL (1999) Robbins' pathologic basis of disease, 6th edn. WB Saunders, Philadelphia, PA
- Earp BL, Ellis CH, Ordal EJ (1953) Kidney disease in young salmon. Special Report Series (1) Washington Department of Fisheries, Olympia
- Elliott DG, Pascho RJ, Bullock GL (1989) Developments in the control of bacterial kidney disease in salmonid fishes. *Dis Aquat Org* 6:201–215
- Evelyn TPT, Ketcheson JE, Prospero-Porta L (1986a) Experimental intra-ovum infection of salmonid eggs with *Renibacterium salmoninarum* and vertical transmission of the pathogen with such eggs despite their treatment with erythromycin. *Dis Aquat Org* 1:197–202
- Evelyn TPT, Ketcheson JE, Prospero-Porta L (1986b) Use of erythromycin as a means of preventing vertical transmission of *Renibacterium salmoninarum*. *Dis Aquat Org* 2:7–11
- Ferguson HW (1989) Systemic pathology of fish. Iowa State University Press, Ames, IA
- Flagg TA, Mahnken CVM, Johnson KA (1995) Captive broodstocks for recovery of Snake River sockeye salmon. In: Schramm HL, Piper RG (eds) Uses and effects of cultured fishes in aquatic ecosystems. *Am Fish Soc Symp* 15, Bethesda, MD, p 81–90
- Fryer JL (1987) Epidemiology and control of infectious diseases of salmonids in the Columbia River Basin. Annual report 1987 to Bonneville Power Administration, Portland, OR, Contract 83-AI-11987, Project 38–312, 130 electronic pages (BPA Report DOE/BP-11987–3)
- Fryer JL, Lannan CN (1993) The history and current status of *Renibacterium salmoninarum*, the causative agent of bacterial kidney disease in Pacific salmon. *Fish Res* 17:15–33
- Girard AE, Girard D, English AR, Gootz TD, Cimochoowski CR, Faiella JA, Haskell SL, Retsema JA (1987) Pharmacokinetic and *in vivo* studies with azithromycin (CP-62,993), a new macrolide with an extended half-life and excellent tissue distribution. *Antimicrob Agents Chemother* 31: 1948–1954
- Gutenberger SK, Duimstra JR, Rohovec JS, Fryer JL (1997) Intracellular survival of *Renibacterium salmoninarum* in trout mononuclear phagocytes. *Dis Aquat Org* 28:93–106
- Hicks BD, Geraci JR (1984) A histological assessment of damage in rainbow trout, *Salmo gairdneri*, fed rations containing erythromycin. *J Fish Dis* 7:457–465
- Kiryu Y, Moffitt CM (2001) Acute LD50 and kidney histopathology following injection of erythromycin (Erythro-200) and its carrier in spring Chinook salmon, *Oncorhynchus tshawytscha* (Walbaum). *J Fish Dis* 24: 409–416
- Luna LB (1968) Manual of histologic staining methods of the Armed Forces Institute of Pathology, 3rd edn. McGraw-Hill, New York
- Meyers TR, Hendricks JD (1985) Histopathology. In: Rand GM, Petrocelli SR (eds) Fundamentals of aquatic toxicology. Hemisphere, Washington, DC, p 283–331
- Moffitt CM, Kiryu Y (2001) Acute and chronic toxicity following parenteral application of erythromycin (Erythro-200) to maturing spring Chinook salmon held at two water temperatures. *J Aquat Anim Health* 13:8–19
- Moffitt CM, Schreck JA (1988) Accumulation and depletion of orally-administered erythromycin thiocyanate in the tissues of Chinook salmon. *Trans Am Fish Soc* 117: 394–400
- Nagahama Y (1983) The functional morphology of teleost gonads. In: Hoar WS, Randall DJ, Donaldson EM (eds) Fish physiology, Vol 9A. Academic Press, New York, p 223–275
- Peters DH, Freidel HA, McTavish D (1992) Azithromycin: a review of its antimicrobial activity, pharmacokinetic properties, and clinical efficacy. *Drugs* 44:750–799
- Piper RG (1961) Toxic effects of erythromycin thiocyanate on rainbow trout. *Prog Fish-Cult* 23:134–135
- Rhodes LG, Rathbone CK, Corbett SC, Harrell LW, Strom MS

- (2004) Efficacy of cellular vaccines and genetic adjuvants against bacterial kidney disease in chinook salmon (*Oncorhynchus tshawytscha*). *Fish Shellfish Immunol* 16: 461–474
- Sakai M, Kobayashi M (1992) Detection of *Renibacterium salmoninarum*, the causative agent of bacterial kidney disease in salmonid fish, from pen-cultured coho salmon. *Appl Environ Microbiol* 58:1061–1063
- Schreck JA, Moffitt CM (1987) Palatability of feed containing different concentrations of erythromycin thiocyanate to Chinook salmon. *Prog Fish-Cult* 49:241–247
- Shepard RM, Falkner FC (1990) Pharmacokinetics of azithromycin in rats and dogs. *J Antimicrob Chemother* 25 Suppl. A:49–60
- Steel RGD, Torrie JH (1980) Principles and procedures of statistics—a biometrical approach, 2nd edn. McGraw-Hill, New York
- Strom MS, Fairgrieve WT, Harrell L, Rathbone CK (2000) Efficacy and toxicity of treatments for bacterial kidney disease in Chinook salmon. In: Berejikian BA (ed) Research on captive broodstock programs for Pacific salmon. FY2000 Annual Report to Bonneville Power Administration, Contract No. 99-AI-17859, p 105–110
- Toranzo AE, Santos Y, Bandin I, Romalde JL, Ledo A, Fouz B, Barja JL (1990) Five year survey of bacterial fish infections in continental and marine aquaculture in northwest Spain. *World Aquacult* 21:91–94
- Warren JW (1963) Toxicity tests of erythromycin thiocyanate in rainbow trout. *Prog Fish-Cult* 25:88–92
- Wolf K, Dunbar CE (1959) Test of 34 therapeutic agents for control of kidney disease in trout. *Trans Am Fish Soc* 88: 117–124

*Editorial responsibility: David Bruno,
Aberdeen, UK*

*Submitted: April 26, 2004; Accepted: October 28, 2004
Proofs received from author: March 8, 2005*