Vol. 108: 53–60, 2014
doi: 10.3354/dao02691

DISEASES OF AQUATIC ORGANISMS
Dis Aquat Org

Published February 4

Occurrence of tumour (odontoma) in marine fish *Sphyraena jello* from the southeast coast of India

R. Vijayakumar, A. Gopalakrishnan*, K. Raja, K. Sinduja

Centre of Advanced Study in Marine Biology, Annamalai University, Parangipettai, Tamil Nadu, India

ABSTRACT: We examined the occurrence of odontoma in the marine fish *Sphyraena jello* sourced from 3 different landing centers (Cuddalore, Parangipettai and Nagapattinam) in Tamil Nadu (southeast India). A total of 19783 fishes were examined for odontoma presence, of which 2393 were affected with odontoma. The overall prevalence was 12.1% among the 3 stations. Fish landed at Parangipettai showed the highest peak prevalence of odontoma (16.8%) during the pre-monsoon, followed by Nagapatinam (9.1%) during summer 2011. The tumour lengths in premaxilla, supermaxilla and dentary bone were 1.1–3.6, 1.4–5.9 and 1.2–4.1 cm, respectively, and tumour widths were 0.3–1.9, 0.7–3.1 and 0.5–1.9 cm. Higher prevalence (0.206%) of tongue tumour along with odontoma was observed at Nagapattinam whereas it was lower (0.162%) at Cuddalore. Odontoma histopathology showed dense fibrous tissue with fine teeth roots. TEM analysis showed virus-like particles associated with odontoma. Radiography of the odontoma showed that the tumour masses were bony in nature and tissues were merged with upper and lower jaw.

KEY WORDS: Pickhandle barracuda · Histopathology · Odontoma · Prevalence · Radiography · Tumour · Viral particles

INTRODUCTION

Disease and parasitism are threats to fish diversity, so it is important to identify those pathogens and parasites which represent the greatest potential risks (Daszak et al. 2000, Smith et al. 2006). The marine environment possesses a wide range of physico-chemical and biological parameters, and if natural conditions exceed the limits of a species' adaptability, it may cause stress and lead to disease outbreaks (Roberts 1989). Increases in the air and water temperature can enhance the reproductive rate of vector organisms (Freed et al. 2005), increase the growth rate of pathogen populations (Woodhams et al. 2008) and also accelerate transmission rates by causing proliferation of infective stages (Freed et al. 2005, Poulin, 2006). Tumours are a common affliction, which may be caused by infectious viruses, inherent genetic factors or chemical carcinogens; cells become aggressive, invasive and sometimes metastatic (Martineau & Ferguson 2006).

Natural fish populations have been found to have tumours in almost all tissue systems, but most of these tumours are of unknown etiology (Harshbarger 1977). Data on fish tumour occurrence in India are very sparse to date (e.g. Sarkar & Datta Chaudhuri 1953, Lakshmanaperumalsamy et al. 1976, Rao & Rao 1979). Gopalakrishnan et al. (2011) reported the occurrence of neoplastic tumours in economically valuable fish species, the great barracuda *Sphyraena barracuda* and oil sardine *Sardinella longiceps*, from

*Corresponding author: aquagopal@gmail.com

the southeast coast of India. Odontomas are the most common odontogenic tumour in great barracuda *S. barracuda* and are usually considered to be hamartomas rather than choristomas, being composed of the tissues native to teeth (i.e. enamel, dentin, cementum and pulp tissue) (Gopalakrishnan et al. 2011). Hence the present study focused on the prevalence and etiology of odontoma in a related species, pickhandle barracuda *S. jello*, from the same locations.

MATERIALS AND METHODS

Sample collection

Sphyraena jello specimens were collected from commercial catches landed at 3 different locations (Cuddalore, Parangipettai and Nagapatinam) on the southeast coast of India (Fig. 1) between April 2009 and March 2012 and examined for odontoma and tongue tumour presence. Affected fishes were brought to the laboratory for further investigation. Fish were identified in the laboratory based on an FAO fish identification sheet (De Bruin et al. 1995). The nature of the tumour and total number of teeth were recorded. For radiography analysis (X-ray), the heads of the affected fish were thoroughly washed with tap water and then by distilled water, and the radiographs were taken at 100 mA in 45 kV.

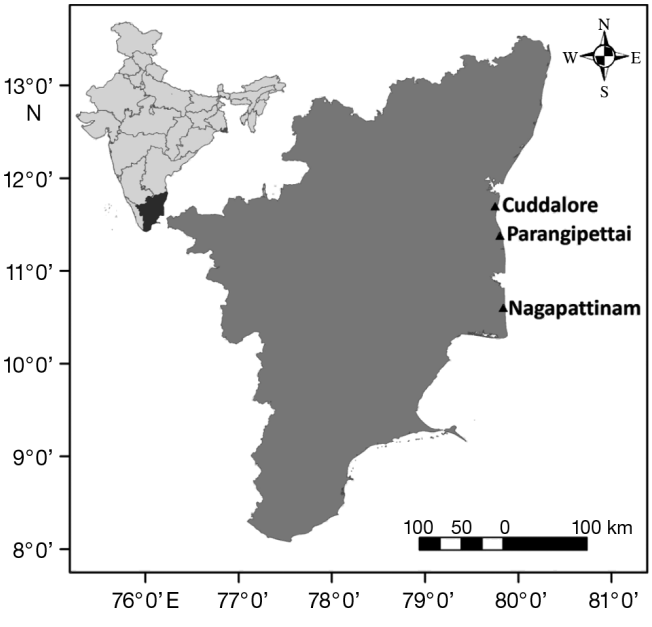

Fig. 1. Location of fishing ports in southwest India where *Sphyraena jello* sample collection occurred

Histology

The tumour tissues were fixed in 10% neutral buffered formaldehyde solution for 24 h, then rinsed several times in tap water before being dehydrated through a graded series of ethanol, cleaned in xylene and embedded in paraffin wax. Thin sections (3 µm) were cut with a rotary microtome, stained with Harris haemotoxylin and counter-stained with eosin (Coolidge & Howard 1979). The stained tissues were examined under a microscope (40× magnification), and digital images of histological features were obtained using the Lucia (Laboratory Imaging, www.forensic.cz/en/products) screen measurement system.

Transmission electron microscopy

Small fragments of tissues were fixed in 2.5% glutaraldehyde in 0.2 M cacodylate buffer (pH 7.6) for 2 h at 4°C. After fixation the tissue was soaked in cacodylate buffer for 2 h at 4°C, and postfixed in 2% osmium tetraoxide for 2 h at 4°C. The fragments were dehydrated using a graded ethanol series and embedded in Epon.

Skeletal structure analysis

The odontoma-affected fishes head were cut off and washed with tap water, then with distilled water. The heads were kept in sealed polythene bags at room temperature for up to 10 d, and then thoroughly washed under running tap water to dislodge the soft tissues.

RESULTS

Tumour prevalence

The seasonal prevalences of odontoma in *Sphyraena jello* landed at the 3 collection locations are given in Table 1. Of 19783 examined fish, 2393 were affected with odontoma, with an overall prevalence of 12.1%. The highest prevalence by location was observed in fish from Parangipettai (12.6%) followed by Cuddalore (12.1%) and Nagaatinam (11.5%). The highest seasonal prevalence (16.8%) was observed during the pre-monsoon 2009 at Parangipettai, whereas the lowest seasonal prevalence (9.1%) occurred during summer 2011 at Nagapatinam (Table 1). Among the odontoma-infected fishes, 36 were also affected with tongue tumours: the highest

Table 1. Prevalence of odontoma and tongue tumours in *Sphyraena jello* landed at 3 sites in Tamil Nadu, southeast India. Seasons are based on calendar months (post-monsoon, Jan–Mar; summer, Apr–Jun; pre-monsoon, Jul–Sep; monsoon, Oct–Dec)

Year	Season	No. of fish examined	Odontoma		Tongue tumour	
			No.	Prevalence (%)	No.	Prevalence (%)
Cuddalore						
2009	Summer	618	72	11.65	1	0.162
	Pre-monsoon	302	43	14.24	0	0.000
	Monsoon	547	69	12.61	2	0.366
2010	Post-monsoon	623	65	10.43	1	0.161
	Summer	587	62	10.56	0	0.000
	Pre-monsoon	538	65	12.08	0	0.000
	Monsoon	409	57	13.94	1	0.244
2011	Post-monsoon	475	54	11.37	0	0.000
	Summer	602	58	9.63	1	0.166
	Pre-monsoon	516	71	13.76	2	0.388
	Monsoon	450	67	14.89	1	0.222
2012	Post-monsoon	510	65	12.75	1	0.196
Total		6177	748	12.11	10	0.162
Parangipettai						
2009	Summer	633	73	11.53	1	0.158
	Pre-monsoon	296	50	16.89	0	0.000
	Monsoon	468	53	11.32	1	0.214
2010	Post-monsoon	507	64	12.62	1	0.197
	Summer	575	69	12.00	2	0.348
	Pre-monsoon	632	83	13.13	0	0.000
	Monsoon	661	96	14.52	1	0.151
2011	Post-monsoon	702	90	12.82	2	0.285
	Summer	524	65	12.40	0	0.000
	Pre-monsoon	596	62	10.40	1	0.168
	Monsoon	644	91	14.13	2	0.311
2012	Post-monsoon	585	63	10.77	1	0.171
Total		6823	859	12.59	12	0.176
Nangipattinam						
2009	Summer	586	65	11.09	1	0.171
	Pre-monsoon	317	42	13.25	1	0.315
	Monsoon	490	60	12.24	0	0.000
2010	Post-monsoon	532	64	12.03	1	0.188
	Summer	600	58	9.67	1	0.167
	Pre-monsoon	566	71	12.54	2	0.353
	Monsoon	643	73	11.35	1	0.156
	Post-monsoon	685	85	12.41	2	0.292
2011	Summer	593	54	9.11	1	0.169
	Pre-monsoon	701	92	13.12	2	0.285
	Monsoon	498	63	12.65	1	0.201
2012	Post-monsoon	572	59	10.31	1	0.175
Total		6783	786	11.59	14	0.206
Grand total		**19783**	**2393**	**12.10**	**36**	**0.182**

station-wise prevalence was 0.206% recorded at Nagapattinam, and the lowest prevalence was 0.162% at Cuddalore (Table 1).

Tumour descriptions

The largest tumours were observed in the supramaxilla (left side), with a mean (±SD) length of 3.2 ± 0.7 cm and width of 1.7 ± 0.5 cm. The smallest tumours were seen in the premaxilla (left side), with a length 1.9 ± 0.4 cm and width of 1.1 ± 0.3 cm (Fig. 2). Normal fish possess 128 teeth (premaxilla 72, supramaxilla 22 and dentary bone 34), but the teeth counts of the odontoma-affected fish were variable: a maximum 83 and 78 in the right and left supramaxilla, respectively, and a minimum of 8 in the right premaxilla (Fig. 3). The odontoma were mostly bony, with only a few being

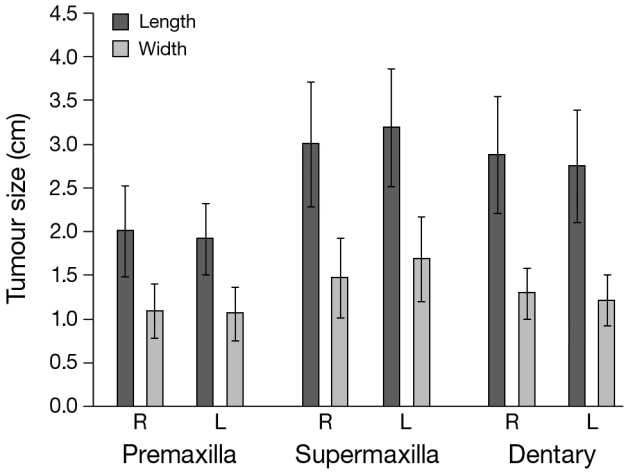

Fig. 2. *Sphyraena jello.* Sizes and locations of odontomas found in affected fish. R: right side; L: left side

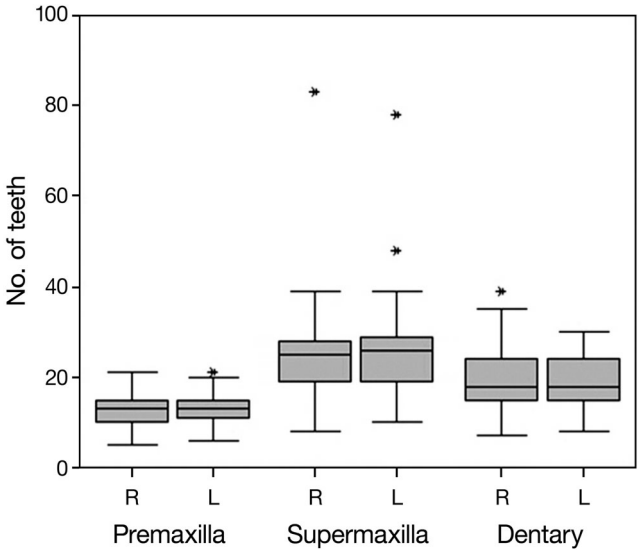

Fig. 3. *Sphyraena jello.* Numbers of teeth in jawbones of fish affected by odontoma (note that normal fish have 128 teeth in total: premaxilla 72, supramaxilla 22 and dentary bone 34). Horizontal line: 50% percentile (median); box: 25th to 75th percentiles; whiskers: 10th and 90th percentiles; asterisks: outliers. R: right side; L: left side

soft tissue, and located mostly in the upper jaw, lower jaw and tongue regions of the fish. In some cases, the tumour affected both jaws. Generally a single tumour occupied the entire mouth of the fish, but multiple tumours (2–6 nodes) were also observed in many fishes (Fig. 4). The radiographic analysis of the odontoma-affected fish showed that the mass of extra bone tissue was usually merged with the upper and lower jaws (Fig. 5), with the normal structure of the skeleton being disrupted (either by deterioration of normal structures, or addition of extra bone mass) (Fig. 6).

Histopathology

Under light microscopic observation, odontoma showed dense fibrous tissue with fine toothlets extending into the bony trabecular tissue of the jaw and medium to large or oval-shaped nuclei, one or more small but distinct nucleoli and moderate to abundant amounts of well-defined amphophilic cytoplasm (Fig. 7). Transmission electron microscopic (TEM) examination of tissues from the odontoma-affected fish revealed the presence of enveloped virus-like particles about 100 nm in diameter with a well-defined electron-dense core, generally in extracellular space near plasmocytes and apparently endocytic events associated with odontoma (Fig. 8).

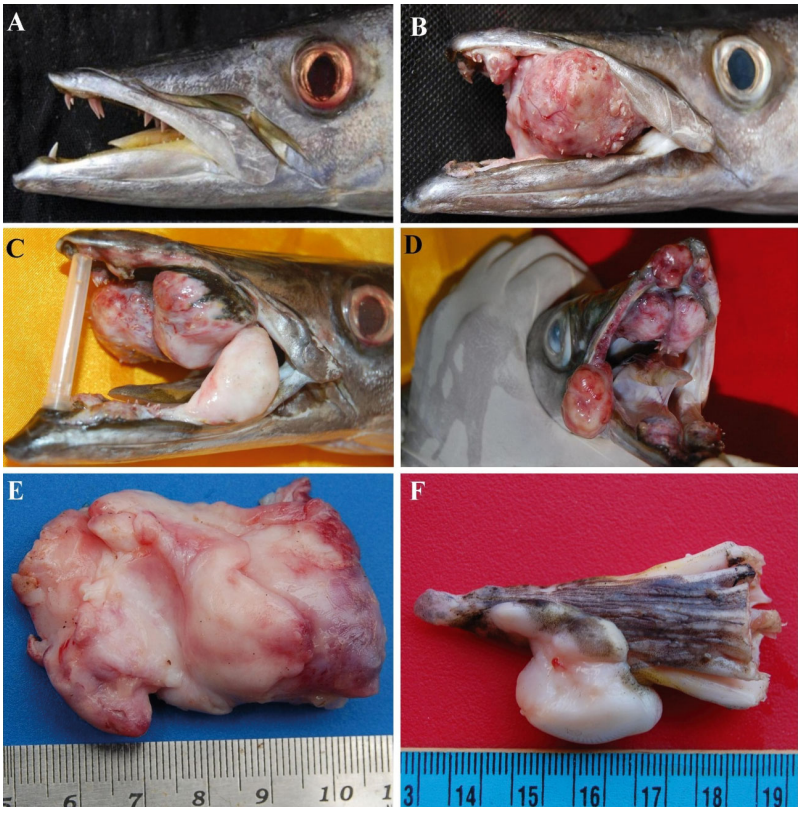

Fig. 4. *Sphyraena jello.* (A) Normal fish. Various forms of odontoma were found in affected fish: (B,C) large odontomas nearly obstructing the gullet in 2 individual fish; (D) smaller, multi-node odontomas; (E) tumour mass excised from the jaw; (F) tongue tumour. Rulers show cm

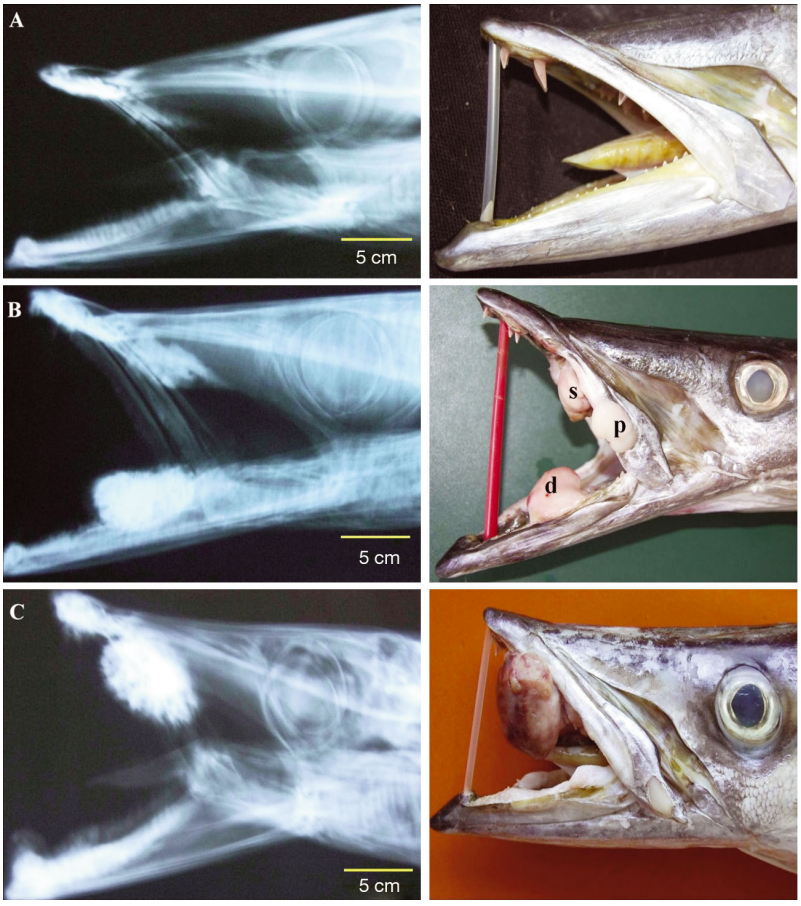

Fig. 5. *Sphyraena jello.* Radiographic comparison. (A) Normal fish. (B) Fish presenting multiple small odontomas in the dentary bone (d), supramaxilla (s) and premaxilla (p). (C) Fish presenting a large odontoma in the supramaxilla

DISCUSSION

Reports on odontoma in fishes are very scarce worldwide (Schlumberger & Lucke 1948, Harshbarger 1974, Budd & Roberts 1978, Mawdesley-Thomas 1975, Hays & Ferguson 1989, Sinderman 1990, Grabda 1991). However, other kinds of odontogenic tumours have been reported by Thomas (1926), while ameloblastoma in *Melanogrammus aeglefinus* was described by Schlumberger & Katz (1956), fibroameloblastoma in *Oncorhynchus tshawytscha* by Stolk (1957), and ameloblastoma in *Cyprinodon variegatus variegatus*, odontoblastic papillomatosis in *Sparus auratus*, and ameloblastoma and ameloblastic odontomas in *Tautogolabrus adsphersus* by Harshbarger (1974). Recently Gopalakrishnan et al. (2011) reported odontoma prevalence of 1.01% in great barracuda *Sphyraena barracuda* at Parangipettai coast Tamil Nadu, India. The present study is the first report on odontoma occurrence in *S. jello* from the southeast coast of India. The highest odontoma prevalence was recorded during the monsoon season (October–December) at Parangipettai, which may be due to contaminated water run-off containing oil, sewage, and/or industrial waste.

Odontomas can be confidently classified based on the radiographic appearance alone. Compound odontomas appear as a collection of small teeth leaving few entities in the radiographic differential diagnosis except perhaps, supernumerary teeth. Complex odontomas appear as a radiodense mass of hard tissues, which may result in a broader differential diagnosis (Bordini et al. 2008, Serra-Serra et al. 2009). In *S. jello* in the present study, compound odontomas were reported; the tumours consisted of the tissues native to teeth (enamel, dentin, cementum and pulp tissue).

Odontomas are generally small; however, they may occasionally grow large resulting in bone expansion (Bordini et al. 2008). In the present study, odontomas in *S. jello* were large and occupied the entire buccal cavity of the fish, which likely affects their feeding activity. Condition factor of affected fishes is currently being investigated. These kinds of odontoma in marine fishes are very rare, but in *S. jello* most of the tumours in the supramaxillae and some in the premaxillae were large in size (although odontomas of the dentary bone were smaller). The radiography showed that the odontoma in *S. jello* was a bony tumour; this is similar to observations by Gopalakrishnan et al. (2011) in *S. barracuda.*

Histological examination is usually used as a tool to evaluate the health of organisms, since this is reflected by the morphological structure of the cells and tissue (Yevich & Barszcz 1983). In this study, gross observation of odontoma tissues showed that fine toothlets and extra teeth were present within the tumour mass. Tumour occurrence in fish may be the result of many factors such as viruses, chemical carcinogen and parasitic attack; the viral etiology of papillomas was first suggested by Keysselitz (1908). Twenty-two apparently distinct herpesviruses have been described from cartilaginous and bony fishes (Hedrick & Sano 1989) and from Japanese eel (Sano et al. 1991). Adenovirus-like particles were described in

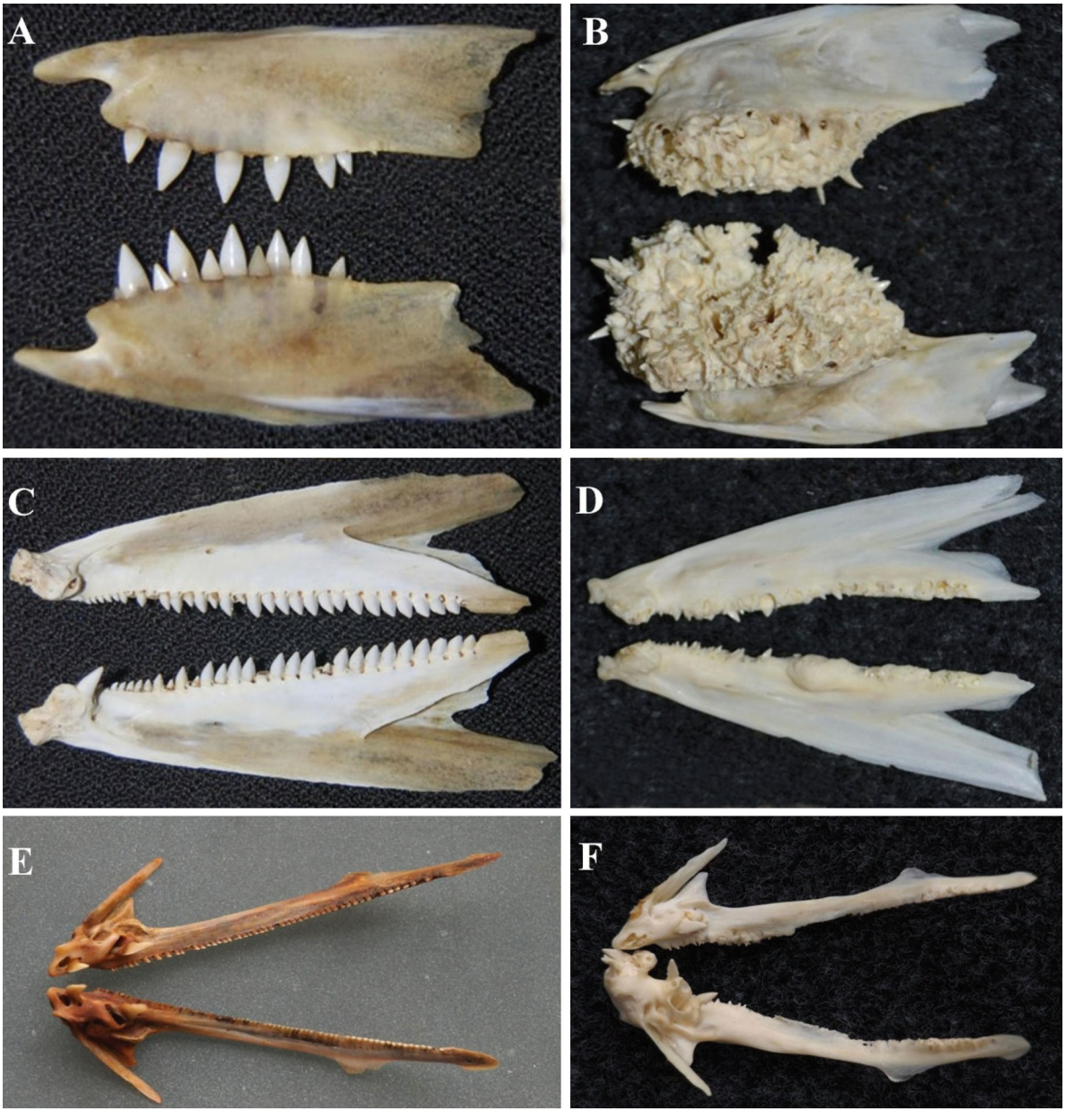

Fig. 6. *Sphyraena jello.* Skeletal structure. (A) Normal supramaxilla, (B) odontomatous supramaxilla, (C) normal dentary bone, (D) odontomatous dentary bone, (E) normal premaxilla, (F) odontomatous premaxilla

Baltic cod *Godus morhua* (Jensen & Bloch 1980) and common dab *Limanda limanda* (Bloch et al. 1986), and in both cases, virus-like particles were associated with epidermal hyperplasia and papillomas. Seventeen types of retroviruses or retrovirus-like particles were reported from fishes, of which 10 types were associated with skin tumour and one with granuloma (Moser et al. 1986).

Among naturally occurring fish tumours, epidermal hyperplasia and papilloma are most frequently observed as the result of mechanical damage and/or parasitic encystment (Nigrelli 1948, Schlumberger 1953, McQueen et al. 1973, Peters & Watermann 1979). The TEM analysis of the odontomas from *S. jello* clearly showed associated virus-like particles which might be the cause of tumours. Molecular analytical techniques provide new tools for studying the role of viruses with respect to seasonal changes in tumour prevalence (Bowser et al. 1996), but further research is needed to confirm the causative agent for tumours in *S. jello*.

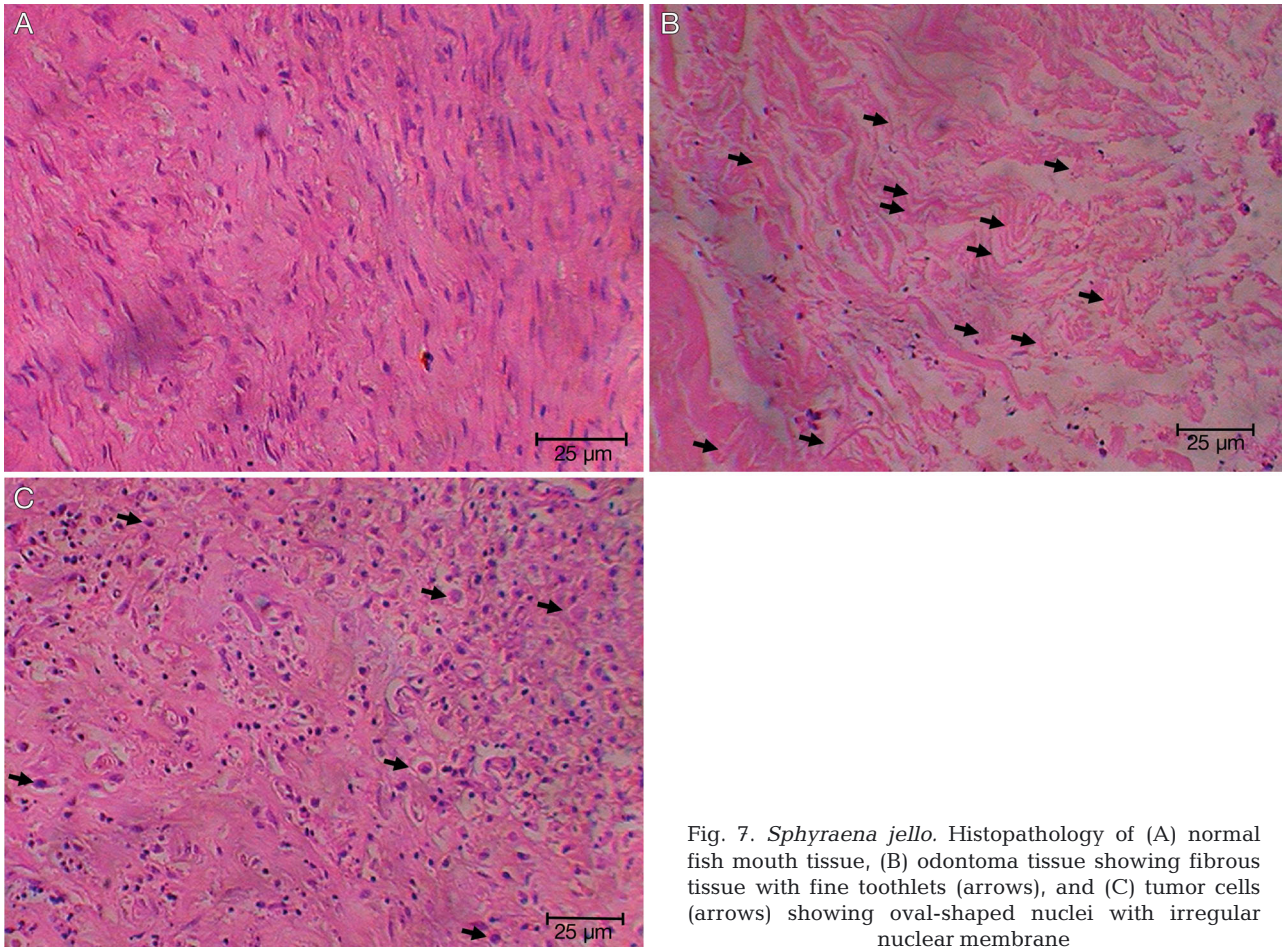

Fig. 7. *Sphyraena jello.* Histopathology of (A) normal fish mouth tissue, (B) odontoma tissue showing fibrous tissue with fine toothlets (arrows), and (C) tumor cells (arrows) showing oval-shaped nuclei with irregular nuclear membrane

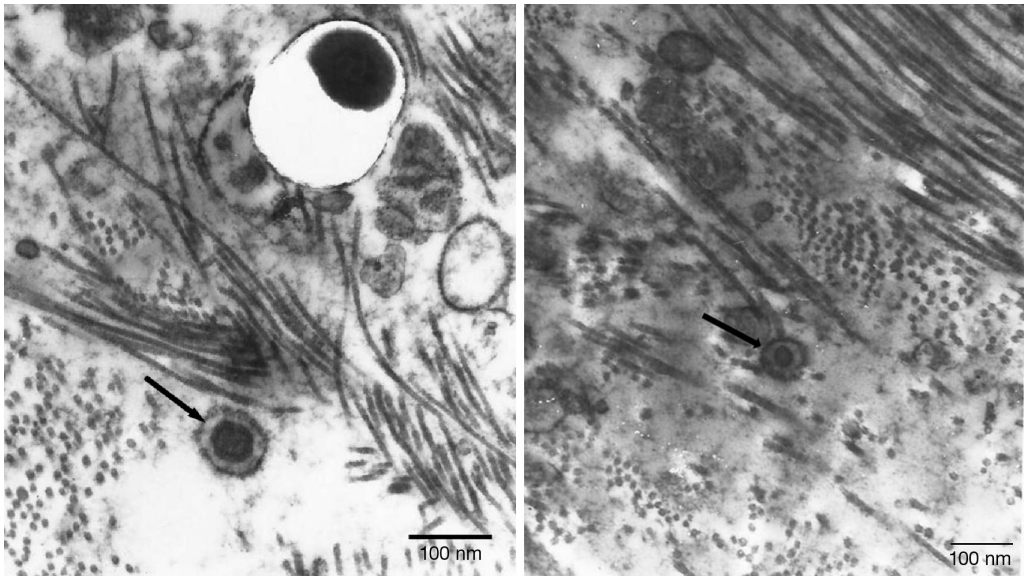

Fig. 8. *Sphyraena jello.* TEM image of odontoma tissue fragment showing virus-like particles (arrows)

Acknowledgements. The authors thank the fishers of Cuddalore, Parangipettai, and Nagapattinam for allowing us to examine their catches both on board ship and in the sorting shed. We also express our gratitude to the University Grants commission, Government of India, New Delhi, for financial support under Major Research Project (MRP) F.No-39-569/2010 (to S.R.)

LITERATURE CITED

Bloch B, Mellergaard S, Nielsen E (1986) Adenovirus-like particles associated with epithelial hyperplasias in dab, *Limanda limanda*. J Fish Dis 9:281–285

Bordini J Jr, Contar CM, Sarot JR, Fernandes A, Machado MA (2008) Multiple compound odontomas in the jaw: case report and analysis of the literature. J Oral Maxillofac Surg 66:2617–2620

Bowser PR, Wooster GA, Quackenbush SL, Casey RN, Casey JW (1996) Comparison of fall and spring tumors as inocula for experimental transmission of walleye dermal sarcoma. J Aquat Anim Health 8:78–81

Budd J, Roberts RJ (1978) Neoplasia of teleosts. In: Roberts RJ (ed) Fish pathology. Bailliere Tindall, London, p 105–113

Coolidge B, Howard RM (1979) Animal histology procedures of the Pathological Technology Section of the National Cancer Institute, 2nd edn. Natl Inst Health Publ No. 80-275

De Bruin GHP, Russell BC, Bogusch A (1995) The marine fishery resources of Sri Lanka, 2nd edn. FAO species identification field guide for fishery purposes. FAO, Rome

Daszak P, Cunningham AA, Hyatt AD (2000) Emerging infectious diseases of wildlife: threats to biodiversity and human health. Science 287:443–449

Freed LA, Cann RL, Goff ML, Kuntz WA, Bodner GR (2005) Increase in avian malaria at upper elevation in Hawai'i. Condor 107:753–764

Gopalakrishnan A, Maran BAV, Puvanendran V, Rajkumar M, Balasubramanian T, Ferguson HW (2011) Neoplasia in the Indian oil sardine, *Sardinella longiceps* (Valenciennes), and the great barracuda, *Sphyraena barracuda* (Edwards), from the south-east coast of India. J Fish Dis 34:881–885

Grabda J (1991) Marine fish pathology, an outline. PWN Polish Science Publishers, Warsaw

Harshbarger JC (1974) Activities report of the Registry of Tumours in Lower Animals, 1965–1973. Smithsonian Institution, Washington, DC

Harshbarger JC (1977) Role of the Registry of Tumors in Lower Animals in the study of environmental carcinogenesis in aquatic animals. Ann NY Acad Sci 298:280–289

Hays MA, Ferguson HA (1989) Neoplasia in fish. In: Ferguson HA (ed) Systemic pathology of fish: a text and atlas of comparative tissue responses in disease of teleosts. Iowa State University Press, Ames, IA, p 230–247

Hedrick RP, Sano T (1989) Herpesviruses of fishes. In: Ahne W, Kurstak E (eds) Viruses of lower vertebrates. Springer, Berlin, p 161–170

Jensen NJ, Bloch B (1980) Adenovirus-like particles associated with epidermal hyperplasia in cod *Gadus morhua*. Nord Vet Med 32:173–175

Keysselitz G (1908) Über ein Epithelioma der Barben. Arch Protistenkd 11:326–333

Lakshmanaperumalsamy R, Chandramohan D, Natarajan R (1976) On the occurrence of osteoma in a marine catfish. Curr Sci 45:592–594

Martineau D, Ferguson HW (2006) Neoplasia. In: Ferguson HW (ed) Systemic pathology of fish, 2nd edn. Scotian Press, London, p 313–335

Mawdesley-Thomas LE (1975) Neoplasia in fish. In: Ribelin WE, Migaki G (eds) The pathology of fishes. University of Wisconsin Press, Ithaca, WI, p 805–870

McQueen A, MacKenzie K, Roberts RJ, Young H (1973) Studies on the skin of plaice (*Pleuronectes platessa* L). III. The effect of temperature on the inflammatory response to the metacercariae of *Cryptocotyle lingua* (Creplin, 1825) (Digenea: Heterophyidae). J Fish Biol 5: 241–247

Moser M, Jensen LA, Heckmann RA (1986) Lesion on sablefish (*Anoplopoma fimbria*) of possible viral and bacterial origin. Trans Am Microsc Soc 105:185–186

Nigrelli RF (1948) Prickle cell hyperplasia in the snout of the redhorse sucker (*Moxostoma aureolum*) associated with an infection by the myxosporidian *Myxobolus moxostomia*. Nov Zoologica 33:43–46

Peters N, Watermann B (1979) Three types of skin papillomas of flatfishes and their causes. Mar Ecol Prog Ser 1: 269–276

Poulin R (2006) Global warming and temperature-mediated increases in cercarial emergence in trematode parasites. Parasitology 132:143–151

Rao KS, Rao KVSJ (1979) A case report of epidermal tumours on a marine teleost, *Johnius* (*Johnieops*) *aneus* (Bloch) from the waters off Visakhapatnam. Curr Sci 48: 417–418

Roberts RJ (1989) Fish pathology. Baillier Tindall, London

Sano T, Morita N, Shima N, Akimoto M (1991) *Herpesvirus cyprini*: lethality and oncogenicity. J Fish Dis 14:533–543

Sarkar HL, Datta Chaudhuri R (1953) On the occurrence of an epidermal papilloma in *Anabas testudineus* (Bloch). J Indian Med Assoc 22:152–154

Schlumberger HG (1953) Comparative pathology of oral neoplasms. Oral Surg 6:1078–1094

Schlumberger HG, Katz M (1956) Odontogenic tumours of salmon. Cancer Res 16:369–370

Schlumberger HG, Lucke B (1948) Tumors of fishes, amphibians and reptiles. Cancer Res 8:657–754

Serra-Serra G, Berini-Aytés L, Gay-Escoda C (2009) Erupted odontomas: a report of three cases and review of the literature. Med Oral Patol Oral Cir Bucal 14:E299–E303

Sinderman C (1990) Principal diseases of marine fish and shellfish, Vol 1, 2nd edn. Academic Press, San Diego, CA

Smith KF, Sax DF, Lafferty KD (2006) Evidence for the role of infectious disease in species extinction and endangerment. Conserv Biol 20:1349–1357

Stolk A (1957) Tumours in fishes. XIX. Odontogenic tumour in the oviparous cyprinodont *Cyprinodon variegates variegatus* Lacepede. Verh K Ned Akad Wet Ser C Biol Med Wet 60:658–665

Thomas L (1926) Epithelioma odontoblastique des maxillaires chez une morue. Bull Assoc Fr Etud Cancer 15: 464–470

Woodhams DC, Alford RA, Briggs CJ, Johnson M, Rollins-Smith LA (2008) Life-history trade-offs influence disease in changing climates: strategies of an amphibian pathogen. Ecology 89:1627–1639

Yevich PP, Barszcz CA (1983) Histopathology as a monitor for marine pollution. Results of the histopathologic examination of the animals collected for the 1976 Mussel Watch Program. Rapp P-V Reun Cons Int Explor Mer 182:96–102

Editorial responsibility: Thomas Braunbeck, Heidelberg, Germany

Submitted: February 27, 2013; Accepted: October 24, 2013
Proofs received from author(s): January 28, 2014