Vol. 125: 243–247, 2017
https://doi.org/10.3354/dao03148

DISEASES OF AQUATIC ORGANISMS
Dis Aquat Org

Published August 9

NOTE

First report of cutaneous infiltrative lipoma in goldfish *Carassius auratus*

Neeraj Sood[1], T. Raja Swaminathan[2,*], Manoj K. Yadav[1], Pravata K. Pradhan[1], Raj Kumar[2], Naresh Kumar Sood[3]

[1]ICAR-National Bureau of Fish Genetic Resources, Canal Ring Road, PO Dilkusha, Lucknow, Uttar Pradesh 226002, India
[2]Peninsular and Marine Fish Genetic Resources Centre, ICAR-NBFGR, CMFRI Campus, PO Number 1603, Kochi, Kerala 682018, India
[3]Guru Angad Dev Veterinary and Animal Sciences University, Ludhiana Road, A Block, Aggar Nagar, Ludhiana, Punjab 141012, India

ABSTRACT: Goldfish *Carassius auratus* is the most popular ornamental species, widely present in private and public aquaria. In the present case, 2 goldfish exhibited bilateral, multiple, variably sized, round, pale-white, soft, protruding masses on the body. The microscopic examination of the masses revealed well-differentiated adipocytes infiltrating the subcutaneous skeletal muscle bundles. The histological lesions were consistent with infiltrative lipoma. To our knowledge, this is the first report of cutaneous infiltrative lipoma in goldfish.

KEY WORDS: Goldfish · Histopathology · Lipoma · Neoplasm

INTRODUCTION

The goldfish *Carassius auratus*, a freshwater fish belonging to the family Cyprinidae, is native to East Asia (Lelek 1987), including China and neighbouring countries. It inhabits rivers, lakes, reservoirs, ponds and ditches with stagnant and slow flowing water (Etnier & Starnes 1993). The goldfish was one of the earliest finfish species to be domesticated and is one of the most popular ornamental species due to its diverse characteristics, viz. colour, body shape, size and fin features (Rylková et al. 2010). Importantly, the fish is quite tolerant to environmental conditions, viz. wide temperature range, high water turbidity and low dissolved oxygen (Balon 2004).

The susceptibility of teleosts to developing neoplasms is similar to that observed in higher vertebrates and there are a number of reports of neoplasms in freshwater as well as marine fish species (Hayes & Ferguson 1989). The tumours may arise from any tissue of the fish but occur more frequently in skin, gills, liver and gut, as these are more exposed to environmental contaminants (Roberts 2012). Lipomas are benign mesenchymal tumours of the adipose tissue, which can develop in almost all the organs of the body containing fat (Moussa et al. 2013), and therefore are also known as universal or ubiquitous tumours (Cicconetti et al. 2010). Lipomas are the most common soft tissue tumours (Murphey et al. 2004), reported frequently in humans and dogs (Pakhrin et al. 2007). These tumours have also been reported in freshwater and marine fish (Marino et al. 2011), but are rather rare in fish (Easa et al. 1989b, De Stefano et al. 2012). Further, the lipomas are subclassified into classic lipoma, fibrolipoma, angiolipoma, infiltrative lipoma, hibernoma, etc., according to their histologic features and growth pattern (Salvatore et al. 2003). Of these, the infiltrative lipoma is a rare variant that characteristically infiltrates adjacent tissues and tends to recur after excision (Colella et al.

*Corresponding author: rajathanga@yahoo.co.in

2004). Infiltrative lipomas have been mostly reported in humans (Çalisaneller et al. 2009, Han et al. 2014) and dogs (Hobert et al. 2013, Briand et al. 2015), but occasionally occur in horses (Erkert et al. 2007), cattle (Sickinger et al. 2009, Agerholm et al. 2016), cats (Esplin 1984) and lambs (Azizi et al. 2011). These tumours have also been reported in a few finfish species such as sand flathead *Platycephalus bassensis* (Hard et al. 1979), channel catfish *Ictalurus punctatus* (McCoy et al. 1985), tuna *Thunnus maccoyii* (Johnston et al. 2008) and seabass *Dicentrarchus labrax* (Marino et al. 2011).

Here, we describe spontaneously occurring infiltrative lipomas in 2 adult *C. auratus*, which seems to be the first report of this tumour in goldfish.

MATERIALS AND METHODS

During April 2016, 2 goldfish *Carassius auratus* (body weight: 70 to 75 g; total length: 15 to 16 cm; about 18 mo old) exhibiting multiple growths on their skin were brought to the Peninsular and Marine Fish Genetic Resources Centre of ICAR-National Bureau of Fish Genetic Resources from a farm in Kerala, South India. The affected fish showed normal activity and appetite. As per the farmer's information, the goldfish were being cultured in 4 cemented tanks (1 × 1 × 1 m each) at a density of 100 fish per tank. The fish were fed twice daily with commercial fish feed (Carpmax from Growel; crude protein 37 to 38%, fat 7 to 8% and crude fibre 7.5%) at 2 to 3% of body weight. About 50% of the water in the tanks was exchanged daily. In the laboratory, the fish were euthanized with an overdose of MS222 (Sigma-Aldrich) and necropsy was conducted to record the gross lesions. Routine parasitological and bacteriological investigation of the tumour masses was carried out. For parasitological examination, wet mounts were prepared from the scrapings taken from the surface of the tumour masses and examined under the microscope, whereas for bacteriological examination, the surface of the protruding mass was disinfected and an inoculation loop was inserted deep into the mass and streaked on nutrient agar.

Subsequently, virus isolation was attempted from cutaneous masses of each goldfish. Briefly, the tissue homogenate prepared from the masses was collected aseptically and inoculated in goldfish fin (GFF) cell line, using standard protocol (Swaminathan et al. 2016). The inoculated cells were observed for development of cytopathic effects up to 10 d. A total of 5 blind passages from inoculated cells were made at an interval of 10 d each. In addition, 2 cutaneous masses from each fish along with internal organs viz. spleen, kidney and liver were collected in 10% neutral buffered formalin and routinely processed for paraffin embedding. The tissue sections (5 µm thickness) were cut and stained with haematoxylin and eosin (H&E).

RESULTS

There were bilateral, multiple, pale-white, soft masses of varying sizes on the dorso-lateral and flank region as well as at the base of the pectoral fin of the affected goldfish (Fig. 1). The masses protruded from the surface and were almost spherical. The cut surface was whitish and lardaceous in appearance. Routine examination of wet mounts prepared from the surface and the area around the masses did not reveal the presence of any parasite. Moreover, no bacteria could be isolated from the protruding masses during bacteriological investigation. Further-



Fig. 1. Multiple, variably sized, pale-white masses on the skin of the 2 affected goldfish

more, during post-mortem, no gross lesions were observed in any of the organs, namely liver, spleen and kidney.

In the GFF cell line, no cytopathic effects were observed following inoculation of tissue homogenates, even after 5 blind passages. Microscopically, the tumour masses consisted of mature, fully differentiated adipocytes of varying size, which were round to polyhedral in appearance. The adipocytes had a large, single locule of fat, peripheral flat nuclei and clear cell margins. The adipocytes were seen infiltrating the subcutaneous muscle bundles, resulting in disruption as well as mild hyaline degeneration and necrosis, along with mild interstitial inflammation and focal fibroplasia (Fig. 2). However, the tumours were neither encapsulated nor circumscribed and, importantly, no typical features suggestive of malignancy such as cellular and nuclear pleomorphism or atypia or anaplasia were recorded. The histological lesions were similar in all the examined masses. Based on the characteristic gross and histological features and absence of anaplasia, the tumour masses were identified as cutaneous infiltrative lipomas. The internal organs viz. spleen, kidney and liver did not show any remarkable histopathological alteration.

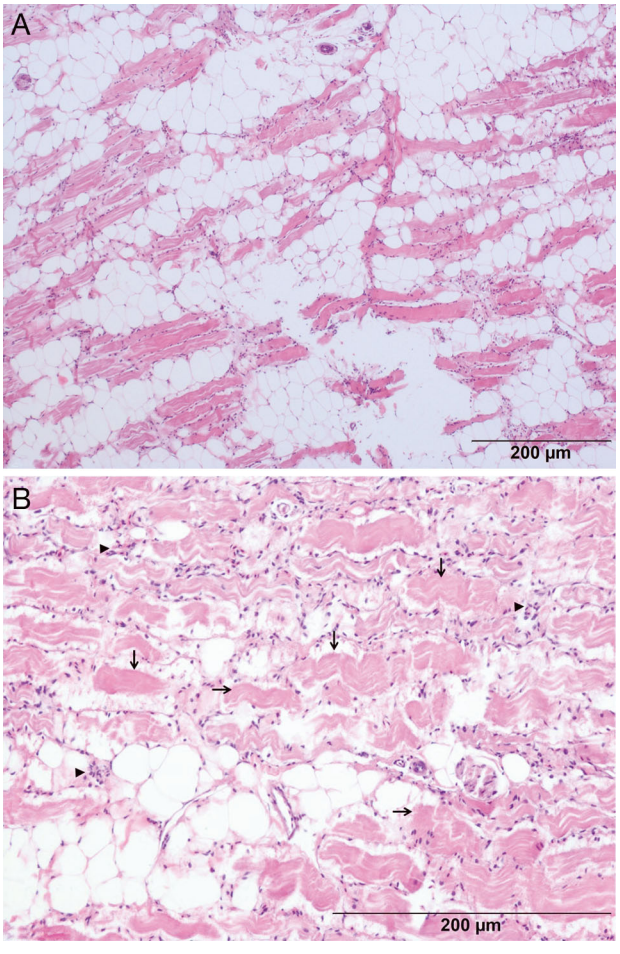

Fig. 2. (A) Histological section of the mass showing mature adipocytes disrupting the muscle bundles, leading to their atrophy. (B) A higher magnification of the mass showing well-differentiated adipocytes infiltrating the muscle fibres, which appear to be undergoing hyaline degeneration (arrows). Mild inflammatory reaction is evident (arrowheads)

DISCUSSION

Tumours in fish have been reported in almost all the organs, as in higher animals and mammals (Ferguson 1989). However, teleosts mainly develop mesenchymal tumours (Mawdesley-Thomas 1972), whereas higher vertebrates more commonly develop tumours of ectodermal or endodermal origin (Marino et al. 2006). Among mesenchymal tumours, lipomas are the most common type of soft tissue tumour (McTighe & Chernev 2014). Interestingly, lipomas are localised nodules of fat with otherwise normal appearance (Yager & Scott 1985), and a lipoma is indistinguishable from normal adipose tissue histologically as well as chemically. However, the fat present in lipomas is unavailable to the body during starvation, as lipomas are metabolically inactive (Epivatianos et al. 2000). Lipomas have been reported in most domestic animals (Goldschmidt & Hendrick 2002), but they are relatively uncommon in fish (Marino et al. 2011, De Stefano et al. 2012) and, to date, 84 cases of lipoma affecting 53 species of fish have been listed by the Registry of Tumors in Lower Animals (J. Wolf pers. comm.). These include *Thunnus maccoyii* (Lester & Kelly 1983, Johnston et al. 2008), *Ictalurus punctatus* (McCoy et al. 1985), *Anguilla anguilla* (Easa et al. 1989a), *Mugil cephalus* (Easa et al. 1989b), *Limanda limanda* (Bruno et al. 1991), *Lithognathus mormyrus* (Volpatti et al. 1998), *Thunnus thynnus* (Marino et al. 2006), *Dicentrarchus labrax* (Marino et al. 2011) and *Poecilia velifera* (De Stefano et al. 2012).

In the present study, multiple tumours that were soft and nearly round were observed in the affected goldfish. In earlier reports, lipomas have been observed as single or multiple well-circumscribed masses, which grew to very big size (up to 20 kg) in a few cases (Easa et al. 1989b, Roberts 2012). Moreover, similar tumours have been reported to be soft with their cut surfaces appearing greasy to the touch (Roberts 2012), as was also observed in the present case.

Histologically, the adipocytes were found infiltrating the muscle fibres, resulting in disruption, atrophy and degeneration of muscle fibres. The tumours were neither encapsulated nor circumscribed. Based on the histological findings, the tumours were classified as infiltrative lipomas. Previously, there have been reports of infiltrative lipomas in a few fish species (Hard et al. 1979, McCoy et al. 1985, Johnston et al. 2008, Marino et al. 2011). Our findings are in accordance with earlier reports that infiltrative lipomas are characterized by sheets of adipocytes between the skeletal muscle and fascia (Yager & Wilcock 1994). Moreover, these tumours are reported to be poorly circumscribed with minimal stromal fibrous tissue and lack of encapsulation (Sickinger et al. 2009). As observed in the present study, infiltrative lipomas are benign and composed of well-differentiated adipocytes lacking cellular and nuclear pleomorphism or anaplasia (Yager & Wilcock 1994). By definition, a lipoma is considered benign, whereas an infiltrative characteristic suggests somewhat malignant behaviour as these infiltrative lipomas are locally invasive and reoccurrence after surgical excision is quite common (Saik et al. 1987, Sickinger et al. 2009). Therefore, Saik et al. (1987) suggested that infiltrative lipomas should be classified as well-differentiated liposarcomas. However, the infiltrative lipomas can be differentiated from liposarcomas by the absence of multivacuolated lipoblasts, cellular and nuclear pleomorphism, mitotic activity and multinucleated giant cells (Çalisaneller et al. 2009).

The etiology of infiltrative lipomas is still unknown. It is unclear why some of the lipomas develop locally invasive attributes and form an infiltrative lipoma. It has been suggested that congenital infiltrative lipomas may arise due to developmental disorders (Di Giancamillo et al. 2002, Sickinger et al. 2009, Azizi et al. 2011, Agerholm et al. 2016). However, for infiltrative lipomas developing at a later age, a number of factors viz. metaplasia, trauma, chronic irritation, genetic predisposition and endocrine dysfunctions may play an important role (McTighe & Chernev 2014). In addition, a role of aberrant high-mobility group proteins in the development of infiltrative lipomas is also suggested (Tallini et al. 1997). Although various chromosomal alterations have been described in human neoplasms of adipocyte origin (Bartuma et al. 2008), such abnormalities have not yet been described in adipose neoplasms of domestic animals.

In the present study, infectious etiology was not suspected as no parasites were observed in wet mounts and tissue sections of tumour masses. Similarly, bacteria could not be isolated from the masses or demonstrated in tissue sections. Furthermore, virus involvement was not suspected as cytopathic effects were not observed in the inoculated cell line. Therefore, in the present case, genetic predisposition seems to be the probable reason for lipoma occurrence in 2 fish in the same tank. However, in earlier studies, dysmetabolic syndrome has been suggested to be the starting point for lipoma formation in aquarium as well as farmed fish (Marino et al. 2011, De Stefano et al. 2012). In the affected goldfish, the neoplasms were not responsible for any physiological disturbance of the goldfish and did not hinder normal activity of the fish. To our knowledge, this is the first report of cutaneous infiltrative lipoma from goldfish.

Acknowledgements. The authors thank the Director of ICAR-NBFGR and the Deputy Director General (Fishery Science) of ICAR for support, guidance and encouragement. The financial support from the National Fisheries Development Board, DADF, Ministry of Agriculture and Farmers Welfare under NSPAAD is thankfully acknowledged. The authors also thank anonymous reviewers for their constructive comments, which helped to improve the manuscript.

LITERATURE CITED

Agerholm JS, McEvoy FJ, Goldschmidt MH (2016) Congenital infiltrative lipomas and retroperitoneal perirenal lipomas in a calf. Acta Vet Scand 58:19

Azizi S, Kheirandish R, Namjoo AR (2011) Occurrence of infiltrative lipoma with remarkable abomasal ulcers in a lamb - a case report. Vet Arh 81:683–690

Balon EK (2004) About the oldest domesticates among fishes. J Fish Biol 65(Suppl A):1–27

Bartuma H, Domanski HA, Von Steyern FV (2008) Cytogenetic and molecular cytogenetic findings in lipoblastoma. Cancer Genet Cytogenet 183:60–63

Briand Q, Livet V, Fau D, Cabon Q (2015) Infiltrative retroperitoneal lipoma in a Labrador retriever. Rev Med Vet 166:148–153

Bruno DW, McVicar AH, Fraser CO (1991) Multiple lipoma in the common dab, *Limanda limanda* L. J Appl Ichthyol 7:238–243

Çalisaneller T, Özdemir Ö, Kiyici H, Karadeli E (2009) Paraspinal infiltrative lipoma complicated with paravertebral abscess in a chronic renal failure patient. Marmara Med J 22:150–154

Cicconetti A, Guttadauro A, Mascioli PA (2010) Rapidly growing infiltrating lipoma of the oral cavity and the mental region. Oral Surg 3:140–142

Colella G, Lanza A, Rossiello L, Rossiello R (2004) Infiltrating lipoma of the tongue. Oral Oncol Extra 40:33–35

De Stefano C, Bonfiglio R, Montalbano G, Giorgianni P, Lanteri G (2012) Multicentric lipoma in a molly (*Poecilia velifera*). Bull Eur Assoc Fish Pathol 32:220–224

Di Giancamillo M, Lombardo R, Beretta S, Pravettoni D, Cipone M, Scanziani E, Belloli A (2002) Congenital facial infiltrative lipoma in a calf. Vet Radiol Ultrasound 43: 46–49

Easa MES, Faisal M, Harshbarger JC, Hetrick FM (1989a) A pseudocystic lipoma in the European eel, *Anguilla anguilla*. J Appl Ichthyol 5:85–87

Easa MES, Harshbarger JC, Hetrick FM (1989b) Hypodermal lipoma in a striped (grey) mullet, *Mugil cephalus*. Dis Aquat Org 6:157–160

Epivatianos A, Markopoulos AK, Papanayotou P (2000) Benign tumors of adipose tissue of the oral cavity: a clinicopathologic study of 13 cases. J Oral Maxillofac Surg 58:1113–1117

Erkert RS, Moll HD, Macallister CG, Confer AW, Ritchey JW (2007) Infiltrative lipoma in an American quarter horse gelding. Equine Vet Educ 19:380–383

Esplin DG (1984) Infiltrating lipoma in a cat. Feline Pract 14: 24–25

Etnier DA, Starnes WC (1993) The fishes of Tennessee. University of Tennessee Press, Knoxville, TN

Ferguson HW (1989) Common neoplasms in fish. In: Ferguson HW (ed) Systemic pathology of fish: a text and atlas of comparative tissue responses in diseases of teleosts. Iowa State University Press, Ames, IA, p 235–245

Goldschmidt MH, Hendrick MJ (2002) Tumor of the skin and soft tissue. In: Meuten DJ (ed) Tumors in domestic animals. Iowa State Press, Ames, IA, p 96–99

Han HH, Choi JY, Seo BF, Moon SH, Oh DY, Ahn ST, Rhie JW (2014) Treatment for intramuscular lipoma frequently confused with sarcoma: a 6-year retrospective study and literature review. BioMed Res Int 2014:867689

Hard GC, Williams R, Lee J (1979) Survey of demersal fish in Port Phillip Bay for incidence of neoplasia. Aust J Mar Freshwater Res 30:73–79

Hayes MA, Ferguson HW (1989) Neoplasia in fish. In: Ferguson HW (ed) Systemic pathology of fish: a text and atlas of comparative tissue responses in diseases of teleosts. Iowa State University Press, Ames, IA, p 230–247

Hobert MK, Brauer C, Dziallas P, Gerhauser I, Algermissen D, Tipold A (2013) Infiltrative lipoma compressing the spinal cord in 2 large-breed dogs. Can Vet J 54: 74–78

Johnston CJ, Deveney MR, Bayly T, Nowak BF (2008) Gross and histopathological characteristics of two lipomas and a neurofibrosarcoma detected in aquacultured southern bluefin tuna, *Thunnus maccoyii* (Castelnau), in South Australia. J Fish Dis 31:241–247

Lelek A (1987) Threatened fishes of Europe. In: European Committee for the Conservation of Nature and Natural Resources, Council of Europe (eds) The freshwater fishes of Europe, Vol 9. Aula-Verlag, Wiesbaden

Lester RJG, Kelly WR (1983) Tumour-like growths from southern Australian marine fish. Tasmanian Fish Res 25: 27–32

Marino F, Monaco S, Salvaggio A, Macri B (2006) Lipoma in a farmed northern bluefin tuna, *Thunnus thynnus* (L.). J Fish Dis 29:697–699

Marino F, Chiofalo B, Mazzullo G, Panebianco A (2011) Multicentric infiltrative lipoma in a farmed Mediterranean seabass, *Dicentrarchus labrax*: a pathological and biochemical case study. Dis Aquat Org 96:259–264

Mawdesley-Thomas LE (1972) Some tumours of fish. Symp Zool Soc Lond 30:191–283

McCoy CP, Bowser PR, Steeby J, Bleau M, Schwedler TE (1985) Lipoma in channel catfish, *Ictalurus punctatus* (Rafinesque). J Wildl Dis 21:74–76

McTighe S, Chernev I (2014) Intramuscular lipoma: a review of the literature. Orthop Rev (Pavia) 6:5618

Moussa OM, Tee M, Khan AU, Selvasekar CR (2013) Computerized tomography providing definitive diagnosis of colonic lipoma: a case series. Surg Laparosc Endosc Percutan Tech 23:e232–e234

Murphey MD, Carroll JF, Flemming DJ (2004) From the archives of the AFIP: benign musculoskeletal lipomatous lesions. Radiographics 24:1433–1466

Pakhrin B, Kang MS, Bae IH (2007) Retrospective study of canine cutaneous tumors in Korea. J Vet Sci 8:229–236

Roberts RJ (2012) Neoplasia of teleosts. In: Roberts RJ (ed) Fish pathology, 4th edn. Blackwell Publishing, Oxford, p 167–185

Rylková K, Kalous L, Šlechtová S, Bohlen J (2010) Many branches, one root: first evidence for a monophyly of the morphologically highly diverse goldfish (*Carassius auratus*). Aquaculture 302:36–41

Saik JE, Diters RW, Wortman JA (1987) Metastasis of a well-differentiated liposarcoma in a dog and a note on nomenclature of fatty tumours. J Comp Pathol 97: 369–373

Salvatore C, Antonio B, Del Vecchio W, Lanza A, Tartaro G, Giuseppe C (2003) Giant infiltrating lipoma of the face: CT and MR imaging findings. AJNR Am J Neuroradiol 24:283–286

Sickinger M, von Erichsen J, Koehler K, Doll K, Reinacher M (2009) Congenital infiltrative lipomas in a calf. J Vet Diagn Invest 21:719–721

Swaminathan TR, Kumar R, Dharmaratnam A, Basheer VS and others (2016) Emergence of carp edema virus (CEV) in cultured ornamental koi carp, *Cyprinus carpio koi*, in India. J Gen Virol 97:3392–3399

Tallini G, Dal Cin P, Rhoden KJ, Chiapetta G and others (1997) Expression of HMGI-C and HMGI(Y) in ordinary lipoma and atypical lipomatous tumors: immunohistochemical reactivity correlates with karyotypic alterations. Am J Pathol 151:37–43

Volpatti D, Patarnello P, Novelli A, D'Angelo L, Musetti R, Galeotti M (1998) Lipoma, fibrolipoma, liposarcoma in mormore, *Lithognatus mormyrus* (L.) allevate: osservazioni istologiche e ultrastrutturali. V convegno, Societa Italiana di Pathologia Ittica (SIPI), Rome

Yager JA, Scott DW (1985) The skin and appendages. In: Jubb KVF, Kennedy PC, Palmer N (eds) Pathology of domestic animals. Academic Press, London, p 407–549

Yager JA, Wilcock BP (1994) Other cutaneous mesenchymal tumors. In: Yager JA, Wilcock BP (eds) Color atlas and text of surgical pathology of the dog and cat. Wolfe Publishing, London, p 299–300

Editorial responsibility: Stephen Feist, Weymouth, UK

Submitted: December 27, 2016; Accepted: June 8, 2017
Proofs received from author(s): July 24, 2017