Vol. 129: 15–30, 2018
https://doi.org/10.3354/dao03229

DISEASES OF AQUATIC ORGANISMS
Dis Aquat Org

Published June 19

Opportunistic fungal pathogens isolated from a captive individual of the European blind cave salamander *Proteus anguinus*

Lilijana Bizjak-Mali, Polona Zalar, Martina Turk, Monika Novak Babič, Rok Kostanjšek, Nina Gunde-Cimerman*

Department of Biology, Biotechnical faculty, University of Ljubljana, Jamnikarjeva 101, 1000 Ljubljana, Slovenia

ABSTRACT: *Proteus anguinus* is a neotenic cave amphibian endemic to the Dinaric Karst and represents a symbol of Slovenian natural heritage. It is classified as 'Vulnerable' by the International Union for Conservation of Nature (IUCN) and is one of the EU priority species in need of strict protection. Due to inaccessibility of its natural underground habitat, scientific studies have been primarily conducted on *Proteus* in captivity where amphibians may be particularly susceptible to opportunistic microbial infections. In this case report, we present the results of an analysis of an individual that had been kept in captivity for 6 yr and then developed clinical symptoms, including ulcers, suggesting opportunistic microbial infection. Pigmented fungal hyphae and yeast-like cells were present in the dermis and in almost all other sampled tissues. Sampling of the ulcer allowed the isolation of a diverse array of bacterial and fungal species. We identified the water-borne, polymorphic black yeast *Exophiala salmonis*, an opportunistic pathogen of fish, as the cause of the primary infection. This is the first report on a fungal infection of *Proteus* and on cave salamanders in general.

KEY WORDS: *Proteus anguinus* · Dinaric Karst · Troglobiont · Microbial infection · *Exophiala salmonis* · *Pseudomonas*

INTRODUCTION

Amphibians are globally endangered. According to the Global Amphibian Assessment (www.pacificbio.org/initiatives/ESIN/News/global_amphibian_assessment.htm), 43% of amphibian species are in decline, while an additional 32% are threatened. Several contributing factors have been identified, including eradication, fragmentation and pollution of their natural habitats, climate change, and perturbation of natural infection cycles with microbial pathogens (Latney & Klaphake 2013).

The European blind cave salamander *Proteus anguinus* Laurenti, 1786 is an obligate cave-dwelling amphibian endemic to Dinaric Karst on the western Balkan Peninsula (Sket 1997). It is a neotenic and troglomorphic member of the Family Proteidae, an ancient group of aquatic salamanders (Bulog et al. 2000, Langecker 2000). With its unique life history, anatomy, and adaptations to subterranean life, including the absence of pigmentation, degenerate eyes, specific sensory adaptation, slow metabolism, and longevity, *Proteus* is a prime example of vertebrate troglomorphosis (Vandel 1965, Bulog et al. 2000, Hervant et al. 2001). Furthermore, *Proteus* represents a symbol of Slovenian natural heritage and is a flagship species of the subterranean environment of the Dinaric Karst (Sket 1996, Stankovič et al. 2015), a habitat recognized as a world hotspot in biodiversity of subterranean fauna (Sket 1996, 1999, 2012, Sket et al. 2004). Unlike most amphibians, *Proteus* is completely aquatic throughout life, potentially making it particularly susceptible to environmental pollution and infectious microbes. In Slovenia, *Pro-*

*Corresponding author: nina.gunde-cimerman@bf.uni-lj.si

teus has been protected by national legislation since 1922 and is currently classified as 'Vulnerable' by the International Union for Conservation of Nature (IUCN).

Proteus plays an important ecological role as the top predator of underground water systems, and its presence and health status are bioindicators of the stability of food chains and the general health of the underground ecosystem of the Dinaric Karst. It is therefore important to ensure its survival, which includes understanding its interactions with the environment and identification of potential threats.

Because of the inaccessibility of its natural habitat, scientific studies of *Proteus* depend on animals kept in captivity under controlled conditions simulating its natural environment. However, as observed in other amphibians (Carey et al. 1999, Densmore & Green 2007, Pessier 2007, de Assis et al. 2015), suboptimal artificial conditions in captivity can generate stress and decrease the immune response. Compared to free-living *Proteus,* individuals kept under semi-natural conditions in captivity (e.g. simulated natural environment or semi-natural environments) may be more susceptible to opportunistic microbial infections introduced in the aquaria via contaminated water, food, or equipment.

In this study, we present the case report of a *Proteus anguinus* individual, encoded Paa 196, which was kept in captivity for 6 yr before showing signs of an infection, seen as excessive mucus production, slimy irritation of the gills, sloughing of epithelial cells, and development of cutaneous ulcers on the ventral midline of its body. We discovered a primary infection by a black yeast followed by a mixed bacterial–fungal infection. This is the first case report of a fungal infection in any cave salamander, including *Proteus*, and includes the identification of the probable source.

MATERIALS AND METHODS

Animals, housing, and care

Animals were kept in the laboratory of the Chair of Zoology, Department of Biology, Biotechnical Faculty, University of Ljubljana, in accordance with Slovenian animal protection law. The animals were collected in their natural habitat with the approval of the Slovenian Ministry of the Environment and Spatial Planning, permit no. 35601-8/2016-4.

The *Proteus anguinus anguinus* individual (Paa 196) was obtained in September 2010 in Otavice near Ribnica, SE Slovenia. It was found in a flooded basement of a residential house at the end of the flooding season and was kept in captivity together with 3 other animals collected in June 2015 from the Planina Cave (Planina, SW Slovenia). All animals were kept in the speleological laboratory in separate tanks with filtered and aerated water at 11°C. They were fed once a week with amphipod crustaceans (*Gammarus* sp.) collected from the natural stream Dupeljščica in northern Slovenia. One-third of the water in the aquarium tank was exchanged every week with aerated, dechlorinated tap water kept in plastic canisters and aged at least 1 d prior to use. The tap water was poured into the plastic canisters via a rubber hose connected to the tap water faucet. The animals were kept in captivity for 2 mo to 6 yr prior to the onset of clinical signs of infection.

Case history

In the summer of 2015, all 4 *Proteus* individuals kept in separate tanks started to secrete excessive amounts of mucus and to slough epithelial cells, resulting in milky and turbid water. The gills appeared irritated and covered with a slime layer, and the animals became lethargic and lost appetite. Because sampling and inspection of the water showed contamination with a protozoan, malachite green (MG) (4.5 g l^{-1}) was applied daily for 2 consecutive weeks (T. Valentinčič pers. comm.) until all 4 animals appeared to recover. Five months after the MG treatment, however, the recurrence of excessive mucus secretion was observed on the gills of Paa 196. A few days later, cutaneous ulcers appeared on the ventral midline of its body. The animal was anesthetized to obtain blood samples by immersion in 1.0% tricaine methane sulfonate solution (MS222, Sigma Chemical) buffered with 0.2% sodium bicarbonate (pH 7) for 15 min and was euthanized by prolonged immersion in MS222. The body was submitted for diagnostic and pathological tests.

Pathological examination

Blood samples were taken from the heart ventricle with a heparinized syringe. Blood smears prepared on microscopic slides were air-dried and fixed in methanol followed by Giemsa staining (Presnell & Schreibmann 1997). Smears (in duplicate) were examined at 100× magnification for differential cell counts of white blood cells (WBC) and red blood cells

(RBC) (Davis et al. 2008). The coelomic cavity was opened for inspection of visceral organs, and tissues were sampled and fixed for 24 h in 10% buffered formalin (pH 7.4), then rinsed in water and stored in 70% ethanol. Intact skin and skin with ulcers, as well as liver, gills, lungs, intestine, spleen, gonads, blood vessels with nodules, and kidneys were processed for histological examination using a microwave-assisted protocol for paraffin tissue processing (Giberson & Elliott 2001) with the PELCO BioWave® system. Sections of 5–10 µm thickness were prepared using a rotary microtome (Reichert Jung 2040) and stained with Ehrlich's hematoxylin and eosin (H&E) and Masson Fontana counterstained with Kernechtrot (nuclear fast red; Kiernan 1990). Processed serial sections of all tissues were examined under light microscopy (OPTON-Axioskop, Zeiss) and photographed with a Leica DFC290 HD digital camera and Leica LAS 4 program.

Electron microscopy

For scanning electron microscopy (SEM), both the ulcerated parts of the skin and intact skin and biofilm covering the inner surface of the rubber hose providing the water for aquaria were fixed in 1% glutaraldehyde and 0.5% formaldehyde in 0.1 M cacodylate buffer, pH 7.3 at 4°C overnight. After washing of the fixative with 0.1 M cacodylate buffer, the samples were postfixed in 1% aqueous solution of OsO_4 for 1 h. Postfixed samples were dehydrated in an ascending ethanol series (30, 50, 70, 90, and 96%) and transferred into pure acetone that was gradually replaced by hexamethyldisilazane (HMDS) and allowed to air-dry overnight. Dried samples were attached to metal holders with silver paint, coated with platinum, and observed with a JEOL JSM-7500F field-emission scanning electron microscope.

Isolation of microorganisms from ulcer and intact skin of Paa 196

Before fixation, swab samples were taken from epidermal ulcer tissue in the ventral midline of the body and from intact skin on the head. Pieces of wounded tissue from the ulcer and healthy tissue from the ventral midline of the body were also taken. Swabs and tissue pieces were plated onto blood agar (BA), Sabouraud's glucose agar (SGA), and tryptone–gelatin hydrolysate–lactose (TGhL) agar. The latter 2 media were supplemented with 0.4 g of penicillin and streptomycin mixture (pen/strep; Sigma). Culture media were incubated at 15°C (all media), 25°C (only SGA, TGhL), or 30°C (only BA), and checked for microbial growth for up to 3 wk. Blood was also checked for microbial contamination. Blood samples were diluted 1:40 with sterile saline solution. Then 50 µl of the dilution were plated onto each medium and incubated at 3 different temperatures as before.

Colonies were isolated as pure cultures: fungi on malt extract agar (MEA), and bacteria on BA. The majority of isolates are preserved in the Culture Collection Ex, part of the Infrastructural Centre Mycosmo in the Department of Biology, Biotechnical Faculty, University of Ljubljana (www.ex-genebank.com).

Isolation of fungi and bacteria from aquarium water and the aquarium environment

To identify the source of the infection(s), fungi and bacteria were also isolated from different surfaces in the aquarium and from the water. Swabbed surfaces included the inner aquarium walls, the air stones in the aquarium of the diseased animal (Paa 196), as well as the containers and the plastic tubes used for storing and carrying the water. Water was sampled from the aquarium of Paa 196, from the aquarium with a healthy animal, from tap water, and from the Dupeljščica stream where the food for the animals was collected. Aliquots of the water samples (50–100 µl) were plated directly on media, or were filtered (200 ml) using 0.45 mm membrane filters (Merck, Millipore). Filters, water samples, and swabs were plated on dichloran rose bengal chloramphenicol agar (DRBC), SGA+pen/str, TGhL, and BA and incubated at 15 and 30°C.

Identification of fungi

Pure cultures of fungi were grown on MEA medium for 7 d before mechanical lysis of 1 cm^2 of mycelium for DNA extraction (van den Ende & de Hoog 1999). Fungal isolates were identified based on rDNA nucleotide sequences, as well as housekeeping genes beta tubulin and translation elongation factor 1-alpha. Amplicons were generated with the primer pairs ITS1 and ITS4 (White et al. 1990) for the ITS region, NL1 and NL4 (O'Donnell 1993) for the D1/D2 domains of 28S rDNA, Ben2a and Bt2b (Glass & Donaldson 1995) for the beta-tubulin region, and EF1-983F and EF1-2218R (Rehner & Buckley 2005)

for the translation elongation factor 1-alpha. PCR products were subsequently purified and sequenced by Microsynth AG (Balgach, Switzerland). Sequence assembly was done using FinchTV 1.4 (Geospiza, PerkinElmer) software. Sequence alignments were performed using Molecular Evolutionary Genetics Analysis (MEGA) software, version 5.0 (Tamura et al. 2011). Strains were identified with the use of the BLAST search algorithm on the NCBI website and other public databases, e.g. Westerdijk Fungal Biodiversity Institute (Utrecht, The Netherlands).

Identification of bacteria

Bacterial isolates were identified using 16S rDNA sequencing. Genomic DNA was isolated from pure bacterial cultures grown on BA plates at 30°C using PrepMan Ultra Sample Preparation Reagent (Applied Biosystems) according to the manufacturer's instructions. The 16S rRNA genes were PCR-amplified with oligonucleotide primers 27F (AGA GTT TGA TCM TGG CTC AG; Lane 1991) and 1492r (CGG TTA CCT TGT TAC GAC TT; Turner et al. 1999). The PCR mixtures (35 µl) contained 1 µl of isolated DNA, 0.45 U DreamTaq DNA polymerase (Thermo Fisher Scientific), 1× DreamTaq buffer with $MgCl_2$ (Thermo Fisher Scientific), 25 µM of each dNTP (Applied Biosystems), and 0.1 µM of each primer. The thermal profile of the reaction was as follows: 5 min denaturation at 94°C, followed by 5 cycles of 30 s at 94°C, 30 s at 60°C, and 1 min at 72°C, then 5 cycles of 30 s at 94°C, 30 s at 55°C, and 1 min at 72°C, followed by 30 cycles of 30 s at 94°C, 30 s at 50°C, and 1 min at 72°C. This was followed by a 7 min elongation step at 72°C. The PCR products were subsequently purified and sequenced by Microsynth AG (Balgach, Switzerland). The 16S rDNA sequences were aligned against DNA databases (Ribosomal Database Project-II and GenBank non-redundant nucleotide database). Identification to the genus or species level was accepted if there was a ≥97% or ≥99% match with the 16S rRNA gene sequence, respectively.

RESULTS

Gross clinical signs

Treatment of the initial protozoan infections with MG was successful in all of the individuals of *Proteus* except for individual Paa 196, in which excessive mucus secretion and irritation of the gills recurred (Fig. 1A,B). The symptoms were additionally accompanied by sloughing of the outer layers of epidermal epithelium, lethargy, loss of appetite, and 3 cutaneous ulcers. The ulcers appeared on the ventral midline of the body and had clean edges with reddened surrounding skin area, and measured 1.0–1.5 mm in diameter (Fig. 1C,D). Inspection of the internal organs of the ulcerated individual revealed that the liver had a mottled pattern due to pale regions around the surface blood vessels, and that the spleen and kidneys also appeared abnormally pale (Fig. 2A,B). Other abnormalities in the pleuroperitoneal cavity included prominent lymphoid-like tissue on the surface of the kidney (Fig. 2B), and nodules on the main blood vessels of the body cavity (Fig. 2C), as well as a foamy fatty tissue along both sides of the blood vessels (Fig. 2C).

Blood smears and differential counts

Inspection of Giemsa-stained blood smears with the light microscope showed numerous monocytes, followed in abundance by lymphocytes and neutrophils (Fig. 2D). This initial observation was supported by differential counts of leukocytes, among which monocytes were the predominant type (46%), followed by lymphocytes (29%) and neutrophils (24%). Eosinophils were much less numerous (0.8%), while basophils were not observed.

Pathology

In comparison to normal skin morphology, damage to the epidermis, dermis, and underlying tissues was observed in the ulcerated parts of the skin (Figs. 3A & 4A,B). In spite of the presence of fungal hyphae in the dermis, it retained a normal general organization (Fig. 3). Its upper layer, known as basement lamella, formed dense, orthogonally arranged sheets of collagen fibers. The intermediate layer of the dermis, or stratum laxum, consisted of loosely arranged collagen fibers surrounding the multicellular mucous glands, which can extend into more compact collagen of the innermost dermal layer, or stratum compactum (Fig. 3A). Changes in skin morphology included delamination and thinning of the epidermis at the periphery of the ulcer (Figs. 3A & 4A). The absence of epidermis at the edges of the ulcer exposed the upper layer of the dermis (Figs. 3A & 4B). The ulcer then penetrated

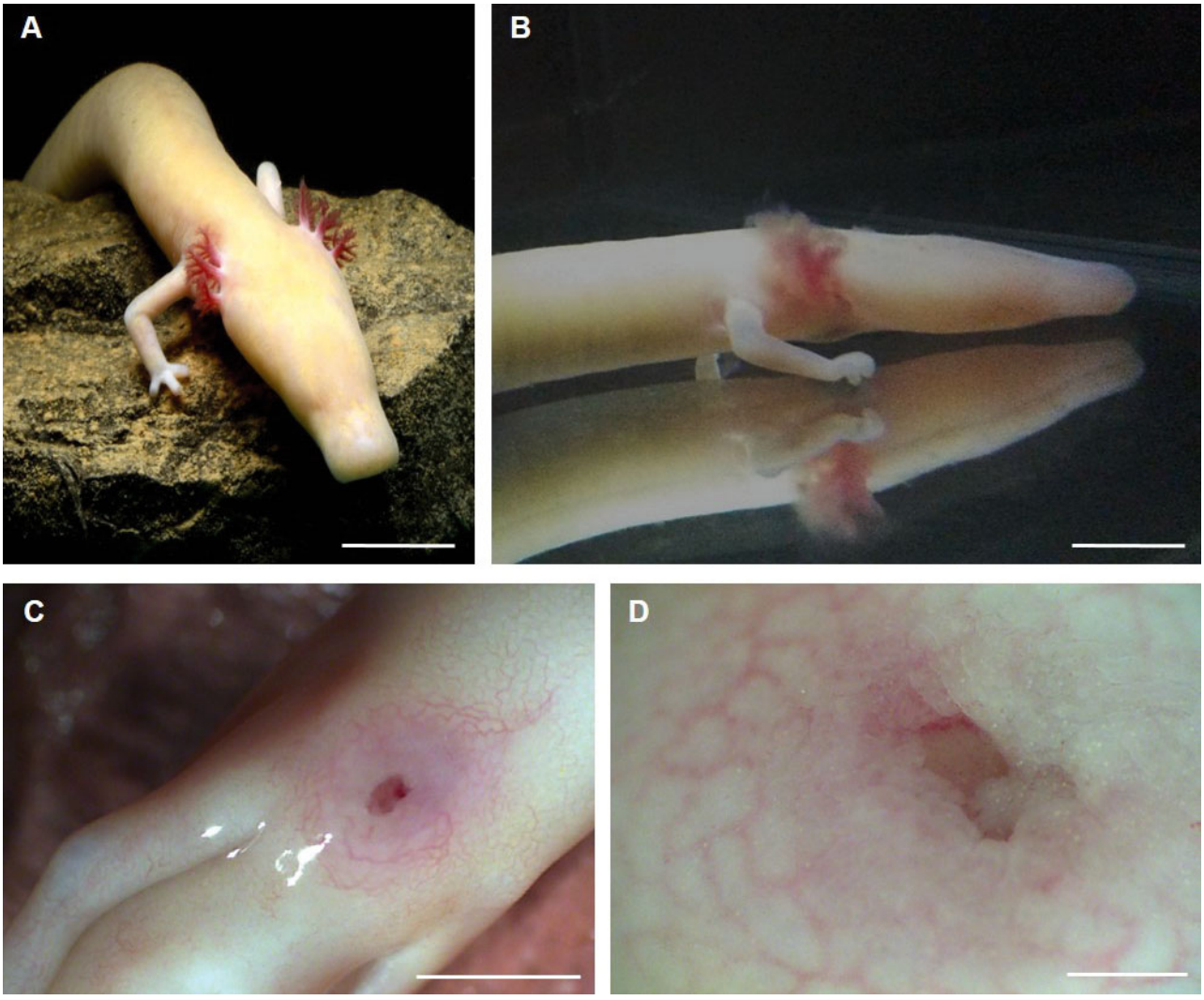

Fig. 1. (A) Healthy and (B) infected *Proteus anguinus anguinus* (Paa 196) with irritated gills covered by mucus, and (C,D) ulcer on the ventral surface of body. Scale bars = (A,B) 15 mm, (C) 5 mm, (D) 1 mm

the stratum laxum and stratum compactum and continued deep into the underlying subcutaneous and muscular tissues (Fig. 3A). In addition to degenerative changes in the tissues, the ulcers also contained dense arrangements of invasive, septated fungal hyphae with terminal swellings (Figs. 3 & 4F). Pigmented hyphae were scattered in the dermis of ulcerated and non-ulcerated parts of the skin (Fig. 4A–D), in the lumina of the multicellular mucous glands (Fig. 4E), in the subcutaneous connective tissue, and in the muscles located around the ulcers. Besides swelling and erythema of the area surrounding the ulcers (Fig. 1C,D), no other defense mechanisms, such as intense accumulations of inflammatory cells or the formation of a granuloma around hyphae, were observed. No other microorganisms, such as bacteria, protozoans, or viral particles, were observed.

Among affected internal organs, the kidneys showed the most extensive changes, including tissue disorganization, necrosis, aggregations of inflammatory cells, and dispersed distribution of septated hyphae (Fig. 5A,B). Hyphae and associated pathological changes were detected in other organs as well, but at much lower incidence. In the spleen and liver, hyphae were obscured by groups of densely packed lymphocytes (Fig. 5C,D) and clusters of pigmented cells (Fig. 5E,F), respectively. The presence of hyphae in the mucus of the gut lumen, in the epithelium of the gut mucosa, and connective tissue of submucosa (Fig. 6A,B) was accompanied by sloughing of the epithelium into the gut lumen (not

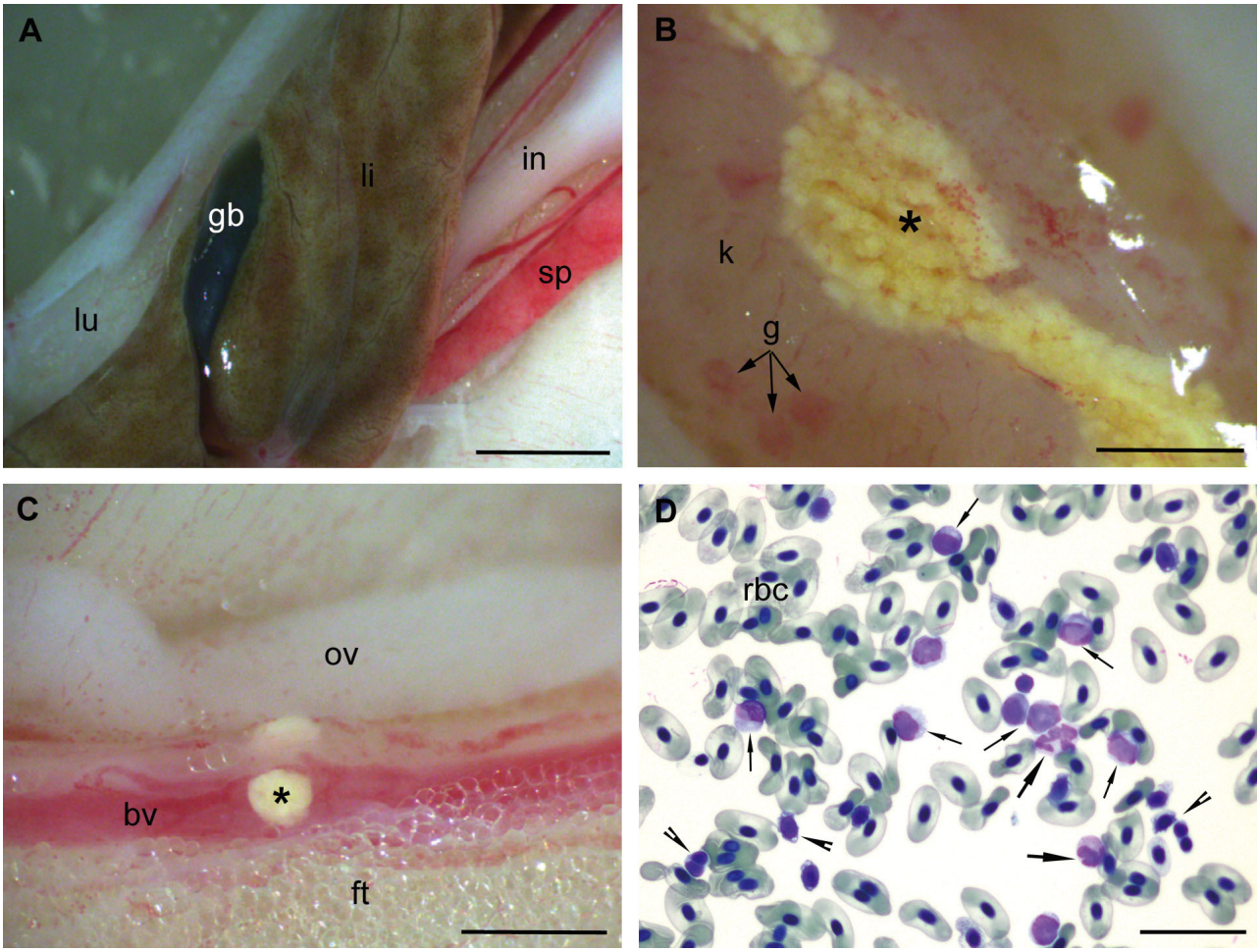

Fig. 2. Gross morphology of the visceral organs and blood smear of *Proteus anguinus anguinus* (Paa 196). (A) Liver (li) with gallbladder (gb) and spleen (sp), intestine (in), and lung (lu); (B) kidney (k) with lymphoid-like tissue (asterisk) and glomeruli (g); (C) nodule (asterisk) on the blood vessel (bv) and surrounding foamy fatty tissue (ft). ov: oviduct. (D) Giemsa staining of blood smear with monocytes (thin arrows), neutrophils (thick arrows), red blood cells (rbc), and thrombocytes (arrowheads). Scale bars = (A) 5 mm, (B,C) 1 mm, (D) 100 µm

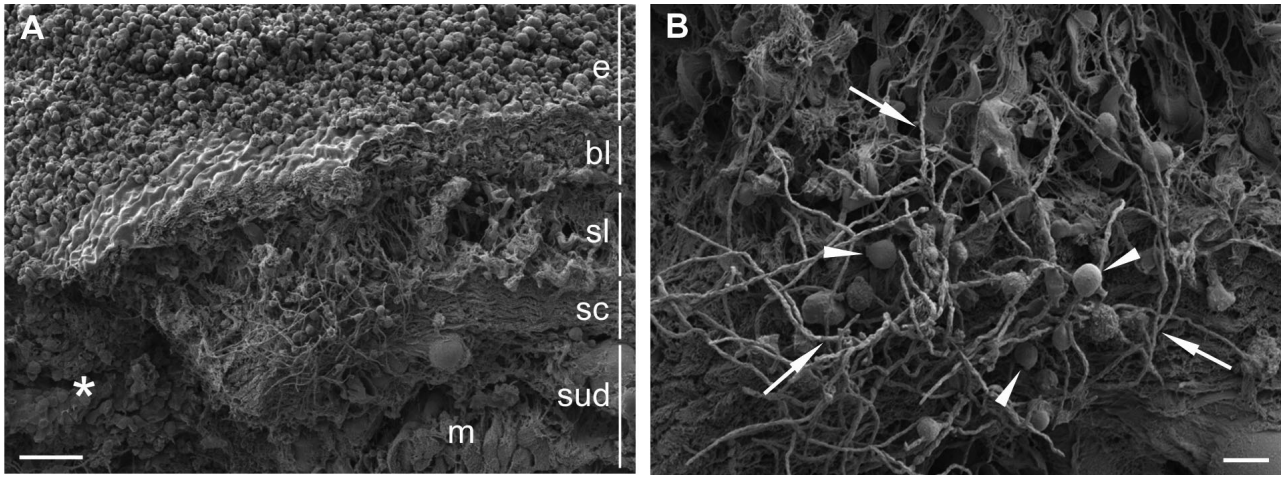

Fig. 3. Scanning electron micrographs of the skin at the ulcer site of *Proteus anguinus anguinus* (Paa 196). (A) Ulcer (asterisk) penetrating epidermis (e) and layers of the dermis (bl: basement lamella; sl: stratum laxum; sc: stratum compactum), exposing the underlying subdermal tissues (sud) and muscle fibers (m). (B) Septated fungal hyphae (arrows) and spore-like elements (arrowheads) in the dermal level of the ulcer. Scale bars = (A) 100 µm, (B) 20 µm

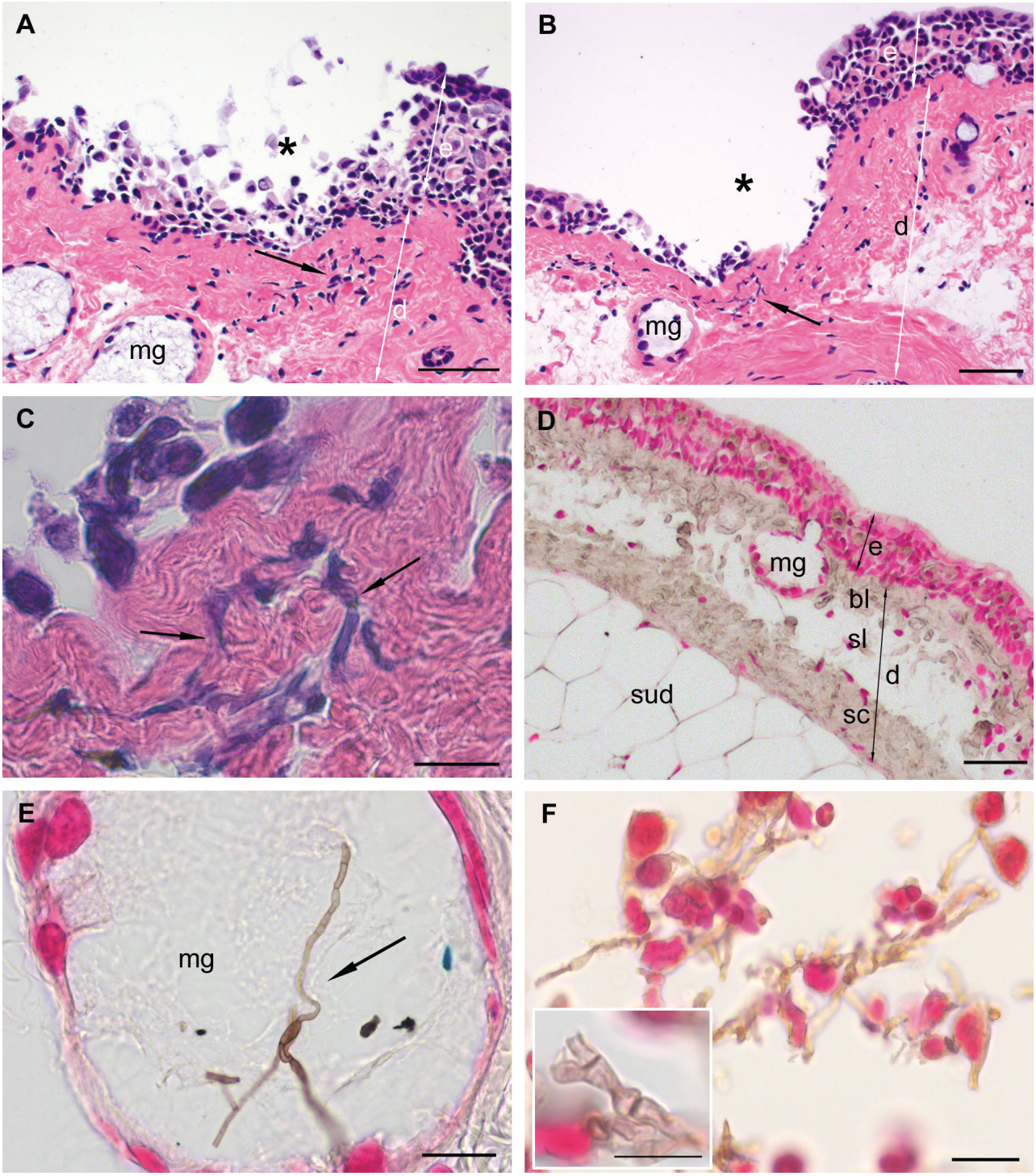

Fig. 4. Skin of *Proteus anguinus anguinus* (Paa 196). (A) Ulcer edge (asterisk) with delaminated epidermis (e) and fungal hyphae (arrow) in the dermis (d). (B) Ulcer (asterisk) with total absence of epidermis (e) and exposed upper layer of the dermis (d) with fungal hyphae (arrow). (C) Higher magnification of dermis in B with visible hyphae (arrows). (D) Non-ulcerated skin with scattered fungal hyphae (brown) in the dermis (d). bl: basement lamella; e: epidermis; mg: mucous gland; sc: stratum compactum; sl: stratum laxum; sud: subdermal adipose tissue. (E,F) Pigmented and septated fungal hyphae (brown) in the lumen of the multicellular mucous gland (mg) of (E) dermis and (F) in the lumen of the ulcer mixed with the epidermal and blood cells. Inset in (F) shows septate hyphae under higher magnification. Ehrlich's H&E staining (A–C), Masson Fontana staining counter stained with Kernechtrot (D–F). Scale bars = (A,B,D) 100 µm, (C,E,F) 20 µm, (inset in F) 10 µm

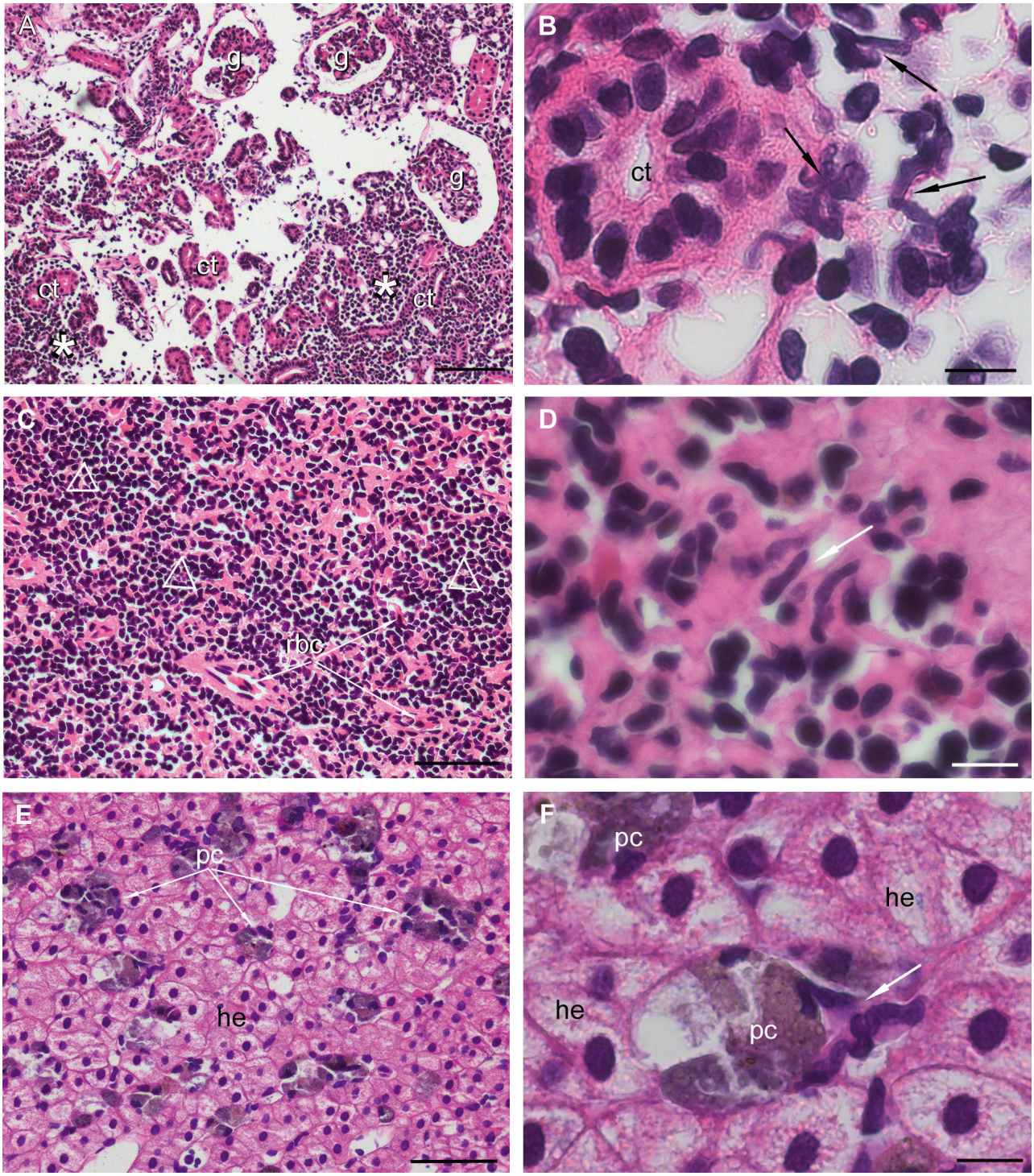

Fig. 5. Visceral organs of *Proteus anguinus anguinus* (Paa 196). Kidney with tissue degeneration and aggregation of (A) inflammatory cells (asterisks) and (B) fungal hyphae (arrows). g: glomeruli; ct: convoluted tubules. Spleen with densely packed (C) lymphocytes (triangles) and (D) fungal hyphae (arrow). Liver with (E) clusters of pigment cells (pc) between hepatocytes (he) and (F) fungal hyphae (arrow). Ehrlich's H&E staining. Scale bars = (A) 200 µm, (C,E) 100 µm, (B,D,F) 20 µm

shown). The presence of scattered hyphae in the gills and lungs was accompanied by disrupted epithelia (Fig. 6C). Finally, high densities of monocytes, neutrophils, and lymphocytes were observed in the lymph nodes along the large blood vessels of the body cavity and the blood vessels (Fig. 6D).

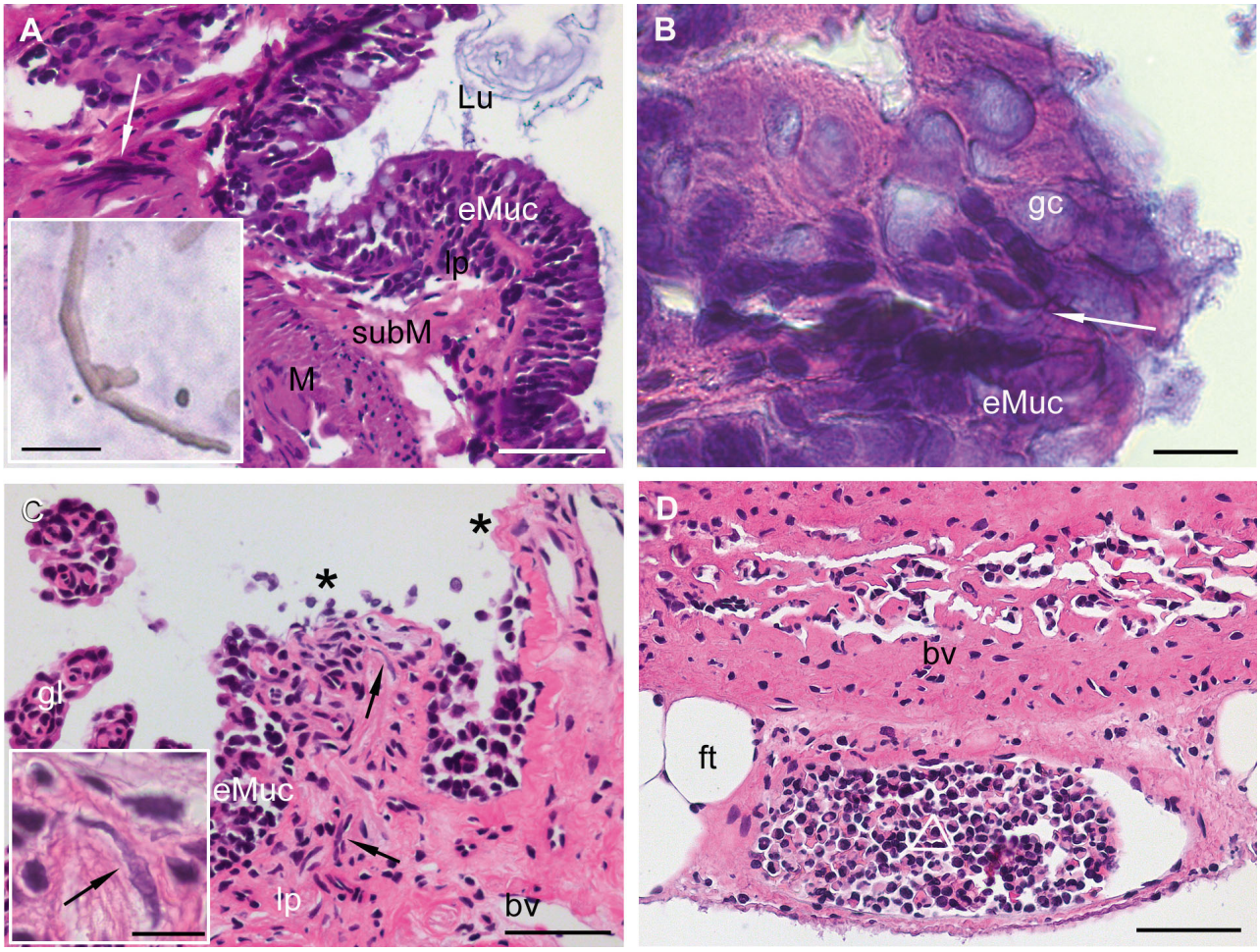

Fig. 6. Visceral organs of *Proteus anguinus anguinus* (Paa 196). Hyphae (arrows) (A) in the intestinal submucosa (inset: in the mucus of the intestinal lumen), (B) in the epithelium of mucosa, and (C) in the connective tissue of the gills (inset: in the gills under higher magnification). (D) Node on blood vessel full of inflammatory blood cells (triangle). Asterisks: disrupted epithelial tissue; bv: blood vessel; eMuc: epithelium of mucosa; ft: fat tissue; gc: goblet cells; gl: gill lamellae; lp: lamina propria of mucosa; Lu: lumen; M: muscularis externa; subM: submucosa. Ehrlich's H&E staining. Scale bars = (A,D) 100 µm, (B) 20 µm, (C) 200 µm, (insets in A,C) 10 µm

Fungi and bacteria isolated from wounded tissue

Swab sampling of the ulcer resulted in the isolation of 5 fungal strains (Table 1). The dominating species was the black yeast *Exophiala salmonis* growing at 15°C on 2 different culture media (SGA and TGhL), while *Fusicolla aquaeductuum* was represented by a single colony on SGA incubated at 15°C. Among numerous bacteria cultured from direct plating of a piece of ulcerated tissue on SGA, a few colonies of *Candida atlantica* and a single colony of *Acremonium alternatum* were initially detected, but were soon overgrown by black yeasts.

E. salmonis was identified based on 99% identity with only a single nucleotide difference from the ITS rDNA of the type strain and 100% identity in the beta tubulin gene. It grew slowly, developing melanized woolly colonies without a yeast phase (Fig. 7A), with poorly differentiated conidiogenous cells, and intercalary or flask-shaped short and inconspicuous annellides. Micromorphology observed on MEA was in accordance with the description of this species (de Hoog et al. 2011): conidia were 0–1-septated, subhyaline to pale brown, ellipsoidal to short cylindrical, and measured 5.5–8.5 × 2.0–3.5 µm (Fig. 7D,F). The cultures of *F. aquaeductuum* (Fig. 7B) and *A. alternatum* (Fig. 7C) were not melanized, but pinkish and orange in color. *F. aquaeductuum*, with hyphae ca.

3–5 µm in diameter (Fig. 7E), was similar to *Exophiala* (Fig. 7F), whereas *Acremonium* had much thinner hyphae, ca. 1 µm in diameter (Fig. 7G).

The bacterial genera *Acinetobacter*, *Pseudomonas*, and *Shewanella* were isolated from the ulcer. Most of the isolates were species in the genus *Pseudomonas*: *P. fluorescens, P. japonica, P. koreensis, P. peli, P. stutzeri*, and *Pseudomonas* sp.; followed by species of the genus *Acinetobacter*: *A. johnsonii*, *A. tjernbergiae*, and *Acinetobacter* sp. A single strain of *S. putrefaciens* was also isolated (Table 2).

Table 1. Fungal isolates from a diseased *Proteus anguinus anguinus* (Paa 196), its environment, and food sources. EXF: Culture Collection Ex; SGA: Sabouraud's glucose agar; TGhL: tryptone–gelatin hydrolysate–lactose agar; pen/strep: penicillin and streptomycin mixture; DRBC: dichloran rose bengal chloramphenicol agar; BA: blood agar

Sample/growth conditions	Genus	Species	EXF accession no.
Swab of the wound			
SGA pen/strep; 15°C	*Acremonium*	*A. alternatum*	10983
SGA pen/strep; 15°C	*Exophiala*	*E. salmonis*	10984
TGhL pen/strep; 15°C	*Exophiala*	*E. salmonis*	10985
TGhL pen/strep; 25°C	*Candida*	*C. atlantica*	10733
TGhL pen/strep; 25°C	*Fusicolla*	*F. aquaeductuum*	10734
Tap water (200 ml)			
DRBC; 30°C	*Exophiala*	*E. bergeri*	11025
SGA pen/strep; 30°C	*Exophiala*	*E. bergeri*	11035
SGA pen/strep; 30°C	*Rhinocladiella*	*R. similis*	11036
Fresh water from aquarium (200 ml)			
BA; 15°C	*Septofusidium*	*S. berolinense*	11020
DRBC; 15°C	*Lecanicillium*	*L. muscarium*	11021
DRBC; 30°C	*Stereum*	*S. hirsutum*	11026
DRBC; 30°C	*Exophiala*	*E. oligosperma*	11027
SGA pen/strep; 30°C	*Penicillium*	*P. chrysogenum*	11037
Water from aquarium after 1 wk (10 µl)			
DRBC; 15°C	*Trichosporon*	*T. moniliiforme*	11022
SGA pen/strep; 15°C	*Trichosporon*	*T. moniliiforme*	11032
DRBC; 30°C	*Aureobasidium*	*A. melanogenum*	11028
DRBC; 30°C	*Exophiala*	*E. oligosperma*	11029
Swab of rubber hose connected to the tap water supply			
DRBC; 15°C	*Cladosporium*	*C. halotolerans*	11023
SGA pen/strep; 15°C	*Cladosporium*	*C. halotolerans*	11030
DRBC; 15°C	*Exophiala*	*E. xenobiotica*	11079
SGA pen/strep; 15°C	*Exophiala*	*E. xenobiotica*	11038
SGA pen/strep; 30°C	*Exophiala*	*E. xenobiotica*	11024
Swab of plastic container for tap water storage			
SGA pen/strep; 15°C	*Cladosporium*	*C. halotolerans*	11034
SGA pen/strep; 15°C	*Cyphellophora*	*Cyphellophora* sp.	11080, 11081
SGA pen/strep; 30°C	*Ochroconis*	*O. globalis*	11039
Swab of dirty aquarium walls			
SGA pen/strep; 15°C	*Trichosporon*	*T. moniliiforme*	11033
Amphipods from Dupeljščica stream			
DRBC; 15°C	*Cladosporium*	*C. psychrotolerans*	11633
SGA pen/strep; 15°C	*Yarrowia*	*Yarrowia* sp.	11632

Fungal and bacterial species from different water sources

The black yeast *E. salmonis* was not isolated from any of the analyzed water sources. However, tap water harbored 2 other species of black yeasts, *E. bergeri* and *Rhinocladiella similis*, whereas both Dupeljščica stream water and water from the aquarium harbored *E. oligosperma*. The opportunistic pathogenic fungus *Trichosporon moniliiforme* was isolated from both the aquarium water and from swab samples of its inner walls (Table 1).

Biofilms covering the rubber hose connected to the tap water system and the interior of the plastic container used for the dechlorination of water for the aquarium were populated by the black yeast *E. xenobiotica* and the melanized fungus *Cladosporium halotolerans*, but not by *E. salmonis*. Only *C. psychrotolerans* and *Yarrowia* sp. were isolated from amphipods used as food source for the *Proteus*.

Isolation and identification of bacteria revealed that the genera *Pseudomonas* and *Acinetobacter* that prevailed in the ulcerated tissue also prevailed in the water of the aquarium of the ulcerated individual (Paa 196). *S. putrefaciens* was isolated only from the ulcer, while *Brevundimonas mediterranea* was present only on the healthy skin and in the aquarium water.

P. stutzeri, P. putida, Klebsiella oxytoca, Sphingobium sp., and *Dechloromonas* sp. were detected in the aquarium immediately after tap water was added. After 1 wk, sampling of aquarium water for bacteria was performed again and the water then also contained *Acinetobacter guillouiae* and *P. fluorescens*. These species were also present on the air stone and in the plastic container together with *Flavobacterium* sp. and *Limnobacter* sp. (Table 2).

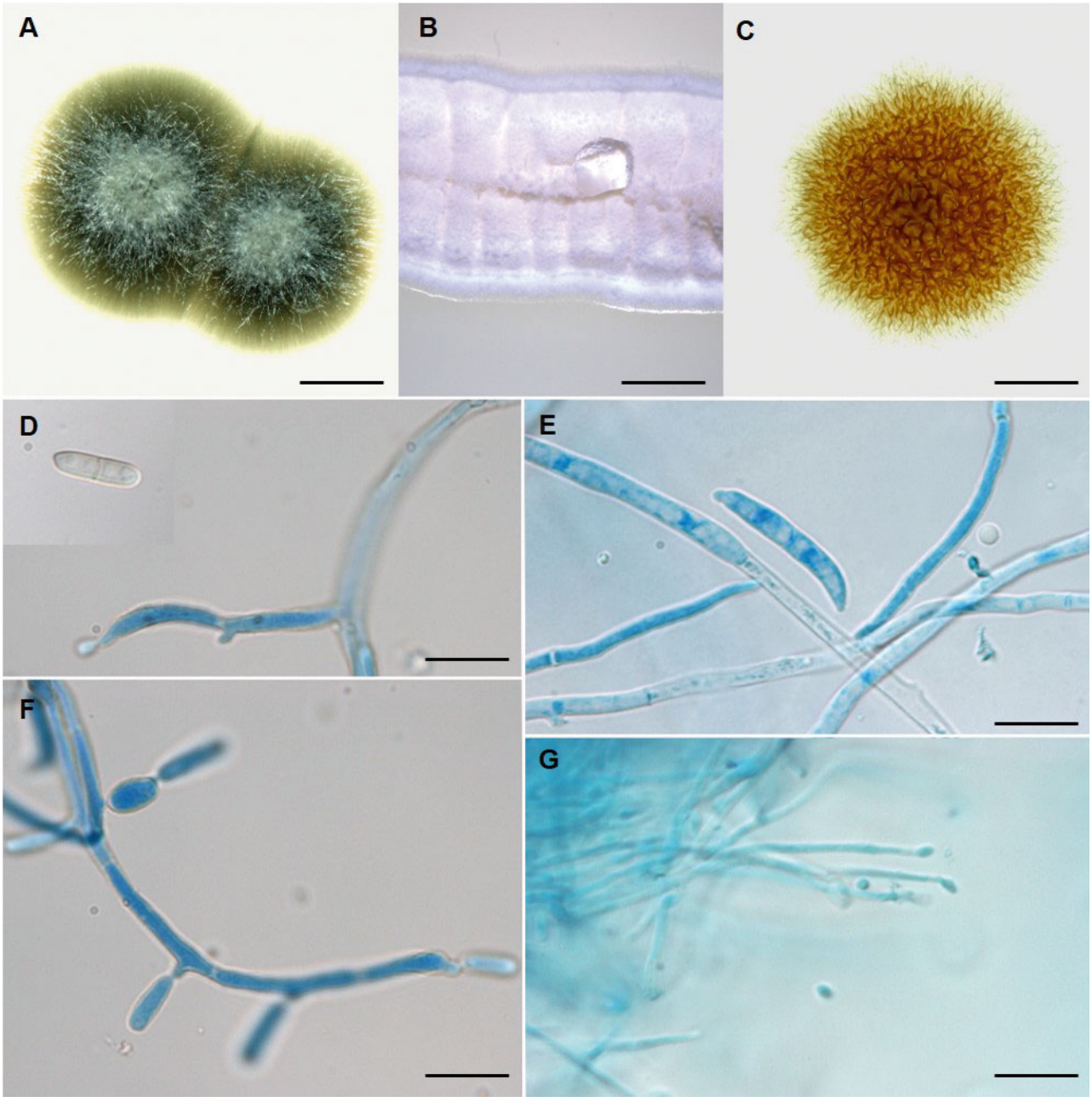

Fig. 7. (A–C) Colonies on malt extract agar and (D–G) corresponding micromorphological structures of (A,D,F) *Exophiala salmonis*; (B,G) *Acremonium alternatum*; (C,E) and *Fusicolla aquaeductuum*. Anniline Blue in lactic acid staining (D–G). Scale bars = (A–C) 5 mm, (D–G) 10 µm

DISCUSSION

Fungal infection is one of the most serious emergent diseases among both captive and wild-caught amphibians (Latney & Klaphake 2013). This is the first case report of a fungal infection in a cave salamander, and includes the identification of the probable source. After successful treatment of an initial protozoan infection, 1 of our captive *Proteus* individuals (Paa 196) developed renewed signs of infections including excessive mucus secretion and sloughing of epidermis, and the appearance of 3 distinct ventral cutaneous ulcers. The ulcerated skin revealed damaged epidermis, dermis, and deep underlying subcutaneous and muscular tissue. We observed dense growth of dark pigmented, septated fungal hyphae

Table 2. Bacterial isolates from a diseased *Proteus anguinus anguinus* (Paa 196) and its aquarium. Abbreviations as in Table 1

Sample/growth conditions	Genus	Species	No. of strains
Swab of the wound			
BA; 30°C	*Acinetobacter*	*A. johnsonii*	4
	Acinetobacter	*A. tjernbergiae*	1
	Pseudomonas	*P. japonica*	3
	Pseudomonas	*P. koreensis*	1
	Pseudomonas	*P. peli*	1
	Pseudomonas	*P. stutzeri*	2
	Shewanella	*S. putrefaciens*	1
SGA pen/strep; 15°C	*Pseudomonas*	*Pseudomonas* sp.	1
TGhL pen/strep; 15°C	*Pseudomonas*	*P. fluorescens*	1
Piece of wound tissue			
BA; 30°C	*Pseudomonas*	*Pseudomonas* sp.	2
	Pseudomonas	*P. fluorescens*	1
Piece of healthy tissue			
BA; 15°C	*Brevundimonas*	*B. mediterranea*	1
Water from aquarium (50 µl)			
BA; 30°C	*Acinetobacter*	*A. guillouiae*	2
	Acinetobacter	*A. tjernbergiae*	1
	Brevundimonas	*B. mediterranea*	1
	Pseudomonas	*P. japonica*	2
	Pseudomonas	*P. salomonii*	1
	Pseudomonas	*P. stutzeri*	1
	Rheinheimera	*R. soli*	2
TGhL pen/strep; 15°C	*Pseudomonas*	*P. fluorescens*	1
	Pseudomonas	*P. putida*	1
Tap water (100 µl)			
BA; 15°C	*Pseudomonas*	*P. stutzeri*	1
BA; 30°C	*Acidovorax*	*Acidovorax* sp.	1
	Caulobacter	*C. vibrioides*	1
	Pseudomonas	*P. stutzeri*	2
	Sphingopyxis	*Sphingopyxis* sp.	1
DRBC; 30°C	*Klebsiella*	*K. oxytoca*	1
SGA pen/strep; 30°C	*Acidovorax*	*Acidovorax* sp.	1
	Sphingobium	*Sphingobium* sp.	1
Fresh water from aquarium (100 µl)			
BA; 30°C	*Pseudomonas*	*P. stutzeri*	1
	Dechloromonas	*Dechloromonas* sp.	2
Fresh water from aquarium (200 ml)			
DRBC; 30°C	*Klebsiella*	*K. oxytoca*	1
	Pseudomonas	*P. putida*	2
SGA pen/strep; 30°C	*Sphingobium*	*Sphingobium* sp.	1
Water from aquarium after 1 wk (100 µl)			
BA; 15°C	*Pseudomonas*	*P. fluorescens*	1
	Flavobacterium	*Flavobacterium* sp.	1
BA; 30°C	*Acinetobacter*	*A. guillouiae*	1
	Limnobacter	*Limnobacter* sp.	1
Swab of rubber hose connected to the tap water supply			
BA; 15°C	*Aeromonas*	*A. veronii*	1
	Massilia	*M. aurea*	1
SGA pen/strep; 30°C	*Sphingomonas*	*Sphingomonas* sp.	1
Swab of plastic container for tap water storage			
BA; 15°C	*Pseudomonas*	*P. fluorescens*	1
	Pseudomonas	*P. stutzeri*	1
	Pseudomonas	*Pseudomonas* sp.	1
DRBC; 30°C	*Pseudomonas*	*P. putida*	1
Swab of dirty aquarium walls			
BA; 15°C	*Acinetobacter*	*A. guillouiae*	1
SGA pen/strep; 30°C	*Sphingobium*	*Sphingobium* sp.	1
Swab of clean aquarium air stone			
BA; 15°C	*Acinetobacter*	*A. johnsonii*	1
BA; 30°C	*Acinetobacter*	*A. johnsonii*	1
	Exiguobacterium	*E. mexicanum*	1
Swab of dirty aquarium air stone			
BA; 15°C	*Pseudomonas*	*P. fluorescens*	1

primarily in the ulcers, but also in the subcutaneous connective and muscle tissue, as well as in the blood vessels below the ulcers. No other microorganisms were observed in the ulcers or their vicinity.

Amphibian skin is particularly sensitive to environmental perturbations and injury due to absence of protective structures and a thin, keratinized layer. It is also involved in a wide array of physiological functions including respiration, osmoregulation, thermoregulation, pigmentation, chemical communication, and pathogen defense (Pessier 2007). This is especially true for the neotenic epidermis of *Proteus*, which is only 6 to 8 cells thick and lacks a protective keratinized layer (Fox & Durand 1990).

Nonspecific clinical signs of the initial and recurring infection in Paa 196 could have been caused by different agents, such as chemical irritants, extreme pH values, or elevated levels of ammonia, which are all recognized as potential hazards to amphibians in captivity (Pessier 2002). However, because the remaining 3 *Proteus* individuals exhibited the same symptoms of the initial infection and yet remained healthy under the same conditions, we focused our research on possible microbial sources of the recurring infection, and newly formed ulcers in individual Paa 196.

Although representatives of the bacterial genera *Acinetobacter*, *Pseudomonas*, and *Shewanella* were isolated from the ulcer of Paa 196, the described ulcer appearance and lack of any bacteria on SEM micrographs of the ulcer did not indicate bacteria as the primary infective agents. However, strains belonging to 3 fungal species were cultured from the Paa 196 ulcers: *Exophiala salmonis, Fusicolla aquaeductuum*,

and *Acremonium alternatum*. The black yeast *E. salmonis* was the dominant fungal species and the only one with a thick-walled, melanized, and septated mycelium.

Black yeasts are causative agents of cutaneous and disseminated systemic phaeohyphomycosis in amphibians (Juopperi et al. 2002, Seyedmousavi et al. 2013). They have been isolated from various species of toads (Dhaliwal & Griffiths 1963, Seyedmousavi et al. 2013) and frogs (Cicmanec et al. 1973, Elkan & Philpot 1973, Rush et al. 1974, Beneke 1978, Miller et al. 1992, Taylor et al. 2001, Seyedmousavi et al. 2013), but not from salamanders. Nevertheless, they can be regarded as relatively common, especially in amphibians held in captivity (Carmichael 1967, reviewed in de Hoog et al. 2011). The genus *Exophiala* (Herpotrichiellaceae, Chaetothyriales, Ascomycota), comprises ca. 40 black yeast species, which can be divided into 2 groups: a thermotolerant group representing potential opportunists or pathogens of immunocompetent humans (Badali et al. 2010, 2012, Najafzadeh et al. 2013, Pattanaprichakul et al. 2013, Woo et al. 2013), and a mesophilic/psychrotolerant group, often involved in infections of fish and amphibians, but occasionally also in invertebrates (de Hoog et al. 2011). According to phylogenetic analyses, most species of waterborne *Exophiala* strongly cluster in the mesophilic *E. salmonis* clade. Only 3 species were reported to cause disease and mortality in amphibians: *E. salmonis, E. pisciphila* in the frog *Mannophryne trinitatis* (Elkan & Philpot 1973), and *E. cancerae* in marine toad *Bufo marinus* (Bube et al. 1992, de Hoog et al. 2011). *Exophiala* infections of fish, particularly in captivity (Kurata et al. 2008, de Hoog et al. 2011), were reported more often in comparison to infections in amphibians. In some fish, e.g. Japanese flounder, the lesions were limited to the skin (Kurata et al. 2008), while in some others, e.g. Atlantic salmon (Otis et al. 1985) and sea dragons (Nyaoke et al. 2009), the lesions were systemic and included internal organs, such as the kidneys, where extensive regions of necrosis were visibly infiltrated by fungal hyphae, as observed in the case of Paa 196. Lesions were identified in other structures as well, including skeletal muscles, skin, swim bladder, heart, liver, spleen, intestine, and even spinal cord (Nyaoke et al. 2009). The species *E. pisciphila* was described as an epizootic agent in captured channel catfish *Ictalurus punctatus* (Fijan 1969, McGinnis & Ajello 1974), with kidneys being the primary place of infection, but the fungus also formed cutaneous, visceral, and brain lesions (Gaskins & Cheung 1986). In addition to fish and amphibian cases, *E. salmonis* was recently also reported in a human, causing phaeohyphomycosis (Yoon et al. 2012). It is present in cold waters (12–14°C), and has a maximum growth temperature of 30–33°C (Göttlich et al. 2002, Defra 2011, de Hoog et al. 2011) in agreement with the water temperature at which Paa 196 was kept in the aquarium. Due to the lack of any objects such as rocks and sand in the aquarium, water was the most probable source of the fungal infection in Paa 196.

Immunological defense mechanisms in non-amniotic vertebrates against *Exophiala* infections commonly include inflammation and granuloma formation (Langdon & McDonald 1987, Nyaoke et al. 2009). We interpret the dispersed inflammatory cells observed in the dermis and other tissues of Paa 196 with observed hyphae as most probably caused by poor physiological condition and weakened immune response of the infected individual.

Infections in amphibians also normally cause increases in the total WBC counts including an increase in the ratio of monocytes involved in phagocytosis of foreign particles and microbes (Davis et al. 2008, Campbell 2015). The percentages of neutrophils and monocytes increase as a result of bacterial and fungal infections, whereas monocytes increase with fungal infections (Green 2001, Seyedmousavi et al. 2014, Campbell 2015). Although the ratios of amphibian blood leukocytes is species specific, in normal conditions neutrophils and lymphocytes usually form the majority (nearly 80% combined) of WBCs (Davis et al. 2008). Gredar (2016) has shown that this also applies to *Proteus* in which 76% of the WBC are lymphocytes, 19% neutrophils, 2.7% eosinophils, and 2.3% are monocytes, while basophils are nearly absent. Despite the absence of intense accumulations of inflammatory cells or granuloma formations around the hyphae in the tissues, the observed increase in neutrophils (24%) and especially monocytes (46%) in the bloodstream of Paa 196 indicates mobilization of the blood cells responsible for coping with fungal infection, similar to the response observed in the salamander *Ambystoma talpoideum* (Davis & Maerz 2010).

The spleen is a major lymphoid organ in the immune response of all vertebrates. In fish and amphibians, it also has hematopoietic and hemocateretic functions, in addition to phagocytosis, storage, and release of erythrocytes (Alvarez 1990). The spleen and liver of ectothermic animals, including amphibians, are also populated with pigmented melanomacrophages with phagocytic activity similar to macrophages (Agius 1980). The spleen and liver of

Proteus are no exception (Jordan 1932, Mrak 2007, Prelovšek et al. 2008). Its spleen is diffuse, with the lymphoid tissue (white pulp) evenly distributed through the red pulp (Mrak 2007). Most of the spleen of *Proteus* is red pulp, consisting of cell cords (lymphocytes, erythrocytes, hemocytoblasts, erythroblasts, and pigment macrophages) and numerous sinusoids full of RBCs. In the case of Paa 196, there was an increased concentration of lymphocytes in the spleen, with only few RBCs, probably reflecting an intense immune response to the fungal infection. The pigment cell clusters in the liver of Paa 196 were numerous but this is actually a typical feature of the liver in *Proteus* (Prelovšek et al. 2008).

Fungi cause a number of diseases among amphibians, including chytridiomycosis, phaeohyphomycosis, zygomycoses, saprolegniasis, and ichthyophoniasis (Pessier 2007). Currently, the most significant and well described pathogens of amphibians are the chytrid fungi *Batrachochytrium dendrobatidis* (*Bd*) and *B. salamandrivorans* (*Bsal*) that cause damage of the outer keratin layer of the skin and disrupt its vital function, resulting in electrolyte depletion and osmotic imbalance. Besides chytrid *Bd* and *Bsal* infections (Fisher et al. 2009, Martel et al. 2014), fungal infections were recorded in the endangered aquatic giant salamander *Cryptobranchus alleganiensis*. Sampling of abnormal/injured sites on the limbs of giant salamander individuals resulted in numerous mixed bacterial/fungal infections (Nickerson et al. 2011). In addition to widely present environmental fungi (e.g. *Acremonium*, *Cladosporium*, *Fusarium*, and *Penicillium*), unidentified *Exophiala*/*Wangiella* species were also found.

No published data are available on microbial infections of *Proteus* in captivity. However, infections with amoebae (L. Bizjak-Mali unpubl. data), *Aeromonas hydrophila* (Kostanjšek et al. 2017), and oomycete water molds from the genus *Saprolegnia* sp. (Kogej 1999) have been observed. This is the first report of a fungal infection in *Proteus*.

Due to paucity of published information on pathogens of *Proteus*, our results may help to increase awareness of the threats to this unique creature and to introduce measures that will ensure that it thrives in captivity as well as in its natural environments and to provide an important baseline for managing this Vulnerable species. In particular, our observations of the response of the immune system of *Proteus* to microbial infections may shed light on the genetic and physiological reasons for the extraordinary longevity of *Proteus*, which can live up to 100 yr in captivity (Voituron et al. 2011).

Acknowledgements. We acknowledge the financial support of the Slovenian Research Agency (ARRS J1-8141) and thank Prof. Børge Diderichsen and Prof. Stanley Session from the Department of Biology, Hartwick College, Oneonta, NY, USA, for careful and critical reading of the manuscript. Special thanks also go to Prof. Tine Valentinčič from the Department of Biology, Biotechnical faculty, University of Ljubljana, for helpful advice on the treatment of diseased animals.

LITERATURE CITED

Agius C (1980) Phylogenetic development of melano-macrophage centers in fish. J Zool 191:11–31

Alvarez R (1990) An ultrastructural-study of the spleen of the ranid frog *Rana perezi*. J Morphol 204:25–32

Badali H, Najafzadeh MJ, van Esbroeck M, van den Enden E, Tarazooie B, Meis JFGM, de Hoog GS (2010) The clinical spectrum of *Exophiala jeanselmei*, with a case report and *in vitro* antifungal susceptibility of the species. Med Mycol 48:318–327

Badali H, Chander J, Bayat M, Seyedmousavi SM and others (2012) Multiple subcutaneous cysts due to *Exophiala spinifera* in an immunocompetent patient. Med Mycol 50:207–213

Beneke ES (1978) Dermatiaceous fungi in laboratory-housed frogs. Pan Am Health Organ Sci Publ 356: 101–108

Bube A, Burkhard E, Weib R (1992) Spontaneous chromomycosis in the marine toad (*Bufo marinus*). J Comp Pathol 106:73–77

Bulog B, Bizjak Mali L, Kos M, Mihajl K, Prelovšek PM, Aljančič G (2000) Biology and functional morphology of *Proteus anguinus* (Amphibia, Caudata). Acta Biol Slov 43:85–102

Campbell TW (2015) Peripheral blood of amphibians. In: Campbell TW (ed) Exotic animal hematology and cytology, 4th edn. John Wiley & Sons, New York, NY, p 89–95

Carey C, Cohen N, Rollins-Smith L (1999) Amphibian declines: an immunological perspective. Dev Comp Immunol 23:459–472

Carmichael JW (1967) Cerebral mycetoma of trout due to a *Phialophora*-like fungus. Sabouraudia 5:120–123

Cicmanec JL, Ringler DH, Beneke ES (1973) Spontaneous occurrence and experimental transmission of the fungus, *Fonsecaea pedrosoi*, in the marine toad, *Bufo marinus*. Lab Anim Sci 23:43–47

Davis AK, Maerz JC (2010) Effects of exogenous corticosterone on circulating leukocytes of a salamander (*Ambystoma talpoideum*) with unusually abundant eosinophils. Int J Zool 2010: 735937

Davis AK, Maney DL, Maerz JC (2008) The use of leukocyte profiles to measure stress in vertebrates: a review for ecologists. Funct Ecol 22:760–772

de Assis VR, Titon SCM, Barsotti AMG, Titon B, Gomes FR (2015) Effects of acute restraint stress, prolonged captivity stress and transdermal corticosterone application on immunocompetence and plasma levels of corticosterone on the cururu toad (*Rhinella icterica*). PLOS ONE 10: e0121005

de Hoog GS, Vicente VA, Najafzadeh MJ, Harrak MJ, Badali H, Seyedmousavi S (2011) Waterborne *Exophiala* species causing disease in cold-blooded animals. Persoonia 27:46–72

Defra (Department for Environment, Food and Rural Affairs) (2011) Review of fungi in drinking water and the implications for human health. BIO Intelligence Service, Paris. http://dwi.defra.gov.uk/research/completed-research/reports/DWI70-2-255.pdf

Densmore CL, Green DE (2007) Diseases of amphibians. ILAR J 48:235–254

Dhaliwal SS, Griffiths DA (1963) Fungal disease in Malayan toads — an acute lethal inflammatory reaction. Nature 197:467–469

Elkan E, Philpot CM (1973) Mycotic infections in frogs due to a *Phialophora*-like fungus. Sabouraudia 11:99–105

Fijan N (1969) Systemic mycosis in channel catfish. Wildl Dis 5:109–110

Fisher MC, Garner TWJ, Walker SF (2009) Global emergence of *Batrachochytrium dendrobatidis* and amphibian chytridiomycosis in space, time, and host. Annu Rev Microbiol 63:291–310

Fox H, Durand J (1990) An examination of the effect of thyroid-hormone on the skin of the neotenic *Proteus anguinus.* Arch Biol (Liege) 101:269–284

Gaskins JE, Cheung PJ (1986) *Exophiala pisciphila* — a study of its development. Mycopathologia 93:173–184

Giberson RT, Elliott DE (2001) Microwave-assisted formalin fixation of fresh tissue: a comparative study. In: Giberson RT, Demaree RSJ (eds) Microwave techniques and protocols. Humana Press, Totowa, NJ, p 191–208

Glass NL, Donaldson GC (1995) Development of primer sets designed for use with the PCR to amplify conserved genes from filamentous Ascomycetes. Appl Environ Microbiol 61:1323–1330

Göttlich E, van der Lubbe W, Lange B, Fiedler S and others (2002) Fungal flora in groundwater-derived public drinking water. Int J Hyg Environ Health 205:269–279

Gredar T (2016) Blood cell cultivation of neotenic amphibians and its optimization for cytogenetic analyses. MSc thesis, University of Ljubljana

Green DE (2001) Pathology of Amphibia. In: Wright K, Whitaker B (eds) Amphibian medicine and captive husbandry. Krieger Publishing, Malabar, FL, p 401–485

Hervant F, Mathieu J, Durand J (2001) Behavioural, physiological and metabolic responses to long-term starvation and refeeding in a blind cave-dwelling (*Proteus anguinus*) and a surface-dwelling (*Euproctus asper*) salamander. J Exp Biol 204:269–281

Jordan HE (1932) The histology of the blood-forming tissues of the urodele, *Proteus anguinus.* Am J Anat 51:215–252

Juopperi T, Karli K, De Voe R, Grindem CB (2002) Granulomatous dermatitis in a spadefoot toad (*Scaphiopus holbrooki*). Vet Clin Pathol 31:137–139

Kiernan JA (1990) Histological and histochemical methods: theory and practice, Vol 1. Pergamon Press, Oxford

Kogej T (1999) Infekcija človeške ribice (*Proteus anguinus*) z glivami rodu *Saprolegnia*. MSc thesis, University of Ljubljana

Kostanjšek R, Gunde-Cimerman N, Bizjak-Mali L (2017) Microbial and parasitic threats to *Proteus.* Nat Slov 19: 31–32

Kurata O, Munchan C, Wada S, Hatai K, Miyoshi Y, Fukuda Y (2008) Novel *Exophiala* infection involving ulcerative skin lesions in Japanese flounder *Paralichthys olivaceus.* Fish Pathol 43:35–44

Lane DJ (1991) 16S/23S rRNA sequencing. In: Stackebrandt E, Goodfellow M (eds) Nucleic acid techniques in bacterial systematics. Wiley & Sons, Chichester, p 115–175

Langdon JS, McDonald WL (1987) Cranial *Exophiala pisciphila* infection in *Salmo salar* in Australia. Bull Eur Assoc Fish Pathol 7:35–36

Langecker TG (2000) The effects of continuous darkness on cave ecology and caverniculous evolution. In: Wilkens H, Culver DC, Humphreys WF (eds) Ecosystems of the world: subterranean ecosystems. Elsevier Science, Amsterdam, p 135–157

Latney LV, Klaphake E (2013) Selected emerging diseases of Amphibia. Vet Clin North Am Exot Anim Pract 16: 283–301

Martel A, Blooi M, Adriaensen C, Van Rooij P and others (2014) Recent introduction of a chytrid fungus endangers Western Palearctic salamanders. Science 346:630–631

McGinnis MR, Ajello L (1974) A new species of *Exophiala* isolated from channel catfish. Mycologia 66:518–520

Miller EA, Montali RJ, Ramsay EC, Rideout BA (1992) Disseminated chromoblastomycosis in a colony of ornate-horned frogs (*Ceratophrys ornata*). J Zoo Wildl Med 23: 433–438

Mrak P (2007) Morphology of the spleen of Proteidaes (Amphibia, Proteidae). MSc thesis, University of Ljubljana

Najafzadeh MJ, Suh MK, Lee MH, Ha GY and others (2013) Subcutaneous phaeohyphomycosis caused by *Exophiala equina*, with susceptibility to eight antifungal drugs. J Med Microbiol 62:797–800

Nickerson CA, Ott CM, Castro SL, Garcia VM and others (2011) Evaluation of microorganisms cultured from injured and repressed tissue regeneration sites in endangered giant aquatic Ozark hellbender salamanders. PLOS ONE 6:e28906

Nyaoke A, Weber ES, Innis C, Stremme D and others (2009) Disseminated phaeohyphomycosis in weedy seadragons (*Phyllopteryx taeniolatus*) and leafy seadragons (*Phycodurus eques*) caused by species of *Exophiala*, including a novel species. J Vet Diagn Invest 21:69–79

O'Donnell K (1993) Fusarium and its near relatives. In: Reynolds DR, Taylor JW (eds) The fungal holomorph: mitotic, meiotic and pleomorphic speciation in fungal systematics. CAB International, Wallingford, p 225–233

Otis EJ, Wolke RE, Blazer VS (1985) Infection of *Exophiala salmonis* in Atlantic salmon (*Salmo salar* L). J Wildl Dis 21:61–64

Pattanaprichakul P, Bunyaratavej S, Leeyaphan C, Sitthinamsuwan P and others (2013) An unusual case of eumycetoma caused by *Exophiala jeanselmei* after a sea urchin injury. Mycoses 56:491–494

Pessier AP (2002) An overview of amphibian skin disease. J Exot Pet Med 11:162–174

Pessier AP (2007) Cytologic diagnosis of disease in amphibians. Vet Clin North Am Exot Anim Pract 10:187–206

Prelovšek PM, Bizjak Mali L, Bulog B (2008) Hepatic pigment cells of Proteidae (Amphibia, Urodela): a comparative histochemical and ultrastructural study. Anim Biol 58:245–256

Presnell JK, Schreibmann MP (1997) Humason's animal tissue techniques, Vol 1. Johns Hopkins University Press, Baltimore, MD

Rehner SA, Buckley E (2005) A *Beauveria* phylogeny inferred from nuclear ITS and EF1-alpha sequences: evidence for cryptic diversification and links to *Cordyceps teleomorphs.* Mycologia 97:84–98

Rush HG, Anver MR, Beneke ES (1974) Systemic chromomycosis in *Rana pipiens.* Lab Anim Sci 24:646–655

Seyedmousavi S, Guillot J, de Hoog GS (2013) Phaeohyphomycoses, emerging opportunistic diseases in animals. Clin Microbiol Rev 26:19–35

Seyedmousavi S, Netea MG, Mouton JW, Melchers WJG, Verweij PE, de Hoog GS (2014) Black yeasts and their filamentous relatives: principles of pathogenesis and host defense. Clin Microbiol Rev 27:527–542

Sket B (1995) Biotic diversity of hypogean habitats in Slovenia and its cultural importance. In: Cimerman A, Gunde-Cimerman N (eds) Proc Biodiversity — International Biodiversity Seminar, Gozd Martuljek. Slovenian National Commission for UNESCO, National Institute of Chemistry, Ljubljana, p 59–74

Sket B (1997) Distribution of *Proteus* (Amphibia: Urodela: Proteidae) and its possible explanation. J Biogeogr 24: 263–280

Sket B (1999) The nature of biodiversity in hypogean waters and how it is endangered. Biodivers Conserv 8: 1319–1338

Sket B (2012) Diversity patterns in the Dinaric Karst. In: White WB, Culver DC (eds) Encyclopaedia of caves. Academic Press, Oxford, p 228–238

Sket B, Paragamian K, Trontelj P (2004) A census of the obligate subterranean fauna in the Balkan Peninsula. In: Griffiths HI, Krystufek B, Reed JM (eds) Balkan biodiversity — Pattern and process in Europe's biodiversity hotspot. Springer, Dordrecht, p 309–322

Stankovič D, Lužnik M, Poboljšaj K (2015) Conservation and declines of amphibians in Slovenia. In: Heatwole H, Wilkinson JW (eds) Amphibian biology, Vol 11. Status of conservation and decline of amphibians: eastern hemisphere. Part 4, Southern Europe and Turkey. Pelagic Publishing, Exeter, p 32–44

Tamura K, Peterson D, Peterson N, Stecher G, Nei M, Kumar S (2011) MEGA5: Molecular Evolutionary Genetics Analysis using maximum likelihood, evolutionary distance, and maximum parsimony methods. Mol Biol Evol 28:2731–2739

Taylor SK, Green DE, Wright KM, Whitaker BR (2001) Bacterial diseases. In: Wright KM, Whitaker BR (eds) Amphibian medicine and captive husbandry. Krieger Publishing Company, Malabar, FL, p 159–179

Turner S, Pryer KM, Miao VPW, Palmer JD (1999) Investigating deep phylogenetic relationships among cyanobacteria and plastids by small subunit rRNA sequence analysis. J Eukaryot Microbiol 46:327–338

van den Ende AHGG, de Hoog GS (1999) Variability and molecular diagnostics of the neurotropic species *Cladophialophora bantiana.* Stud Mycol 43:151–162

Vandel A (1965) Biospeleology, the biology of cavernicolous animals, Vol 1. Pergamon Press, Oxford

Voituron Y, de Fraipont M, Issartel J, Guillaume O, Clobert J (2011) Extreme lifespan of the human fish (*Proteus anguinus*): a challenge for ageing mechanisms. Biol Lett 7:105–107

White TJ, Bruns T, Lee S, Taylor JW (1990) Amplification and direct sequencing of fungal ribosomal RNA genes for phylogenetics. In: Innis MA, Gelfand DH, Sninsky JJ, White TJ (eds) PCR protocols: a guide to methods and applications, Vol 1. Academic Press, San Diego, CA, p 315–322

Woo PC, Ngan AH, Tsang CC, Ling IW and others (2013) Clinical spectrum of *Exophiala* infections and a novel *Exophiala* species, *Exophiala hongkongensis.* J Clin Microbiol 51:260–267

Yoon YA, Park KS, Lee JH, Sung KS, Ki CS, Lee NY (2012) Subcutaneous phaeohyphomycosis caused by *Exophiala salmonis.* Ann Lab Med 32:438–441

Editorial responsibility: Louise Rollins-Smith, Nashville, Tennessee, USA

Submitted: October 18, 2017; Accepted: March 27, 2018
Proofs received from author(s): June 5, 2018