



NOTE

# Underwater ultrasonography and blood sampling provide the first observations of reproductive biology in free-swimming whale sharks

Rui Matsumoto<sup>1,2,\*,#</sup>, Kiyomi Murakumo<sup>1,#</sup>, Ryo Nozu<sup>3</sup>, David Acuña-Marrero<sup>4</sup>, Jonathan R. Green<sup>5</sup>, Simon J. Pierce<sup>6</sup>, Christoph A. Rohner<sup>6</sup>, Harry Reyes<sup>7</sup>, Sofia M. Green<sup>5</sup>, Alistair D. M. Dove<sup>8</sup>, Maria L. Torres<sup>9</sup>, Alex R. Hearn<sup>9,10</sup>

<sup>1</sup>Okinawa Churaumi Aquarium, Okinawa Churashima Foundation, Okinawa 9050206, Japan

<sup>2</sup>Okinawa Churashima Foundation Research Center, Okinawa Churashima Foundation, Okinawa, 9050206, Japan

<sup>3</sup>Faculty of Advanced Science and Technology, Kumamoto University, Kumamoto, 860-8555, Japan

<sup>4</sup>Institute of Natural and Mathematical Sciences, Massey University, Albany Campus, Auckland, 4442, New Zealand

<sup>5</sup>Galapagos Whale Shark Project, Cumbaya, 170901, Ecuador

<sup>6</sup>Marine Megafauna Foundation, West Palm Beach, FL 33411, USA

<sup>7</sup>Dirección Parque Nacional Galápagos, Galápagos, 200350, Ecuador

<sup>8</sup>Research and Conservation Department, Georgia Aquarium, Atlanta, GA 30313, USA

<sup>9</sup>Galapagos Science Center Dept. of Biological Sciences, Universidad San Francisco de Quito, Quito, 170157, Ecuador

<sup>10</sup>MigraMar, Forest Knolls, CA 94933, USA

**ABSTRACT:** We report on a non-invasive technique for observing the reproductive states of wild, free-swimming whale sharks *Rhincodon typus* for the first time. Female whale sharks (n = 22) were assessed using underwater ultrasonography and a novel blood-sampling technique at Darwin Island in the Galapagos Marine Reserve, Ecuador. Despite the widely held assumption among researchers that the post-pelvic distention of large females is indicative of pregnancy, ultrasound provided no evidence of embryos or egg cases. However, the presence of follicles (diameter: 28.5–83.6 mm) was confirmed in 2 female sharks of 11–12 m total length (TL). Additionally, 3 steroid hormones (estradiol, testosterone, and progesterone) were analyzed in blood plasma from 6 female sharks (11–12 m TL). Hormone levels were similar to, or lower than, those obtained from an immature female in the Okinawa Churaumi Aquarium. Based on these results, we infer that female whale sharks (TL >11 m) in this study were mature but not pregnant. The techniques used here for whale sharks can be successfully used to obtain non-lethal field data on the biology and reproductive anatomy of this globally endangered fish, and are adaptable for use in other large marine species.

**KEY WORDS:** Elasmobranch · Conservation physiology · Maturity · Pregnancy · Hormone level · Galapagos · *Rhincodon typus*

## 1. INTRODUCTION

Whale sharks *Rhincodon typus* are well known as the world's largest fish, but their reproduction is still poorly understood. Their huge body size and long-distance migratory behavior make studying the whale

shark's biology difficult. Targeted whale shark fisheries are now banned in most countries, and strandings are uncommon, so scientists rarely have access to specimens (Pierce et al. 2021a). Whale sharks are classified as globally Endangered on the IUCN Red List of Threatened Species (Pierce & Norman 2016),

\*Corresponding author: r-matsumoto@okichura.jp

#These co-first authors contributed equally to this work

© The authors 2023. Open Access under Creative Commons by Attribution Licence. Use, distribution and reproduction are unrestricted. Authors and original publication must be credited.

Publisher: Inter-Research · www.int-res.com

with an IUCN Green Status of Largely Depleted (Pierce et al. 2021b), and they are listed in Appendix I of the Convention on Migratory Species (CMS) and Appendix II of the Convention on International Trade in Endangered Species (CITES). Despite these forms of protection, effective management is hindered by the difficulty of directly monitoring broad-scale population trends and a lack of life history data with which to model demographic parameters (Pierce et al. 2021a).

To date, almost everything known about whale shark reproduction comes from a single pregnant female (10.6 m total length, TL) caught by a commercial fishing boat in Taiwan in 1995 (Joung et al. 1996). Many of the ~300 embryos found in the uteri of this specimen had a yolk sac and were still in their egg cases; others were free-swimming within the uterus. This suggested that whale sharks display yolk-sac viviparity without nutrient supplementation, a lecithotrophic mode, but little more has been discovered since (Pierce et al. 2021a). To advance our knowledge of whale shark reproductive biology, new techniques that will allow us to study sexually mature females in their natural habitat are needed.

Large female whale sharks are rarely seen in coastal areas (Rohner et al. 2021), but they have been documented to transit past offshore islands and seamounts in the eastern Pacific (Ramirez-Macias et al. 2012, Hearn et al. 2016). Noticeable post-pelvic distention in some individuals has led scientists to speculate that they may be pregnant (e.g. Ramirez-Macias et al. 2012, Acuña-Marrero et al. 2014, Hearn et al. 2016). Such sharks would provide an opportunity to learn more about the reproductive biology of the species.

The Okinawa Churaumi Aquarium (OCA) has housed whale sharks since the 1980s. During this time the staff have created health management and biological observation protocols, including growth and maturation indicators for the species (Dove et al. 2021, Pierce et al. 2021a). Concurrently, the development of underwater ultrasonography equipment by OCA has allowed for observations of reproductive state and embryonic growth in 14 elasmobranch species (Murakumo et al. 2020). Additionally, sex hormones extracted from blood samples can be used to observe the reproductive cycles of elasmobranchs (Sulikowski et al. 2016, Nozu et al. 2018). Therefore, we inferred that the combined use of ultrasound and blood analysis represents a promising strategy for studying the reproductive cycle and embryonic development of whale sharks in the wild. Here, we present the results of *in situ* underwater ultrasonog-

raphy and blood sampling from adult, free-swimming female whale sharks—to our knowledge, the first time this has been achieved for an elasmobranch species.

## 2. MATERIALS AND METHODS

### 2.1. Ultrasonography

In-water ultrasounds were conducted at Darwin Arch, off Darwin Island in the Galapagos Marine Reserve (Ecuador), in July 2017 ( $n = 5$ , 5–12 m TL) and September 2018 ( $n = 17$ , 10–14 m TL), and sampling focused on large female whale sharks with visible post-pelvic distention that were suspected to be pregnant (Acuña-Marrero et al. 2014, Hearn et al. 2016); for details, see Table S1 and Fig. S1 in the Supplement at [www.int-res.com/articles/suppl/n050/p125\\_supp.pdf](http://www.int-res.com/articles/suppl/n050/p125_supp.pdf). Whale shark TLs were estimated to the nearest meter using laser photogrammetry, which allows extrapolation of TL from the length between the fifth gill and the start of the first dorsal fin ( $r^2 = 0.93$ ) or visually ( $\pm 10\%$  SE) by experienced observers (Rohner et al. 2011). SCUBA divers approached individual whale sharks swimming at depths ranging from 15–30 m and in currents of up to 2 knots. Ultrasound images were obtained using a portable ultrasound diagnostic imaging system (ARITTA Prologue, Hitachi); for details, see Text S1 in the Supplement. Ultrasound examinations were applied on the post-pelvic distention area, which is considered as a sign of pregnancy, and the abdominal area between the pectoral and pelvic fins, which has been shown to distend during pregnancy in other elasmobranchs (Fig. 1). All ultrasound examinations were typically completed in <1 min, to minimize the potential for stress in animals and due to the difficulty of maintaining contact between the transducer and the shark's skin.

Ultrasound images were recorded underwater by R.M. and examined on the boat by R.M. and K.M. after each dive to inform further sampling. To confirm the scanning position of each image on the abdomen after the examination, the ultrasound procedure was filmed using an HDR-AS300 video camera (Sony) attached to the wrist that the diver (R.M.) used to hold the probe. The probe was applied in the transverse plane and moved parallel to the body axis. To describe and measure target organs, the continuous slice images obtained as DICOM (Digital Imaging and Communications in Medicine)-formatted images were confirmed using OsiriX software (v.8.5.1)

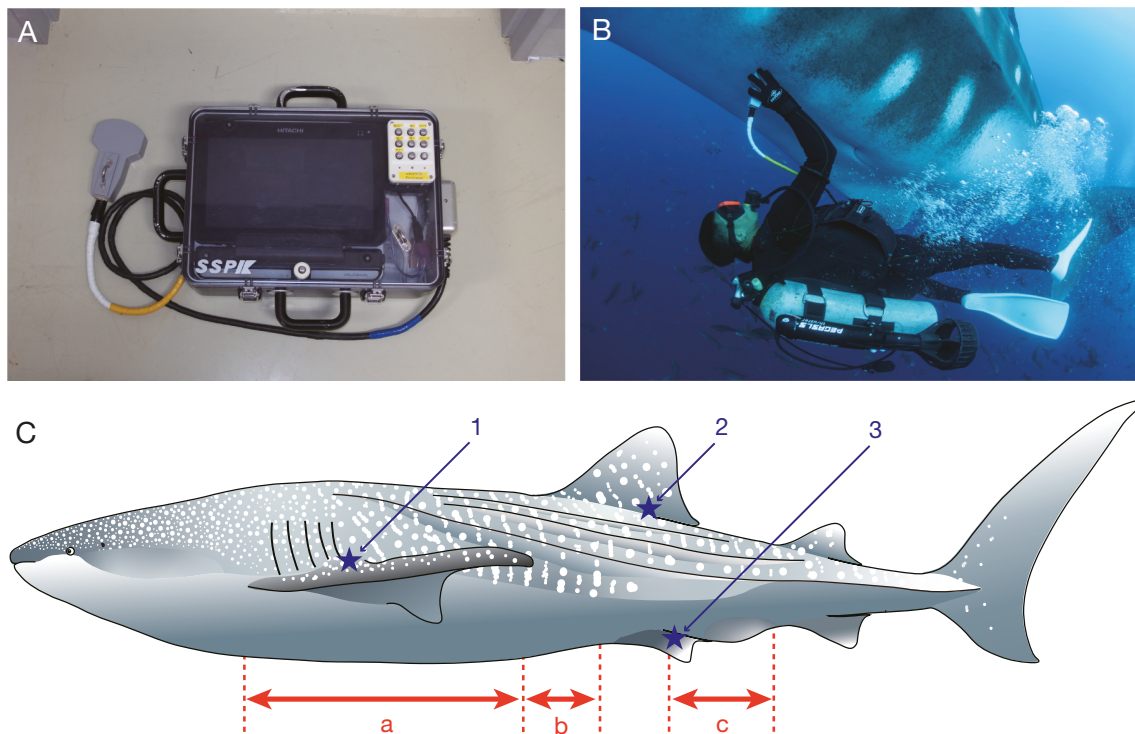


Fig. 1. (A) Ultrasound diagnostic imaging system (ARIETTA Prologue) housed in a pressure- and waterproof case. (B) SCUBA diver positioning the ultrasound probe on the ventral surface of a free-swimming female whale shark in the Galapagos. (C) Ultrasound probe scanning areas (double-headed arrows) and blood sampling locations (stars). a: abdominal area; b: anterior part of pelvic fins; c: post-pelvic distention; 1: pectoral dorsal vein (easy to collect on juveniles); 2: first dorsal cutaneous vein (difficult to collect, but possible on all shark sizes); 3: pelvic dorsal vein (easy to collect on adult sharks)

on the boat, and we then used the highest value obtained as being the most accurate size of the organs. For comparison, we monitored the reproductive organs of a female whale shark (8.0 m TL) throughout 2018 within the OCA using the same equipment and techniques.

To identify anatomical features, such as follicles, on the ultrasound images, we looked through all available images ( $19 \text{ s}^{-1}$ ) and adjusted the contrast to enhance visualization throughout this process. While single images in the figures may look difficult to interpret, features were clear when scanning 3-dimensionally through the images, and follicles were only counted and measured if their spherical shape was confirmed using the many images available.

## 2.2. Blood collection

Blood samples were collected as described in Ueda et al. (2017) by K.M. while swimming alongside each whale shark. We used 2 syringes connected by a 3-way stopcock, an extension tube, and 18 gauge and 90 mm long needles (Fig. S1). The inside wall of

syringes was coated in advance with the anticoagulant lithium heparin. Only the sample from the second syringe (10 ml) was analyzed; the first syringe (5 ml) was used to prevent the contamination of the blood samples by seawater. In free-ranging sharks in the Galapagos, a needle was inserted into either the blood sinus located at the posterior base of the first dorsal fin, or the blood vessels that run along the radial cartilage on the mid-dorsal area of the pelvic fin (Fig. 1C). Blood samples were collected from 1 female in July 2017 (at the dorsal fin base, 11 m TL) and 6 females in September 2018 (at the dorsal side of the pelvic fin, 11–12 m TL; Fig. S2B; Table S1). In the captive female (8 m TL), blood was similarly collected monthly through 2017 (since hormone levels can vary seasonally). After each dive at Darwin Island, plasma was extracted from the samples by centrifugation ( $6000 \times g$  for 6 min) on the boat within an hour of sampling. Plasma samples were then stored in a clean vial at  $-10^\circ\text{C}$  for 4 to 15 d transport to the Universidad San Francisco de Quito (USFQ), where they were stored at  $-80^\circ\text{C}$  until analyses. Plasma was similarly extracted from blood samples of the captive shark and analyzed within the OCA.

### 2.3. Measurement of sex hormone levels

Extraction of plasma steroids, which required ~0.5 ml of plasma was performed as described in Nozu & Nakamura (2015). In brief, plasma steroids were extracted 3 times using 2.5 ml diethyl ether. The extracts were evaporated, and the residue was reconstituted with 3× the original volume of the assay buffer. Estradiol-17b (E2), testosterone (T), and progesterone (P4) levels were determined using an ELISA kit (Cayman Chemical) according to the manufacturer's instructions. Samples and standards were applied in duplicate to each plate.

## 3. RESULTS

### 3.1. Ultrasonography

No embryos or egg cases were detected in any of the 22 female whale sharks. However, follicles were found in the ovaries of 2 large (11–12 m TL) females in September 2018. We identified 18 follicles (diameter range: 28.5–83.6 mm; mean ± SE: 43.7 ± 3.3 mm) in 1 female (Figs. 2A & S3) and a single follicle (75.7 mm) in another female (Table 1). In the other specimens, we were only able to identify skin and muscle layers and the liver, but no follicles (Fig. 2B). Additionally, in the post-pelvic distention, we found only a thick skin layer (ca. 25 cm thickness) and an underlying muscle layer, and no cavity to maintain embryos (Fig. 2C).

There were several artifacts that were visible on the sonographs, including (1) a hyperechoic region at the skin surface, likely caused by skin denticles; (2) an 'M-shaped' area of shadowing immediately below the hyperechoic dermal region; (3) hyperechoic areas at 15–25 cm depth in some of the sonograms; and (4) hyperechoic mirroring in the skin, also likely due to denticles. No follicle images were obtained from the 8.0 m female shark monitored within the OCA; only skin, muscle, intestinal organs, and uteri without ovaries were observed, confirming that this individual was immature across the year-long sampling period (Fig. 2D).

### 3.2. Plasma hormone analysis

Wild whale sharks had hormone concentrations within the range of the samples taken from the captive female for estradiol and progesterone in all samples, and for testosterone in 5 out of 6 samples

(Table 1). However, the female whale shark in the OCA had higher hormone levels in some months than the wild females from Galapagos sampled in July or September (Table 1).

## 4. DISCUSSION

We demonstrated the feasibility of conducting *in situ* ultrasonography and blood sampling of free-swimming adult whale sharks. This method allows for reproductive assessments of free-swimming sharks without the need for restraint, reducing stress in the sampled animal. Ultrasound images from large whale sharks were not as clear as images from smaller whale sharks or from other species due to artifacts related to the exceptionally thick skin layer. This limitation also meant that confident identification of features on the ultrasound images of large whale sharks required experts familiar with ultrasound scanning in smaller whale sharks and other elasmobranchs.

Pronounced enlargement in the area immediately posterior to the cloaca has only been observed in large female whale sharks, not large males, and has been suggested to be a potential indicator of pregnancy (Acuña-Marrero et al. 2014). However, ultrasound examinations (Table S1) identified only skin and muscular tissue in this area, and no similar characteristic has been reported in any other shark species. The presence of this anatomical feature may therefore simply be a secondary sex characteristic in whale sharks and not an indicator of pregnancy. This hypothesis is partially supported by visual observation of a similar distention developing in the immature female (8.0 m TL) held in the OCA, and in females at Georgia Aquarium (R.M., K.M., and A.D.M.D. pers. obs.). Additionally, an autopsy of a deceased juvenile female in the OCA showed that the distention consisted of skin and muscle layers, confirming our ultrasound observations on mature females in the Galapagos.

We obtained ovarian follicle images from 2 of the free-swimming whale sharks (>10 m TL; Table S1). A captive female (8.0 m TL) in the OCA was the largest female whale shark in an aquarium at the time of writing, but ultrasound showed only undeveloped ovarian organs and an unexpanded uterus, indicative of immaturity (Nozu et al. 2015). In mature zebra sharks *Stegostoma tigrinum*, one of the whale shark's closest relatives (Vélez-Zuazo & Agnarsson 2011), the ovary containing follicles usually fills the whole space between the pectoral and pelvic girdles during



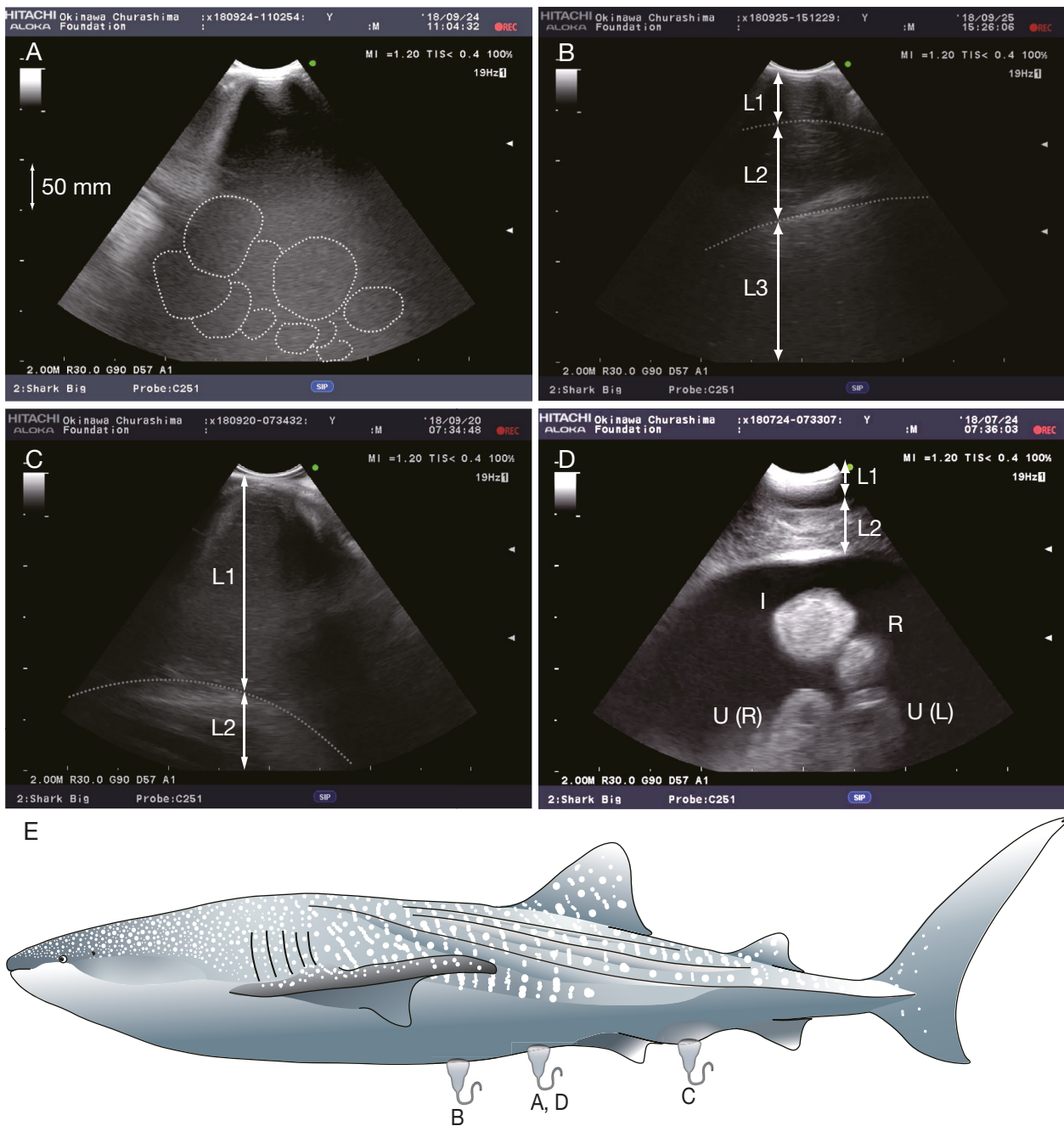


Fig. 2. (A–D) Ultrasound images taken from female whale sharks in the Galapagos. (A–C) Mature females. (A) Longitudinal plane of ovarian follicles enclosed in dotted lines. (B,C) Transverse plane. (D) Transverse plane in an immature female in the Okinawa Churaumi Aquarium (OCA). (E) Parts of the body where each scan was performed. Green marker (pointer) next to the top right of each sonogram consistently points cranially in longitudinal scans or to the left in transverse scans. MI and TIS in the upper right corner of each image indicate the mechanical index and soft-tissue thermal index, respectively. Scale resolution on the lateral column in each image indicates 50 mm of ultrasound penetration depth. ‘W-shaped’ anechoic to hypoechoic shadow (artifact) emanates immediately proximal to the area of hyperechoic enhancement directly beneath the probe in (A) and (B). L1: skin layer; L2: muscle layer; L3: liver; I: intestine; R: rectal gland; U(R): right uterus; U(L): left uterus

the reproductive season (Fig. S4). Assuming a similar relative volume of follicles in whale sharks, the lack of follicles in most of the scanned whale sharks in this study suggests they were not in their reproductive

season. Alternatively, the attenuation and the limitation of the available detecting depth (up to 400 mm) of the ultrasound system may have been too restrictive to identify further follicles. In contrast, egg cases

Table 1. Plasma concentration of 3 steroid hormone levels measured in 7 mature wild whale sharks, and monthly values in single immature captive female whale shark in the Okinawa Churaumi Aquarium (OCA) and presence of follicles in those individuals. Hormone assay range — Estradiol-17 $\beta$  (E2): 0.61–10 000 pg ml<sup>-1</sup>; testosterone (T): 4.9–3000 pg ml<sup>-1</sup>; progesterone (P4): 7.8–10 000 pg ml<sup>-1</sup>. TL: total length; NA: not applicable (no blood sample or follicle ultrasound image could be taken)

Individuals	Sampling date (yr/mo/d)	TL (m)	E2 (pg ml <sup>-1</sup> )	T (pg ml <sup>-1</sup> )	P4 (pg ml <sup>-1</sup> )	No. of follicles (mm)
Female 2	2017/07/08	12	158.6	19.4	19.0	NA
Female 6	2018/09/14	12–14	312.1	<4.9	<7.8	NA
Female 10	2018/09/17	11	173.5	7.6	<7.8	NA
Female 11	2018/09/17	11	480.6	10.2	<7.8	NA
Female 13	2018/09/20	10–11	190.9	12.3	<7.8	NA
Female 14	2018/09/20	12	NA	NA	NA	1 follicle (75.7)
Female 16	2018/09/24	11	505.4	19.0	15.1	18 follicles (28.5–83.6)
Female in OCA <sup>a</sup>	2017/01/09	8	1065.6	33.2	26.7	No follicle
	2017/02/05	8	743.5	26.9	30.0	No follicle
	2017/03/05	8	470.5	20.9	26.9	No follicle
	2017/04/12	8	264.2	7.3	<7.8	No follicle
	2017/05/25	8	285.8	13.8	13.6	No follicle
	2017/06/14	8	489.7	25.6	31.0	No follicle
	2017/07/06	8	650.4	20.4	14.8	No follicle
	2017/08/03	8	746.7	35.7	24.0	No follicle
	2017/09/13	8	750.0	41.3	32.5	No follicle
	2017/10/18	8	673.0	30.8	26.2	No follicle
	2017/11/11	8	133.3	20.0	37.6	No follicle
	2017/12/03	8	133.3	20.6	20.3	No follicle

<sup>a</sup>Single female whale shark kept in OCA

(a sign of pregnancy) are larger than follicles and easily seen on sonogram images in other species. For example, zebra sharks have 1–8 eggs in the uterus prior to laying (Fig. S5). The chitinous cases of eggs reflect ultrasound waves, thus facilitating their detection by sonography (R.M. and K.M. pers. obs.). A pregnant whale shark could contain ~300 of these highly reflective egg cases containing embryos within her uterus (Joung et al. 1996). Therefore, in pregnant individuals, these intra-uterine egg cases are probably filling most of the abdominal cavity and would likely be detectable with an ultrasound system.

Blood sampling and subsequent sex steroid hormone analysis have the potential to provide complementary insights into the reproductive state of whale sharks. Here, we measured E2, P4 and T hormone levels from 6 presumed mature female whale sharks. The hormone values of the adult sharks from Galapagos were within the annual range of, or lower than, those of the immature shark in the OCA (Table 1). As these are the first data from wild whale sharks, we have no baseline for comparison. Blood samples taken in different months will be needed to investigate the timing of their reproductive cycle and put these first hormone data into context. However, the low hormone levels of the large, wild whale sharks compared to those of the immature, captive shark provisionally support our ultrasound results that the wild individu-

als sampled were not pregnant. Sulikowski et al. (2016) developed criteria for pregnancy in tiger sharks using T, E2, and P4 concentrations based on pregnancy determined via ultrasound. They found that the P4 level was not suitable as a pregnancy indicator, with levels being similar among pregnant, non-pregnant mature, and immature sharks. In contrast, Nozu et al. (2018) reported that steroid hormone levels reflected the reproductive cycle in the zebra shark. In particular, E2 increased before ovarian follicle development and decreased in conjunction with follicle regression. The different reproductive modes of these species (i.e. lecithotrophic zebra shark vs. matrotrophic tiger shark) may influence this inconsistency (e.g. Walker 2020). If lecithotrophic whale sharks follow the lecithotrophic zebra shark 'model', we hypothesize that the Galapagos individuals in this study may have only recently reached maturity or were sampled while they were in the follicle regression period late in their reproductive cycle.

Underwater ultrasonography and blood sampling are non-invasive research methods that have the potential to provide physiological information on endangered marine species. Continuation of these methods in different locations and seasons could be a key means to increase scientific understanding of the reproductive biology of whale sharks, including pregnancy and reproductive processes.

**Acknowledgements.** Our study was funded by a grant to the Galapagos Whale Shark Project from the Galapagos Conservation Trust, funding from the Planeterra Foundation to the Marine Megafauna Foundation (MMF), and PADI Foundation grant #28506. Fieldwork was carried out under permits (PC-24-18 and PC-34-17) issued to the Galapagos Science Center (USFQ) by the Galapagos National Park Directorate. We thank Dr. Matthew Pawly (Massey University, New Zealand), Ms. Jenny Waack (Galapagos Whale Shark Project), Kevin A. Morales (ESPOL), Nicolas Dávalos (USFQ), and the captain and crew of the MV 'Queen Mabel'. We acknowledge Dr. K. Ueda in the Okinawa Churashima Foundation (OCF) for providing the underwater ultrasound diagnostic imaging system. We thank Dr. K. Sato and Dr. I. Kawazu in the OCF for giving us the opportunity to perform this research. This work was supported by the admission fees for the OCF. S.J.P. and C.A.R.'s contribution to this project was supported by Aqua-Firma, Shark Foundation, the Swiss Friends of Galapagos, Temperatio, Waterlust, 2 private trusts, and MMF members. We are grateful to the handling editor at ESR, Dr. Austin Gallagher, and the anonymous reviewers whose constructive comments have improved the manuscript.

## LITERATURE CITED

- Acuña-Marrero D, Jimenez J, Smith F, Doherty P Jr and others (2014) Whale shark (*Rhincodon typus*) seasonal presence, residence time and habitat use at Darwin Island, Galapagos Marine Reserve. PLOS ONE 9:e115946
- Dove AD, Matsumoto R, Schreiber C, Murakumo K and others (2021) Lessons from care of whale sharks in public aquariums. In: Dove ADM, Pierce SJ (eds) Whale sharks: biology, ecology, and conservation. CRC Press, Boca Raton, FL, p 181–198
- Hearn A, Green J, Roman MH, Acuña-Marrero D, Espinoza E, Klimley AP (2016) Adult female whale sharks make long distance movements past Darwin Island (Galapagos, Ecuador) in the Eastern Tropical Pacific. Mar Biol 163:213–224
- Joung SJ, Chen CT, Clark E, Uchida S, Huang WYP (1996) The whale shark, *Rhincodon typus*, is a livebearer: 300 embryos found in one 'megamma' supreme. Environ Biol Fishes 46:219–223
- Murakumo K, Matsumoto R, Tomita T, Matsumoto Y, Ueda K (2020) The power of ultrasonography: observation of nearly the entire gestation and embryonic developmental process of captive reef manta rays (*Mobula alfredi*). Fish Bull 118:1–7
- Nozu R, Nakamura M (2015) Cortisol administration induces sex change from ovary to testis in the protogynous wrasse, *Halichoeres trimaculatus*. Sex Dev 9:118–124
- Nozu R, Murakumo K, Matsumoto R, Nakamura M, Ueda K, Sato K (2015) Gonadal morphology, histology, and endocrinological characteristics of immature female whale sharks, *Rhincodon typus*. Zoolog Sci 32:455–458
- Nozu R, Murakumo K, Yano N, Furuyama R, Matsumoto R, Yanagisawa M, Sato K (2018) Changes in sex steroid hormone levels reflect the reproductive status of captive female zebra sharks (*Stegostoma fasciatum*). Gen Comp Endocrinol 265:174–179
- Pierce SJ, Norman B (2016) *Rhincodon typus*. In: The IUCN Red List of Threatened Species 2016, e.T19488A2365291
- Pierce SJ, Pardo SA, Rohner CA, Matsumoto R and others (2021a) Whale shark reproduction, growth, and demography. In: Dove ADM, Pierce SJ (eds) Whale sharks: biology, ecology, and conservation. CRC Press, Boca Raton, FL, p 13–45
- Pierce SJ, Grace MK, Araujo G (2021b) *Rhincodon typus* (green status assessment). In: The IUCN Red List of Threatened Species 2021, e.T19488A1948820213
- Ramirez-Macias D, Vazquez-Haikin A, Vazquez-Juarez R (2012) Whale shark *Rhincodon typus* populations along the west coast of the Gulf of California and implications for management. Endang Species Res 18:115–128
- Rohner CA, Richardson AJ, Marshall AD, Weeks SJ, Pierce SJ (2011) How large is the world's largest fish? Measuring whale sharks *Rhincodon typus* with laser photogrammetry. J Fish Biol 78:378–385
- Rohner CA, Norman B, Reynolds S, Araujo G, Holmberg J, Pierce SJ (2021) Population ecology of whale sharks. In: Dove ADM, Pierce SJ (eds) Whale sharks: biology, ecology, and conservation. CRC Press, Boca Raton, FL, p 129–152
- Sulikowski JA, Wheeler CR, Gallagher AJ, Prohaska BK, Langan JA, Hammerschlag N (2016) Seasonal and life-stage variation in the reproductive ecology of a marine apex predator, the tiger shark *Galeocerdo cuvier*, at a protected female-dominated site. Aquat Biol 24:175–184
- Ueda K, Yanagisawa M, Murakumo K, Matsumoto Y, Sato K, Uchida S (2017) Physical examination, blood sampling, and sedation of large elasmobranchs. In: Smith M, Warmolts D, Thoney D, Hueter R, Murray M, Ezcurra J (eds) Elasmobranch husbandry manual. II. Recent advances in the care of sharks, rays and their relatives. Ohio Biological Survey, Columbus, OH, p 255–262
- Vélez-Zuazo X, Agnarsson I (2011) Shark tales: a molecular species-level phylogeny of sharks (Selachimorpha, Chondrichthyes). Mol Phylogenet Evol 58:207–217
- Walker TI (2020) Reproduction of Chondrichthyan. In: Yoshida M, Asturiano JF (eds) Reproduction in aquatic animals. Springer, Singapore, p 193–223

Editorial responsibility: Austin Gallagher,  
Herndon, Virginia, USA

Reviewed by: B. Campbell and 1 anonymous referee, and  
previous version reviewed in MEPS by 3 other anonymous  
referees

Submitted: February 19, 2022

Accepted: January 30, 2023

Proofs received from author(s): March 3, 2023